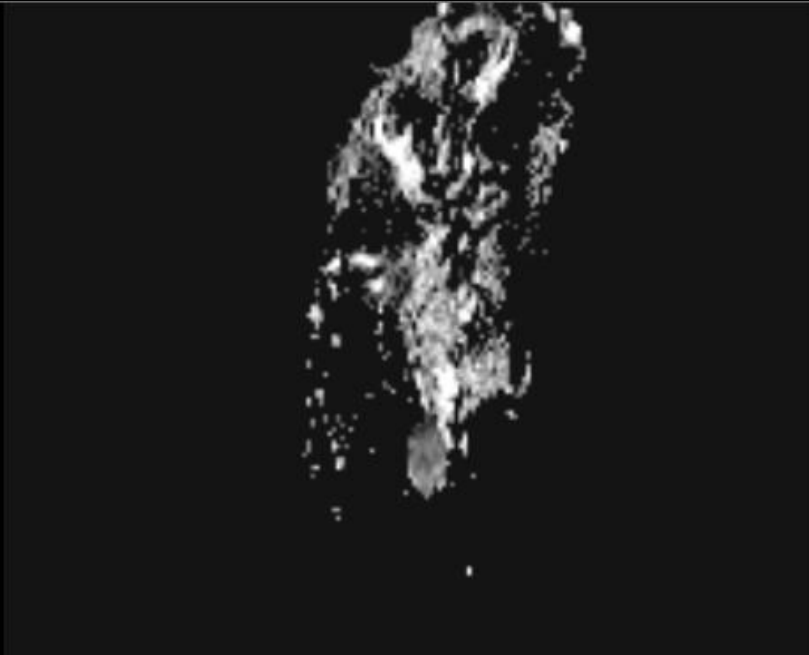
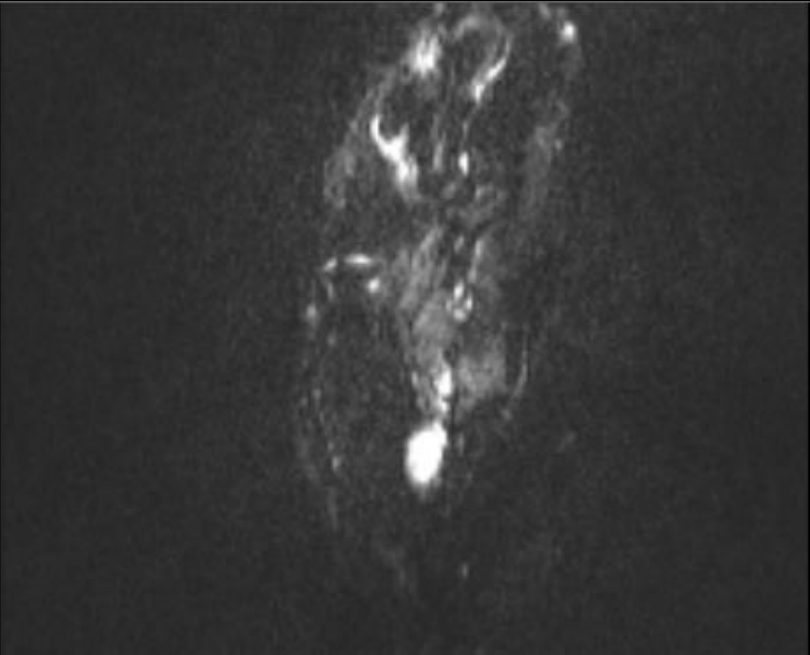
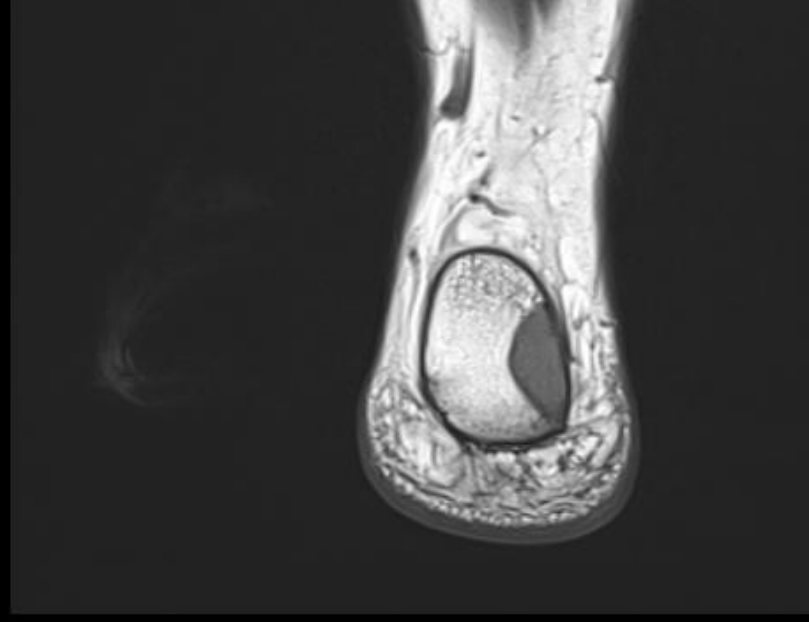
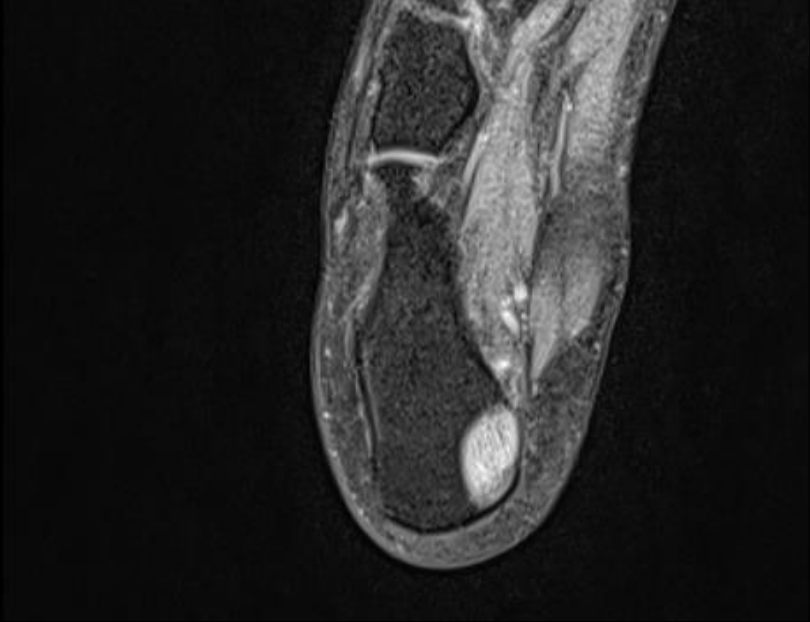
MICOD – 22/04/2024  
Case contributor – Dr. Sonal Saran

# MI-COD

MSS INDIA- Case Of the Day





12 year old boy with heel pain