

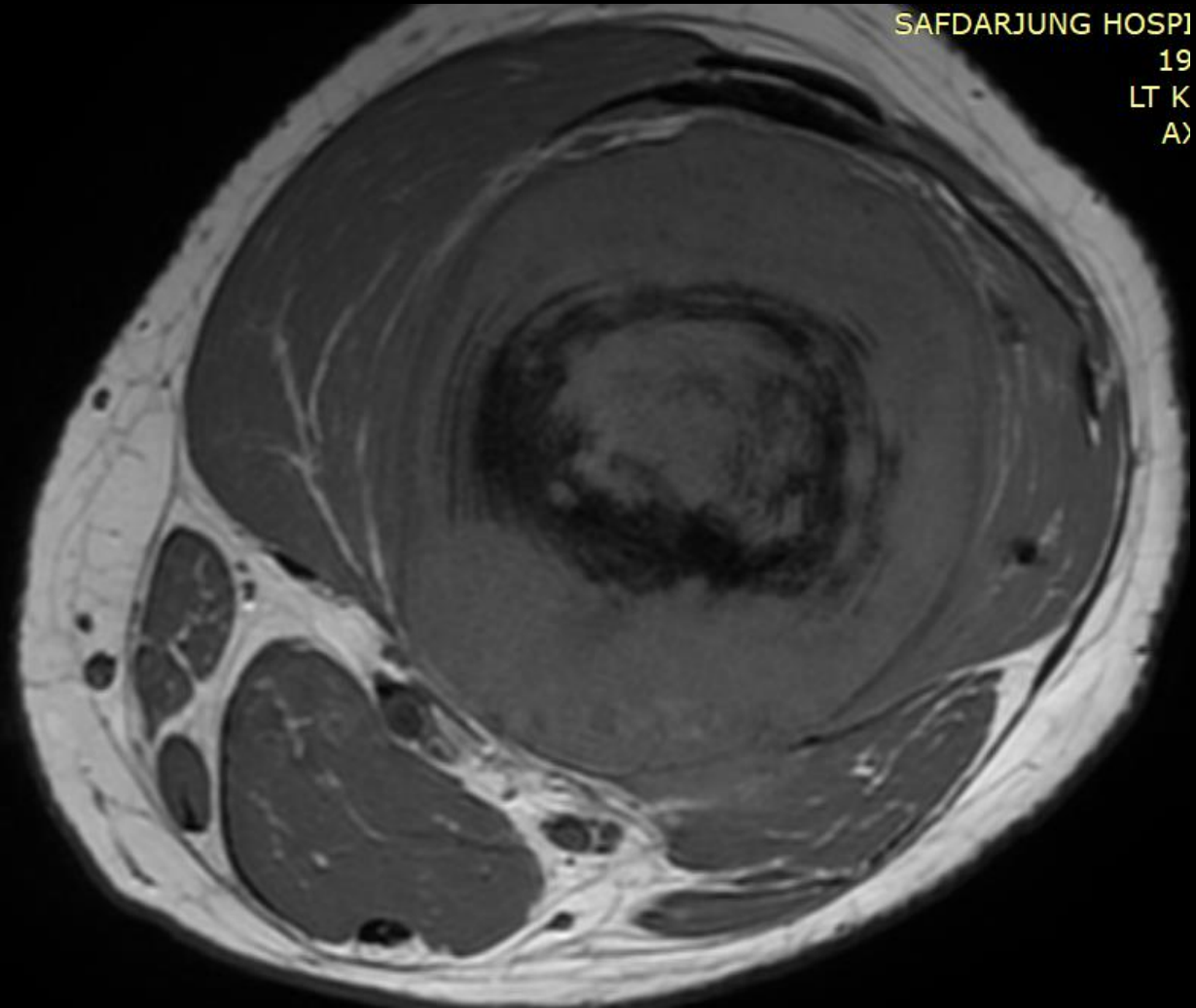
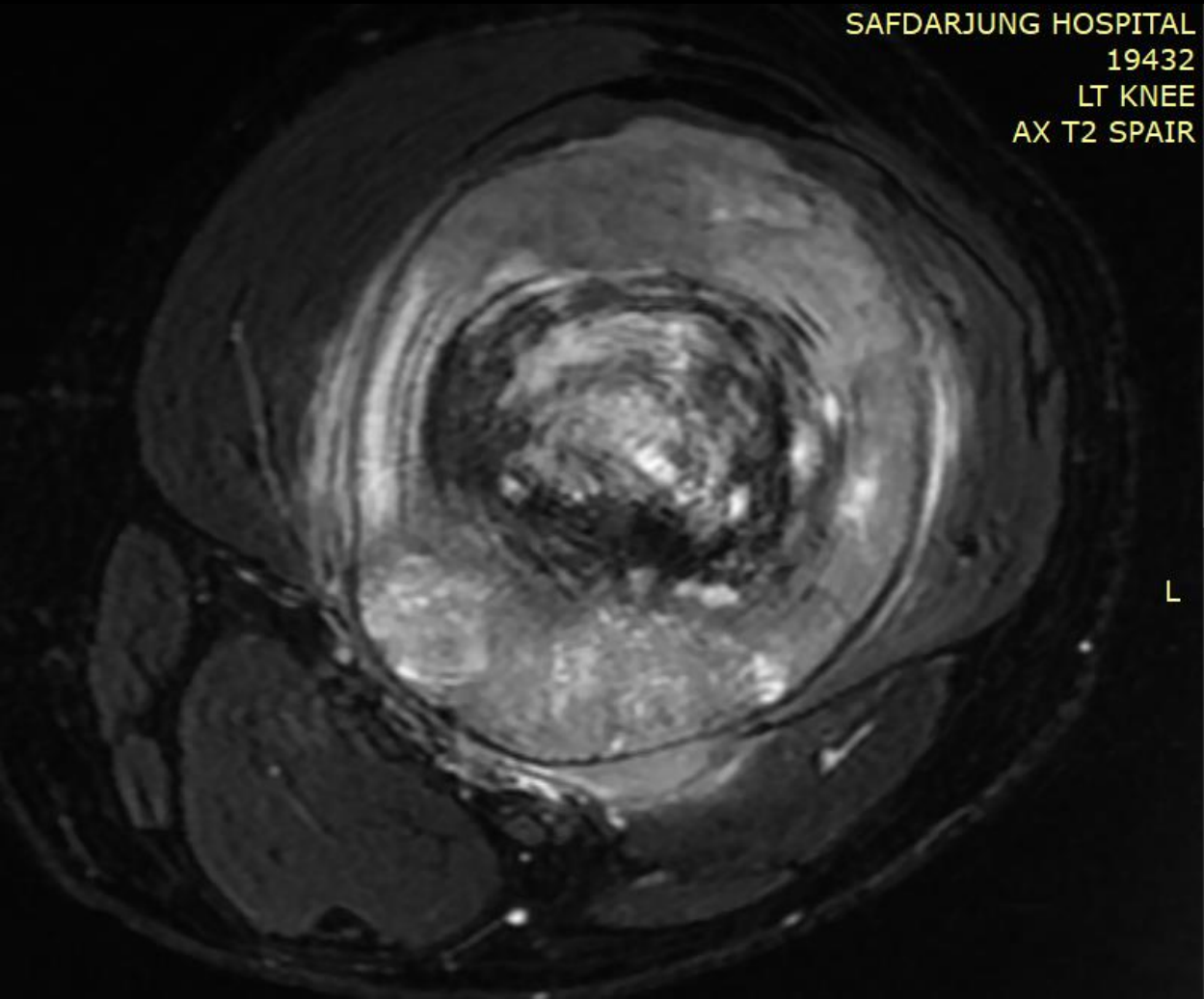
MICOD – 17/04/2024

Case contributor – Dr. Dharmendra Singh

MI-COD

MSS INDIA- Case Of the Day





The surgeon wants to know

- A. The NVB zone is free from the tumor.
- B. The tumor is abutting (< 180 degree) the NVB zone
- C. The peritumoral edema has infiltrated NVB zone
- D. The tumor has encased (>180 degree) the NVB zone

*NVB: Neurovascular bundle