
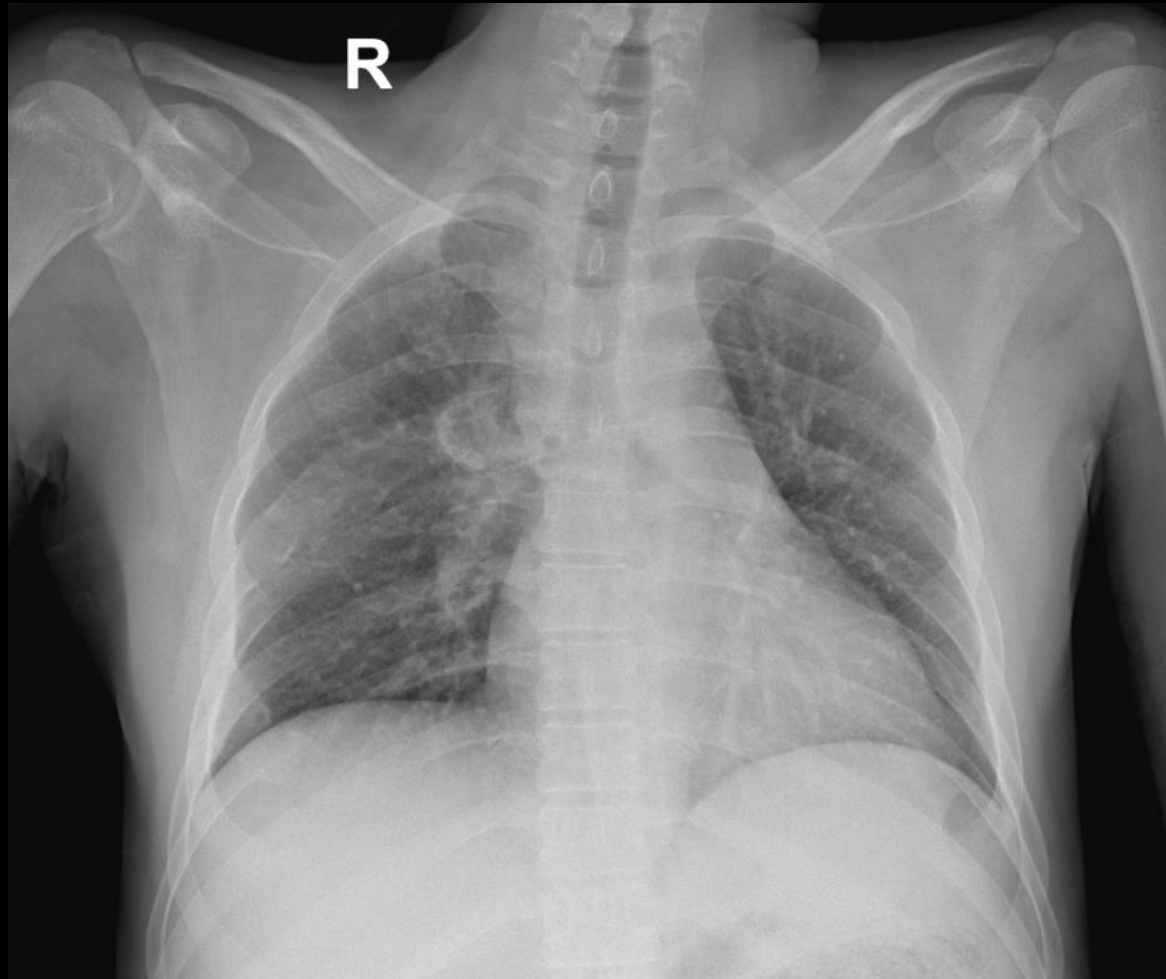


MICOD – 16/04/2024  
Case contributor – Dr. Sonal Saran

# MI-COD

MSS INDIA- Case Of the Day





32 year old male with pain in back