

MICOD – 15/04/2024

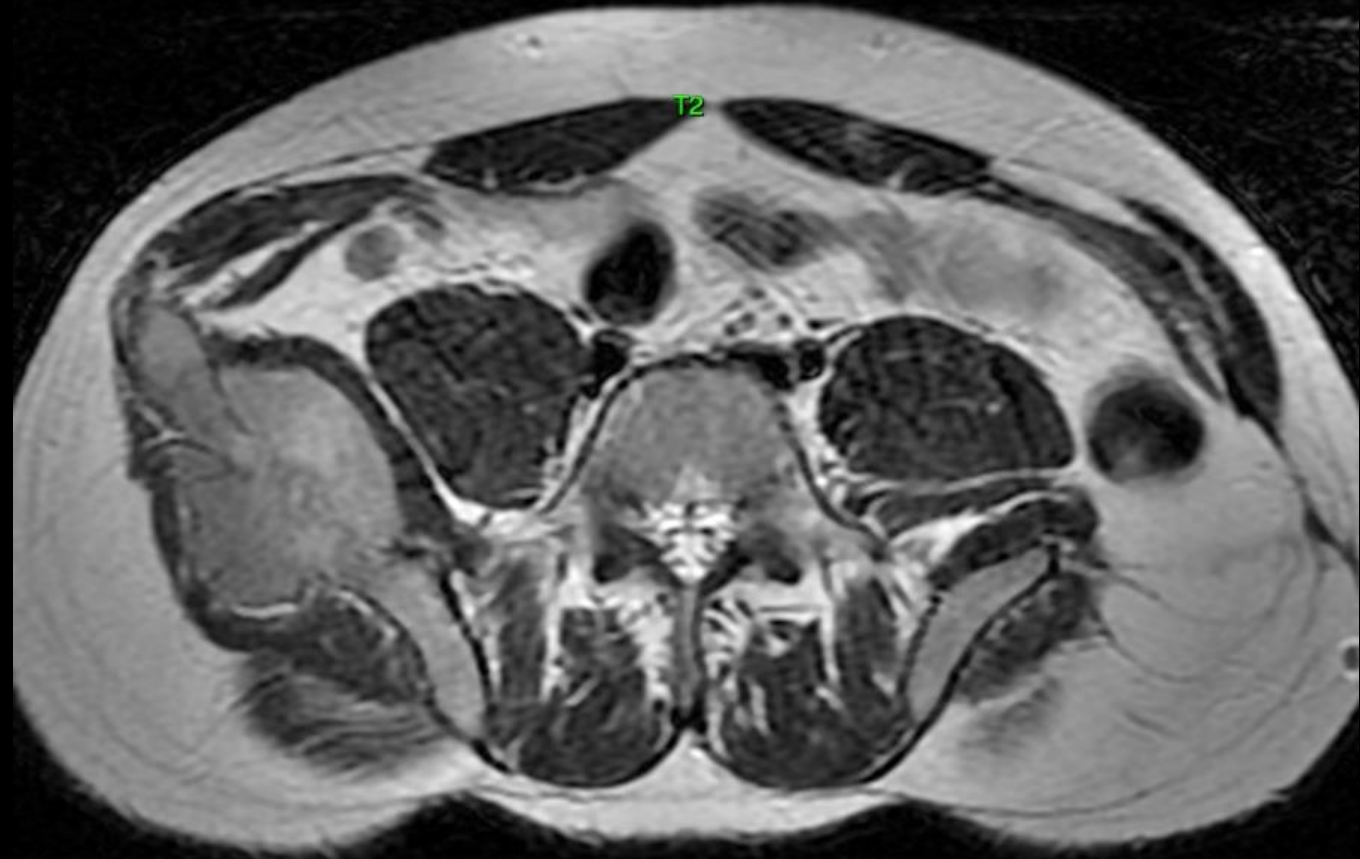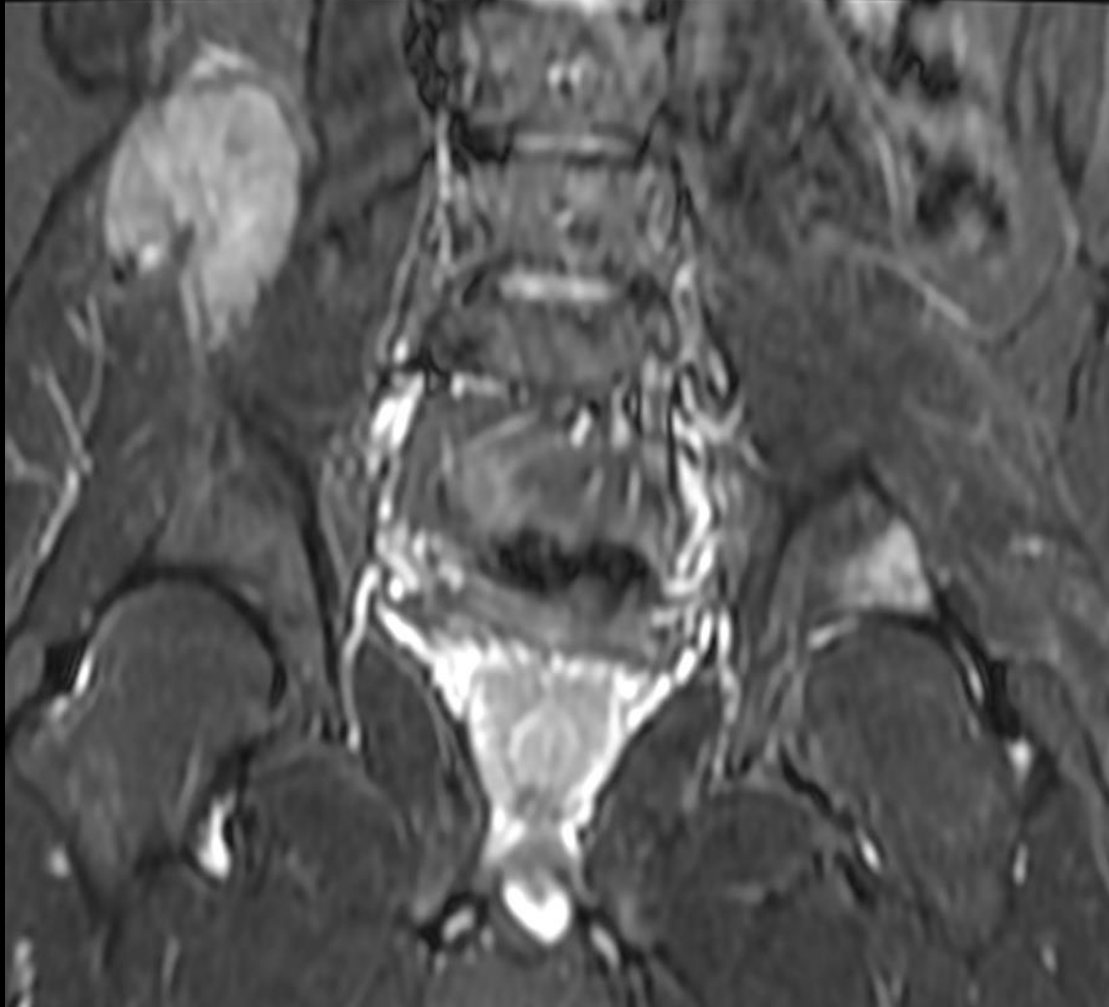
Case contributor – Dr. Chinmay P. Mehta

# MI-COD

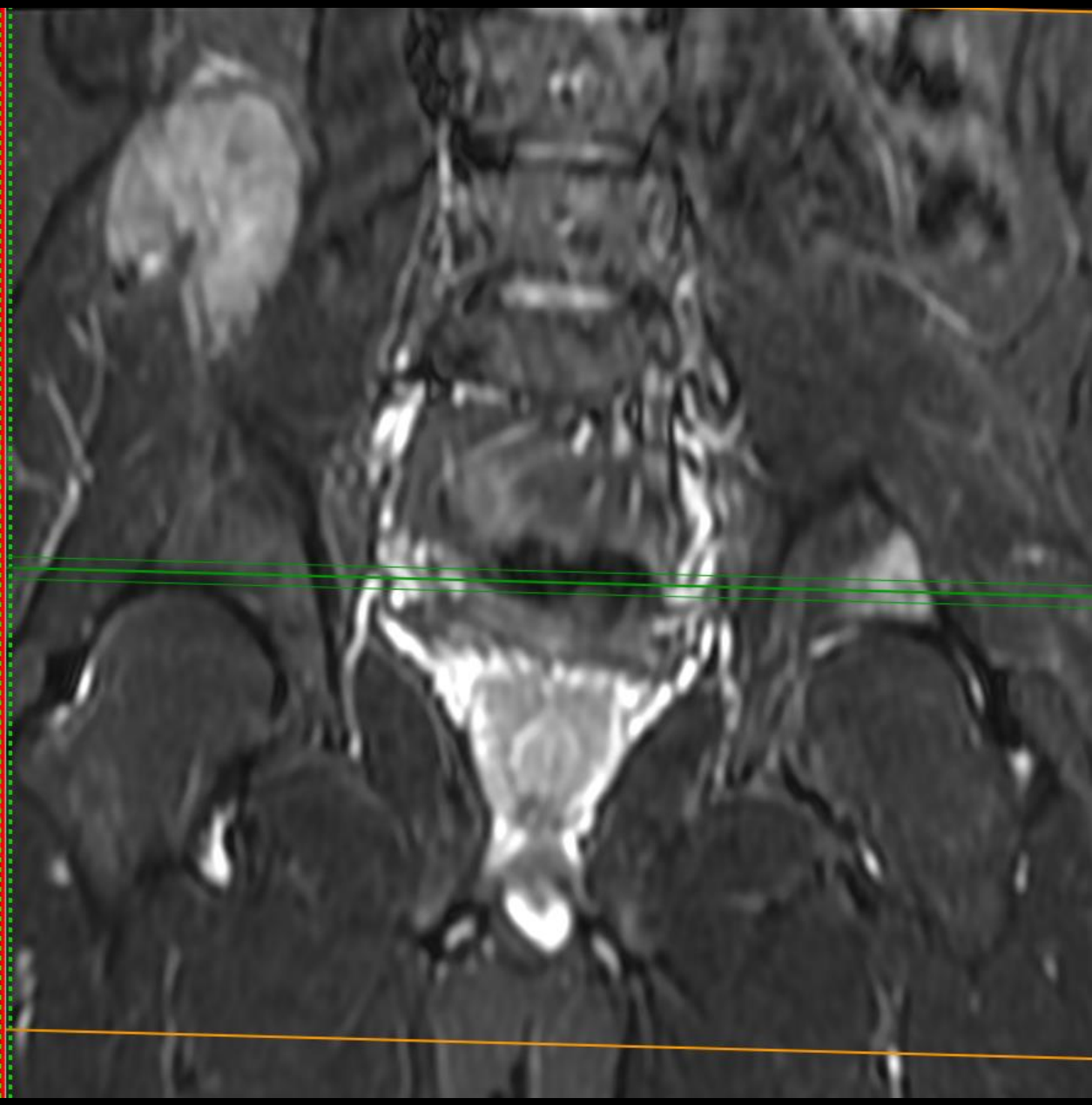
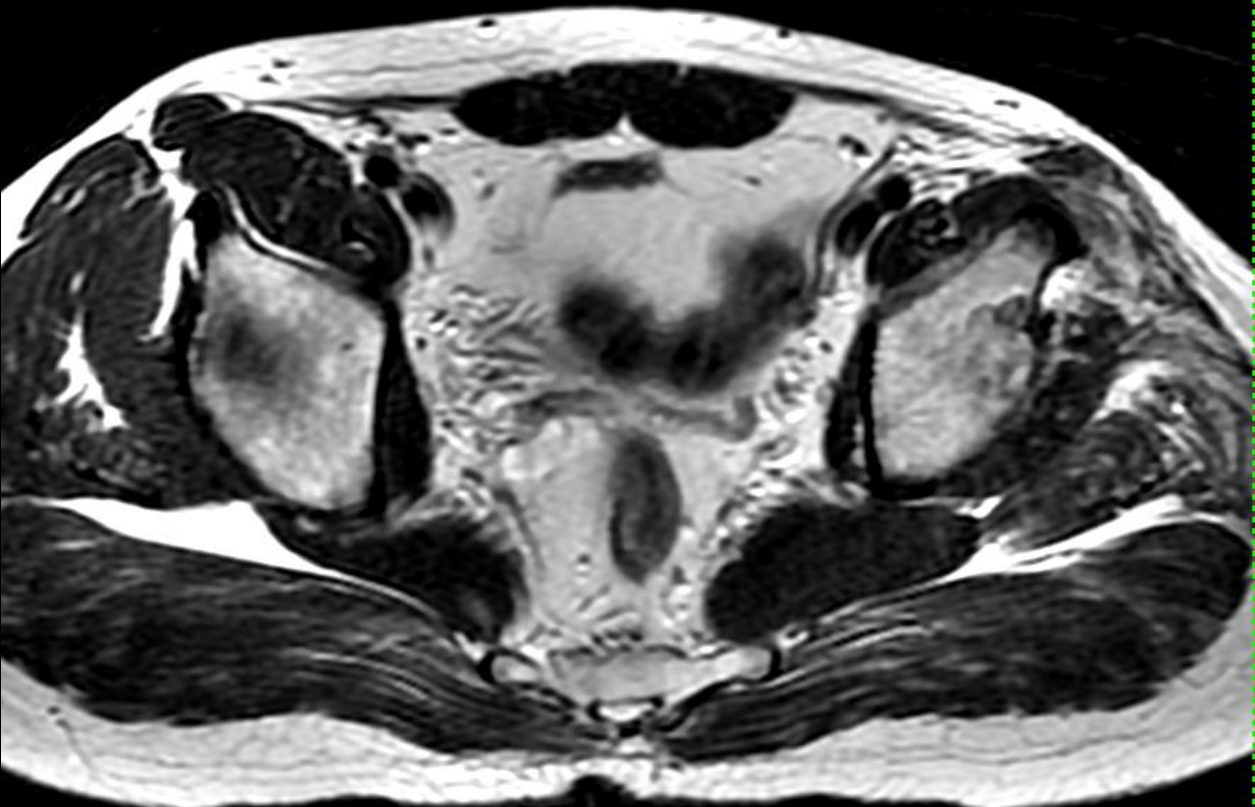
MSS INDIA- Case Of the Day

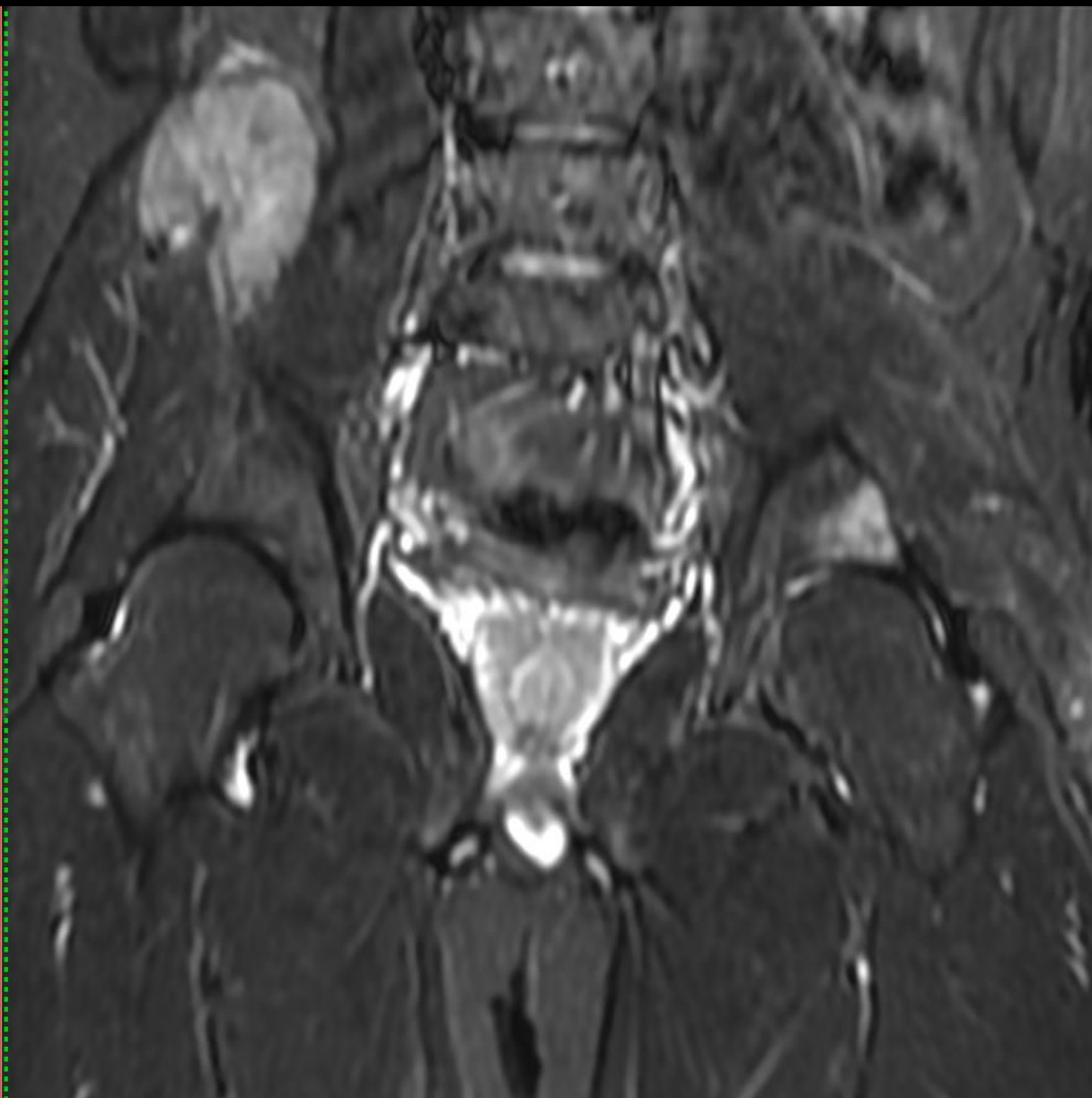
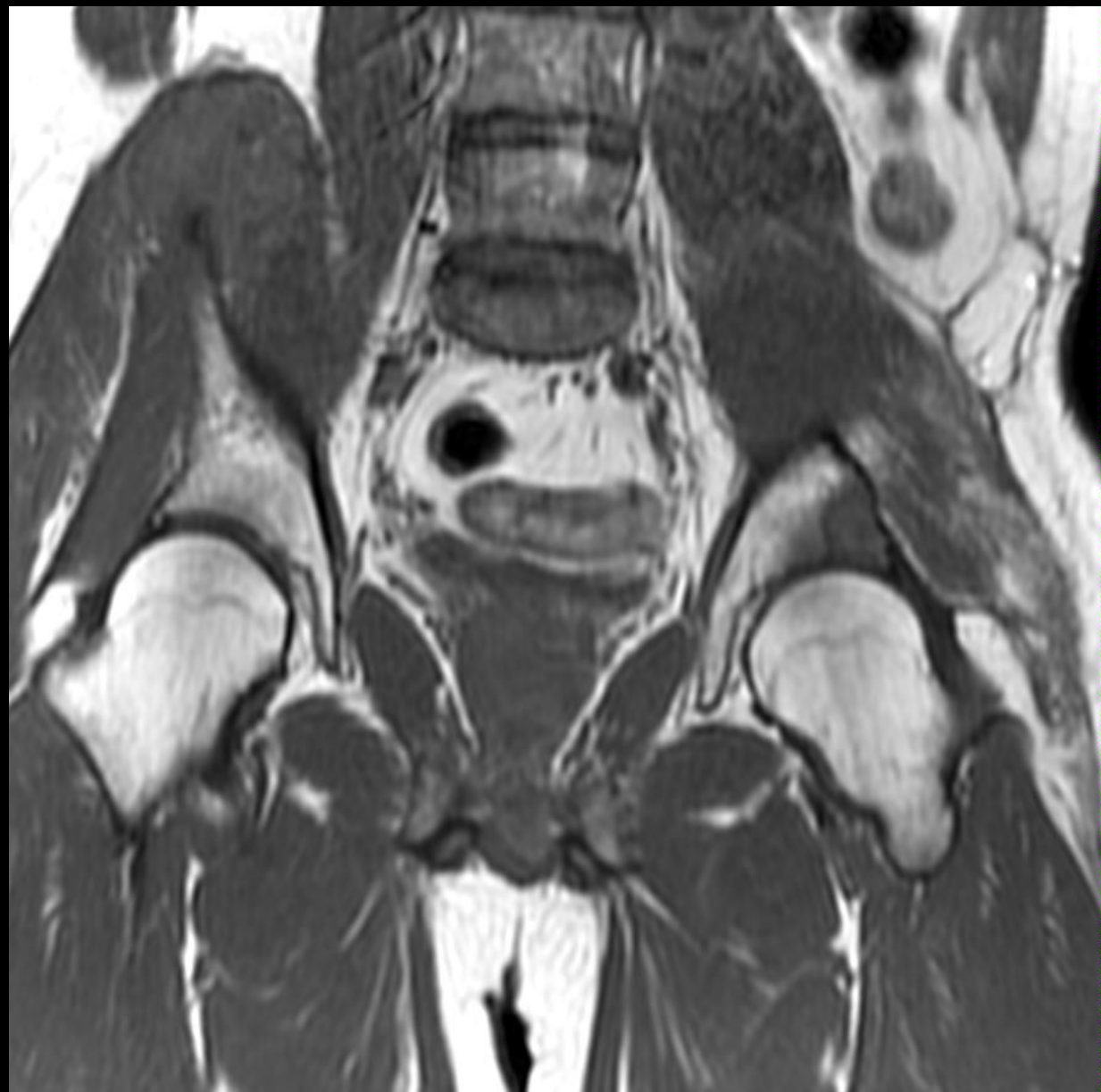

27yr old patient- known case of hereditary multiple exostosis and operated 1 year ago for left iliac blade chondrosarcoma- now presents with right iliac swelling.

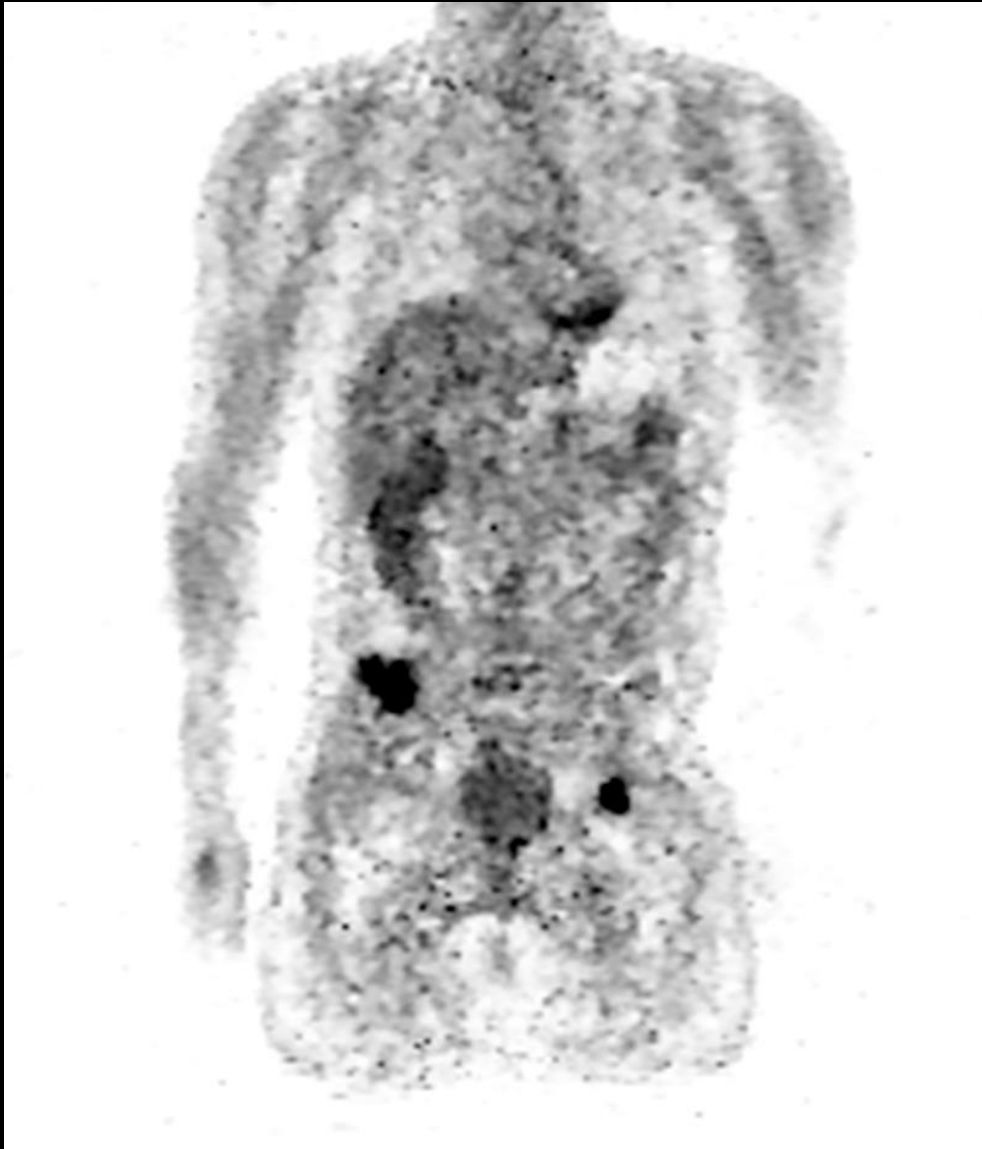







# PET CT WITH SUV VALUES

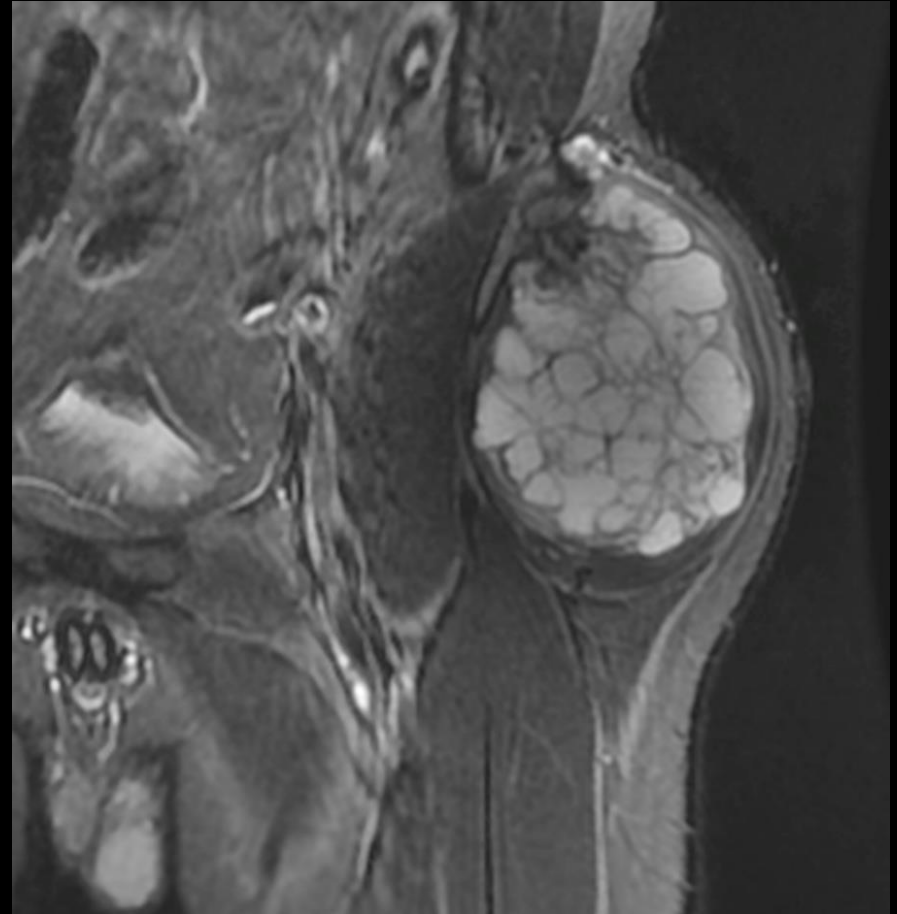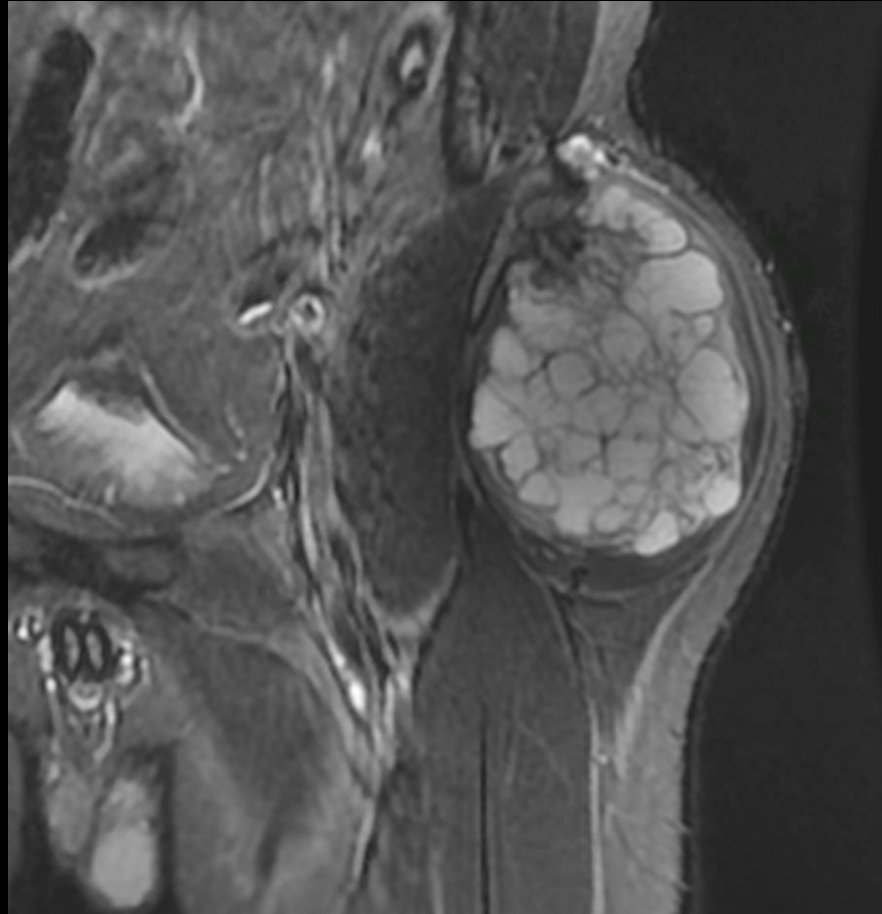


## Page:2

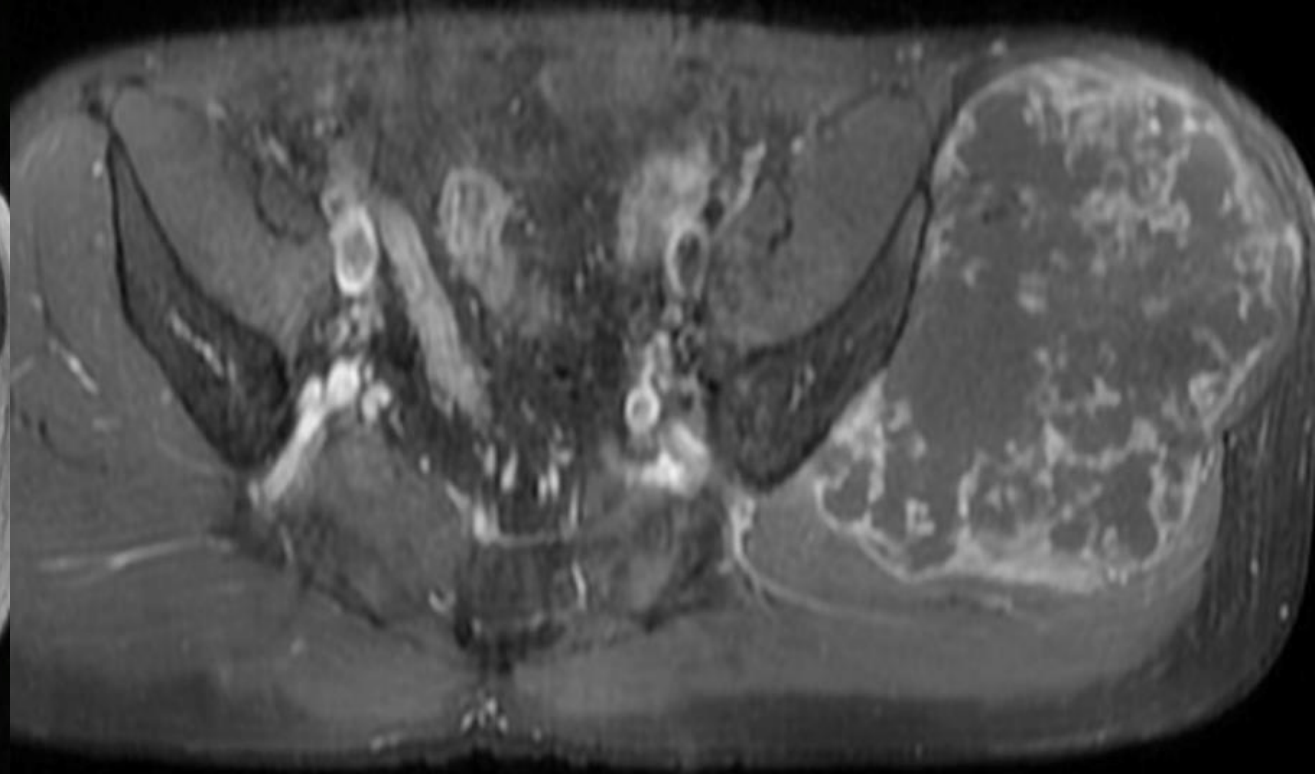
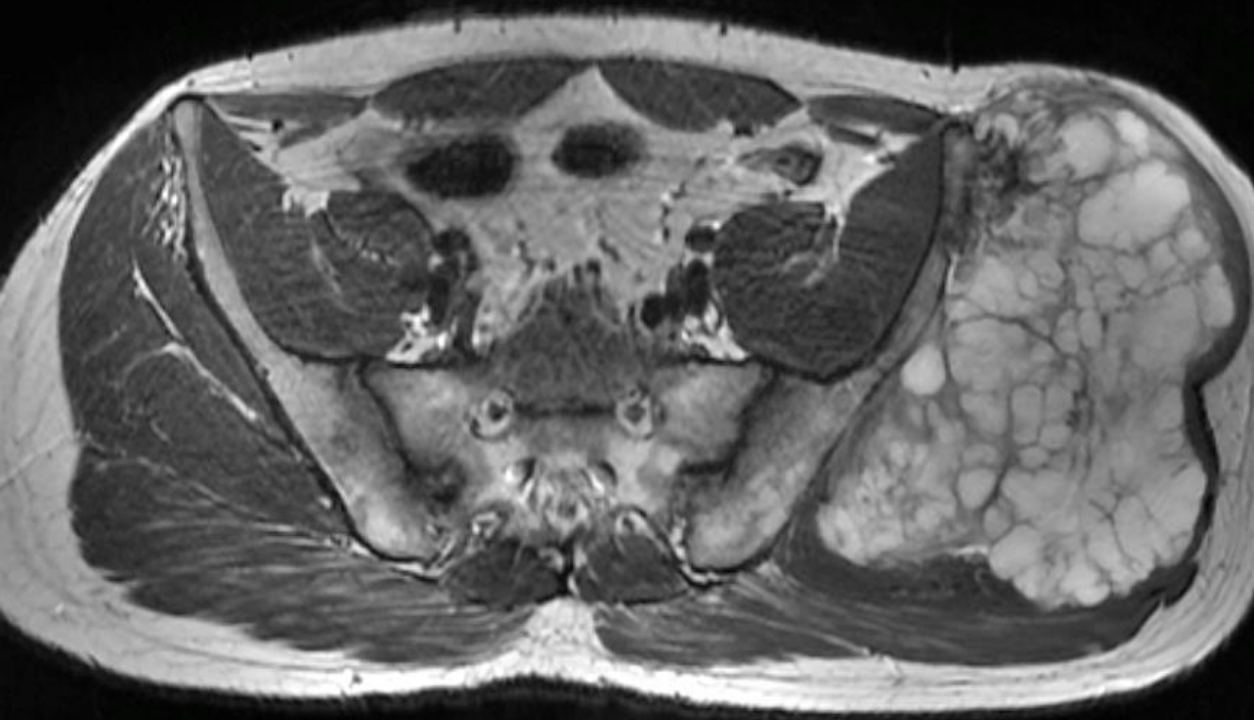An irregular osteolytic lesion is now seen in the left acetabulum showing uptake of FDG (SUVmax: 26.9). An irregular osteolytic lesion is also seen involving the right iliac bone, and associated with a large extra osseous enhancing soft tissue component involving the subjacent iliacus muscle and the overlying gluteal muscles. The lesion measures about 5.5 x 4.8 cm in maximum transverse dimensions with subtle uptake of FDG (SUVmax: 9.9). No other metabolically active skeletal lesion is seen.



# PRE-OPERATIVE IMAGES



# PRE-OPERATIVE IMAGES



# Q1. What next ?

1. Diagnosis of recurrent chondrosarcomas / metastasis and treat accordingly.
2. Biopsy the left acetabular lesion.
3. Biopsy the right iliac blade lesion.
4. Biopsy both the lesions.