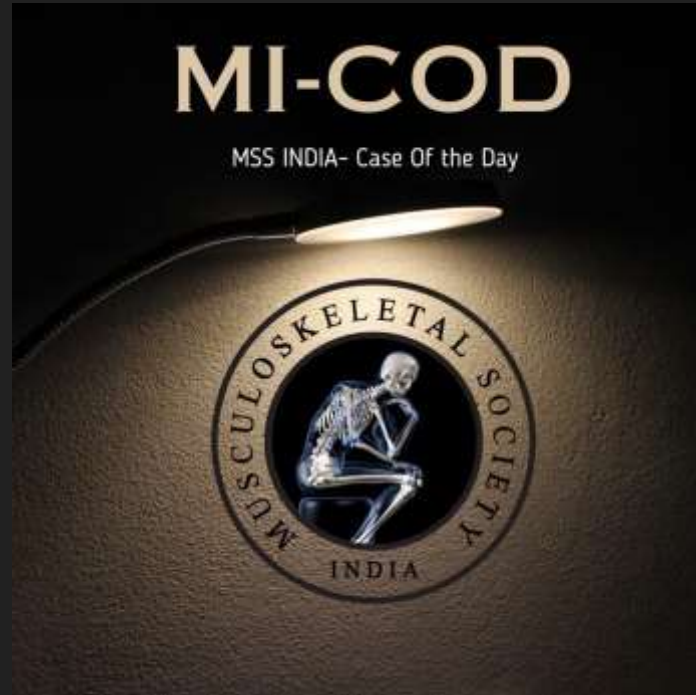
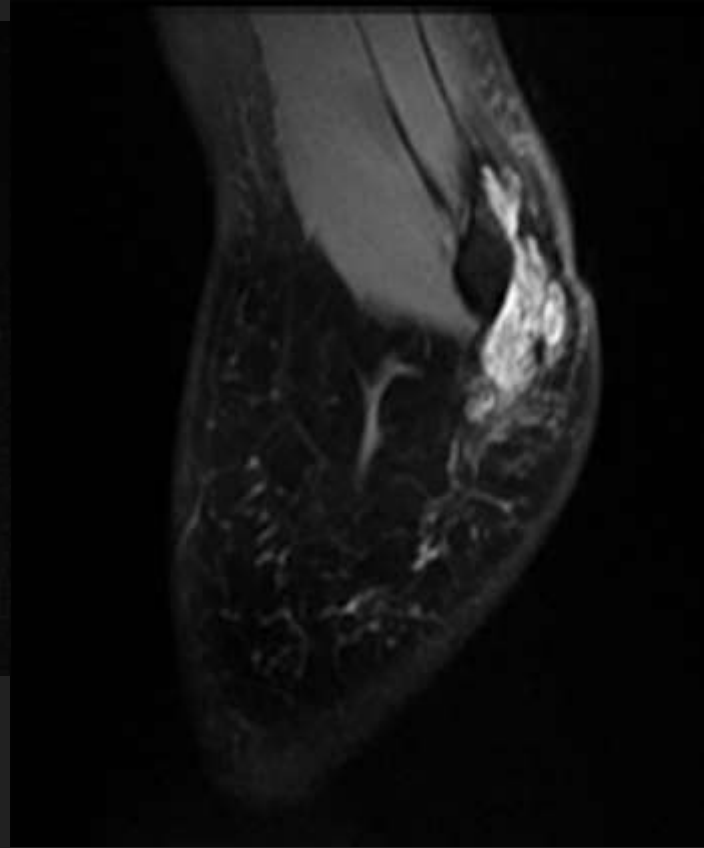
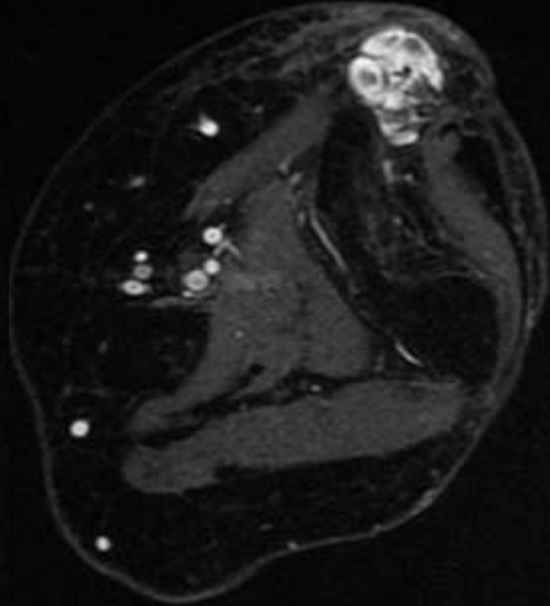
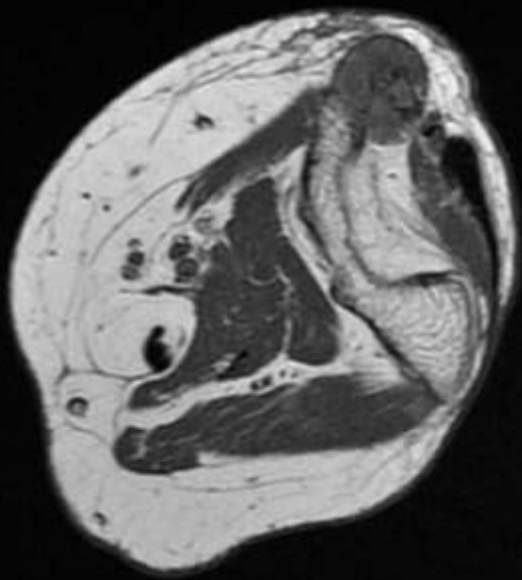


MICOD -10/04/24
Case contributor – Dr. Satish



40 yrs female, Acute onset left elbow pain, palpable lesion along medial aspect of elbow. Patient is On treatment for borderline leprosy. Now, worsening of ulnar nerve palsy



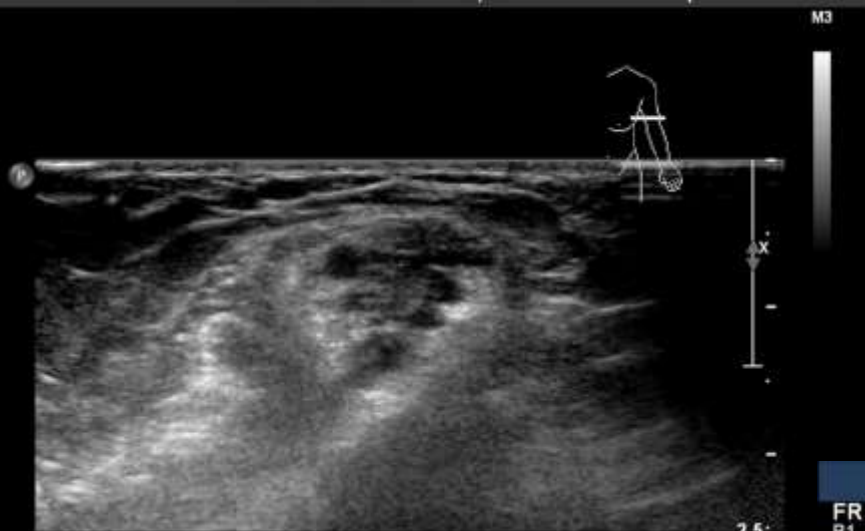MRI of elbow T1, T1fs post contrast

2163756

KASTURBA HOSPITAL, M L12-5/MSK Sup

FR 37Hz
RS

2D
73%
C 55
P Low
Res



2163756

KASTURBA HOSPITAL, M L12-5/MSK Sup

FR 13Hz
R1

2D
80%
C 60
P Med
Res

CF
80%
350Hz
WF 29Hz
Low

