


MICOD – 27/03/2024

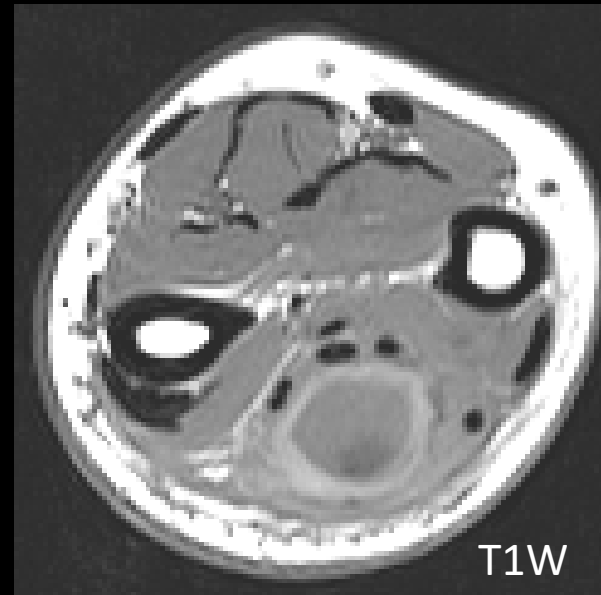
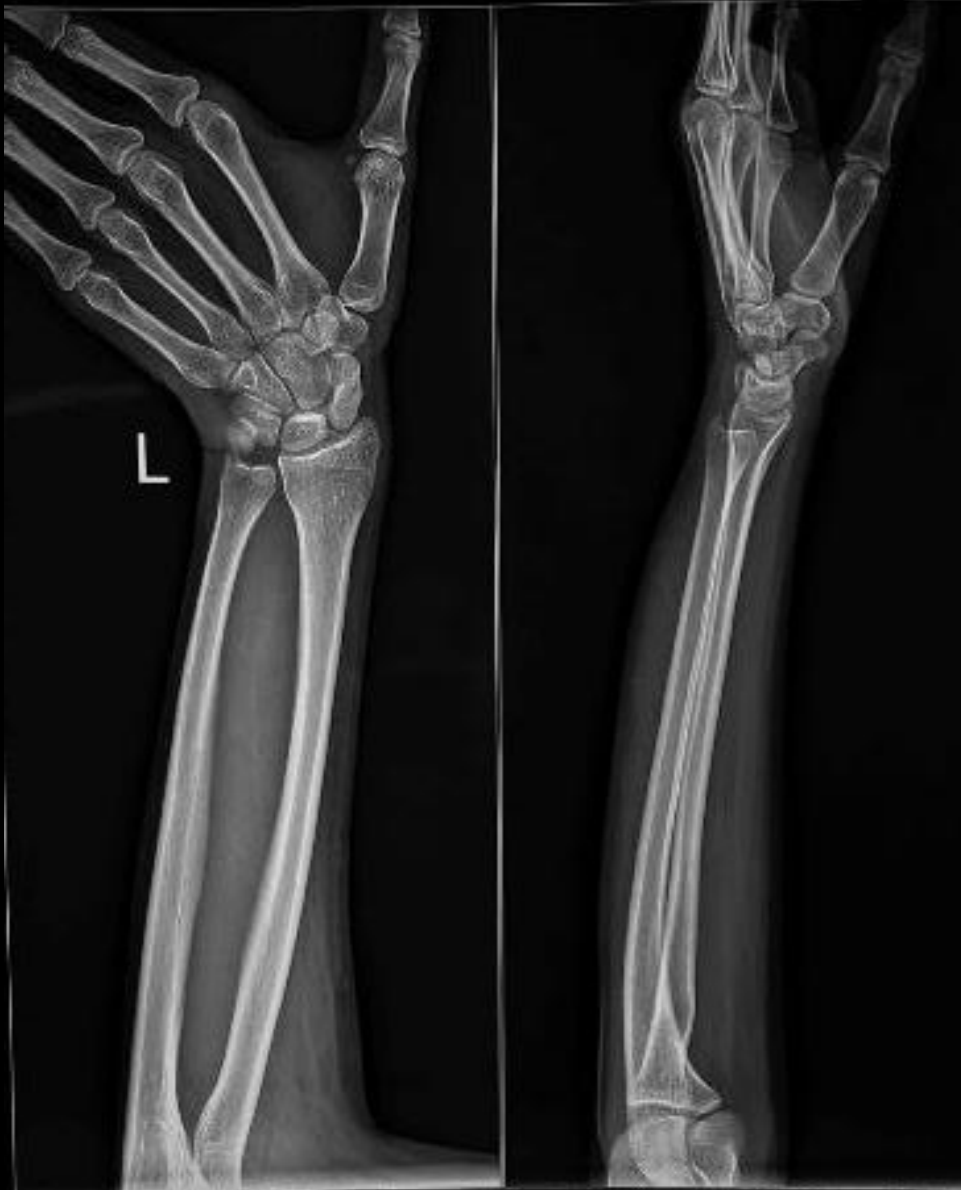Case contributor – Dr. Vaishali Upadhyaya

# MI-COD

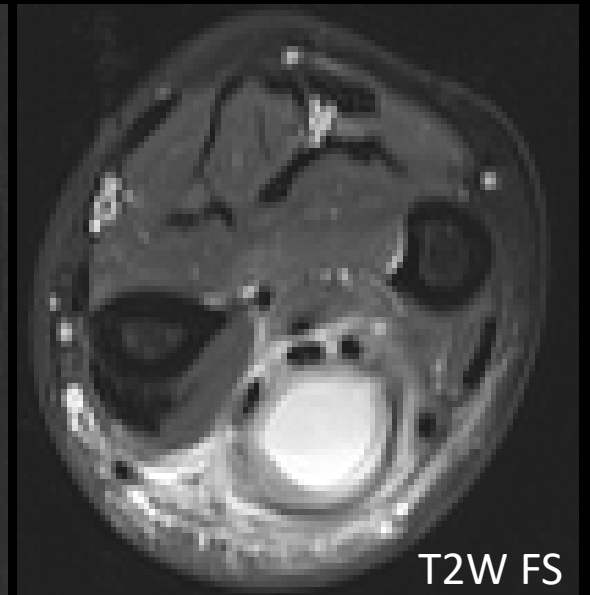
MSS INDIA- Case Of the Day



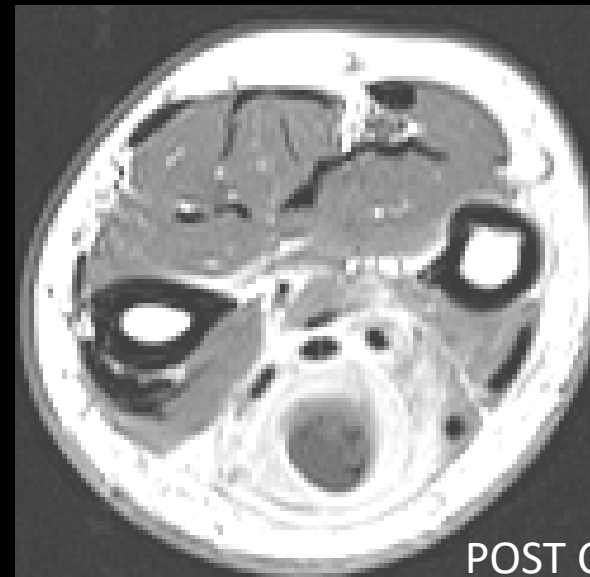
21-year-old lady with swelling on the dorsal aspect of left forearm, sometimes painful, no H/O fever or trauma



T1W



T2W FS



POST CONTRAST T1W

