

MICOD -23/03/24

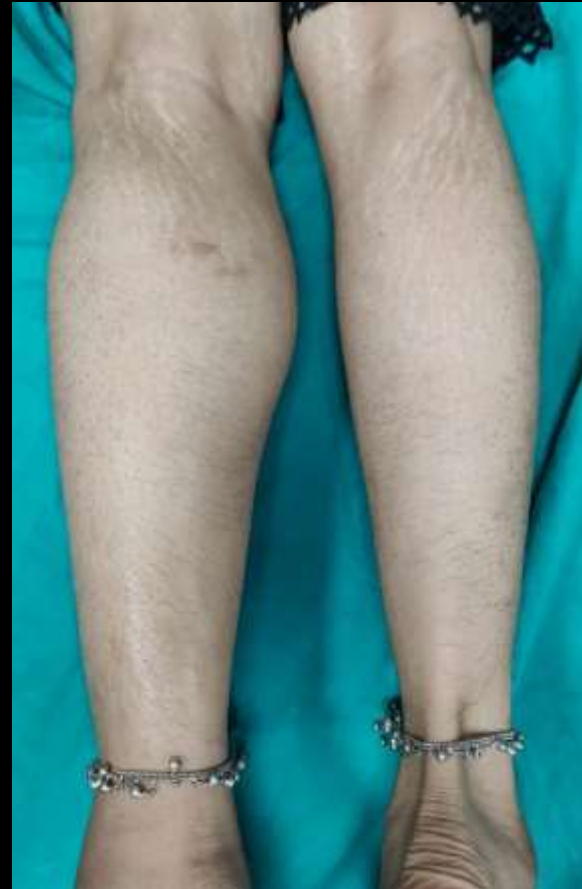Case contributor – Dr. Sonal Saran

MI-COD

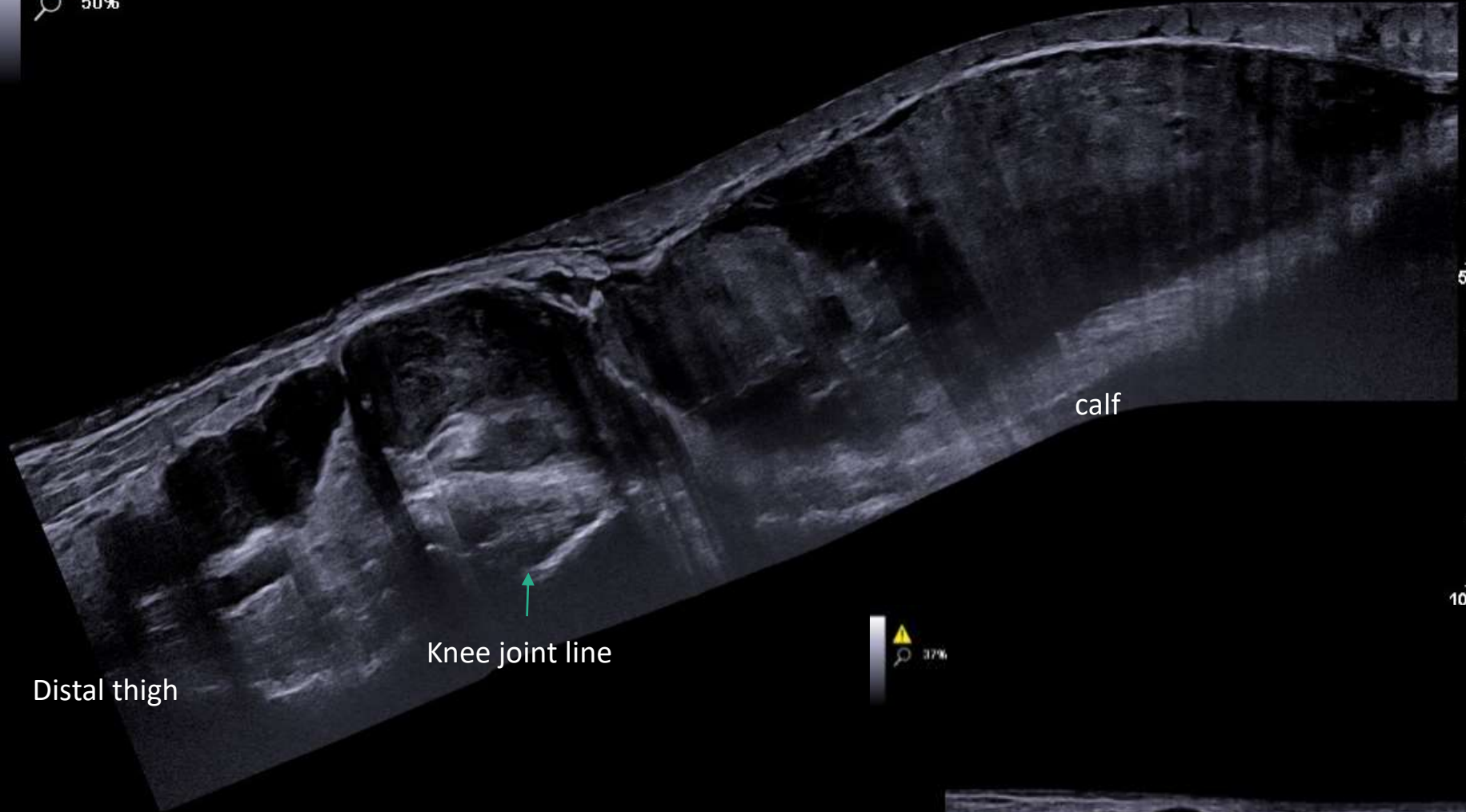
MSS INDIA- Case Of the Day



- A 30 year old female with known rheumatoid arthritis presented with left calf pain and mass.



50%



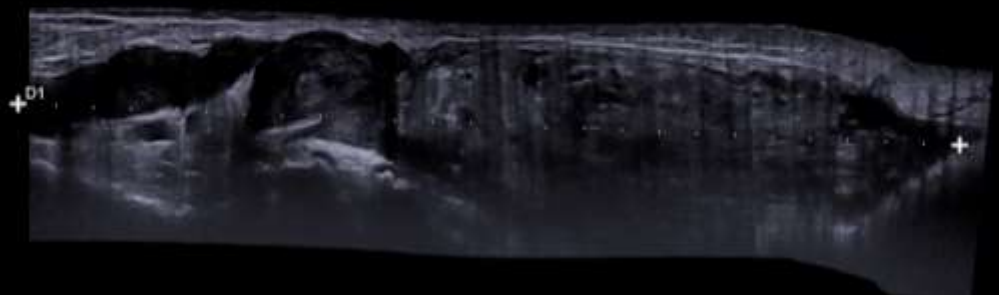
Distal thigh

Knee joint line

calf

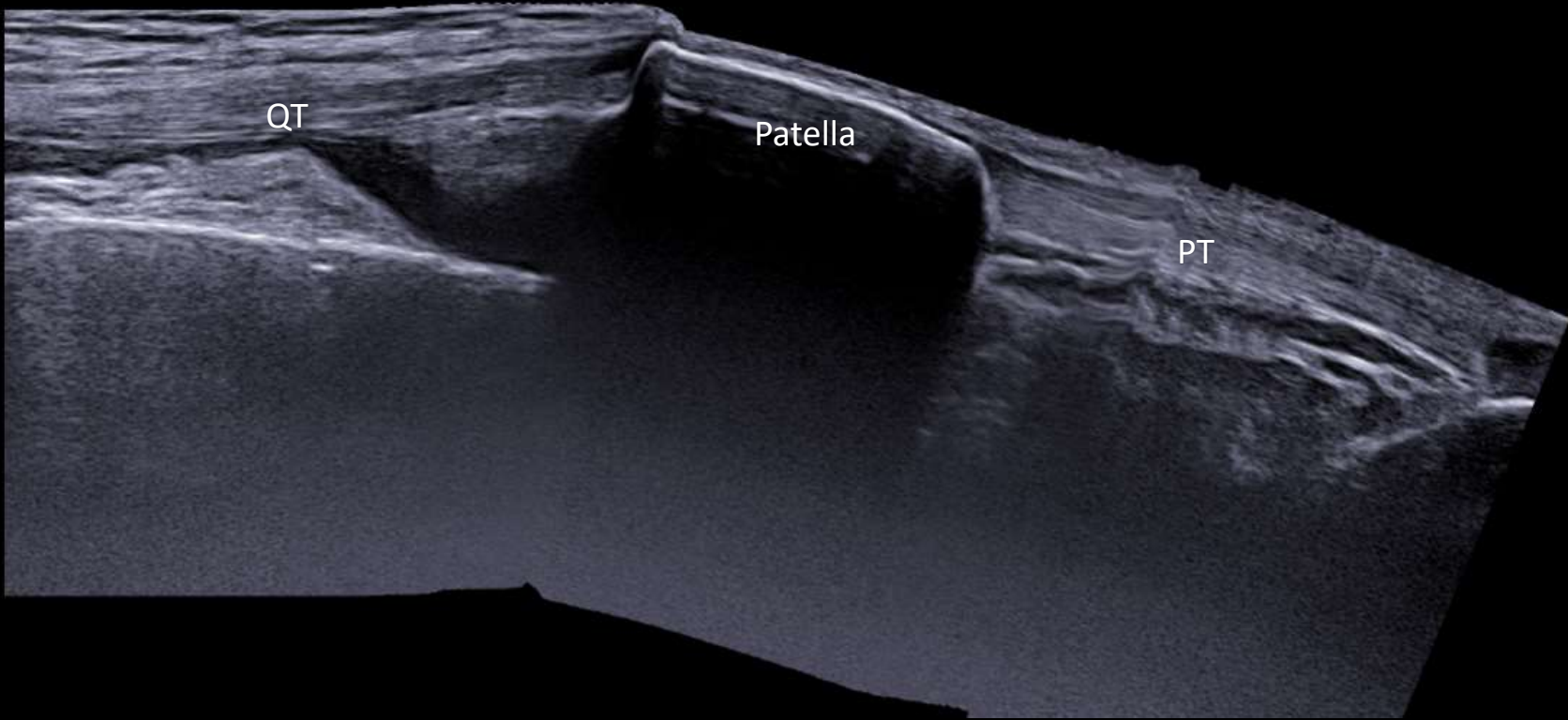D1 249.5 mm

37%



+D1

+



QT

Patella

PT

What is the diagnosis?