

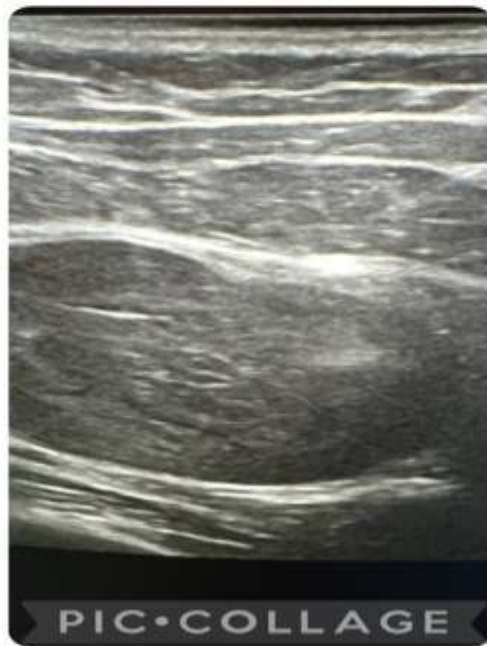
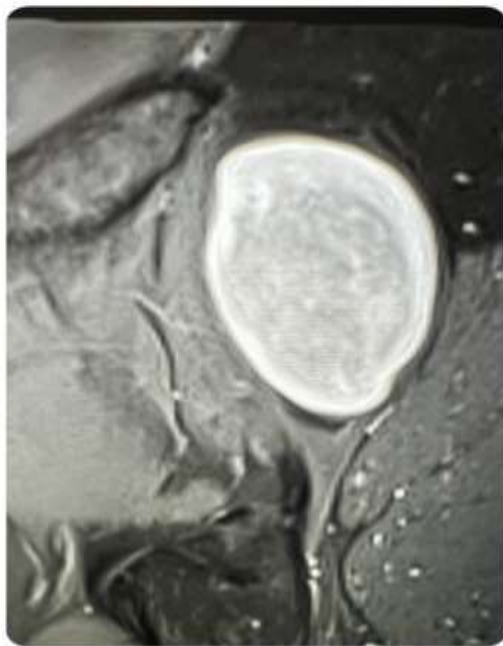
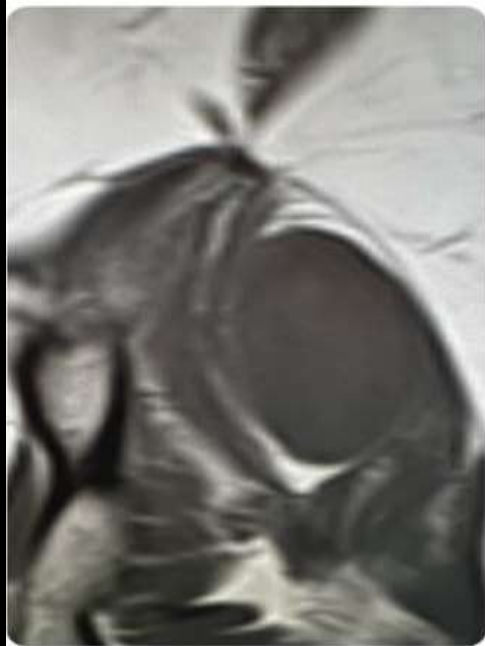
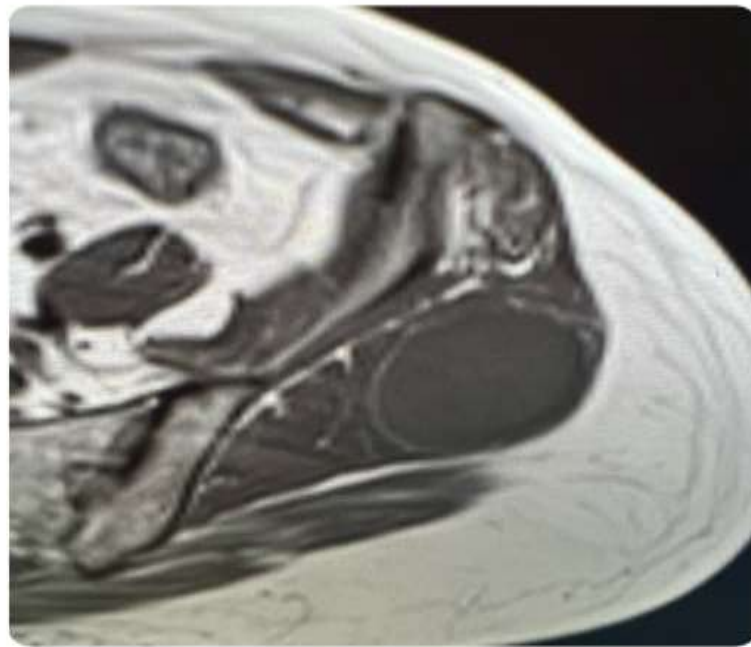
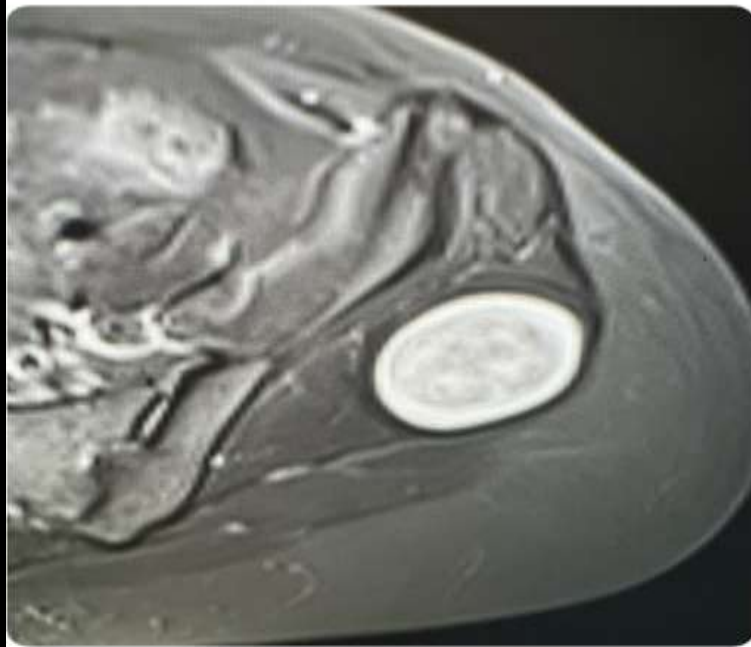
MICOD – 22/03/2024

Case contributor – Dr. Harun gupta (MSK Teaching Room)

# MI-COD

MSS INDIA- Case Of the Day





PIC•COLLAGE

Middle aged patient

Findings and D/d.