

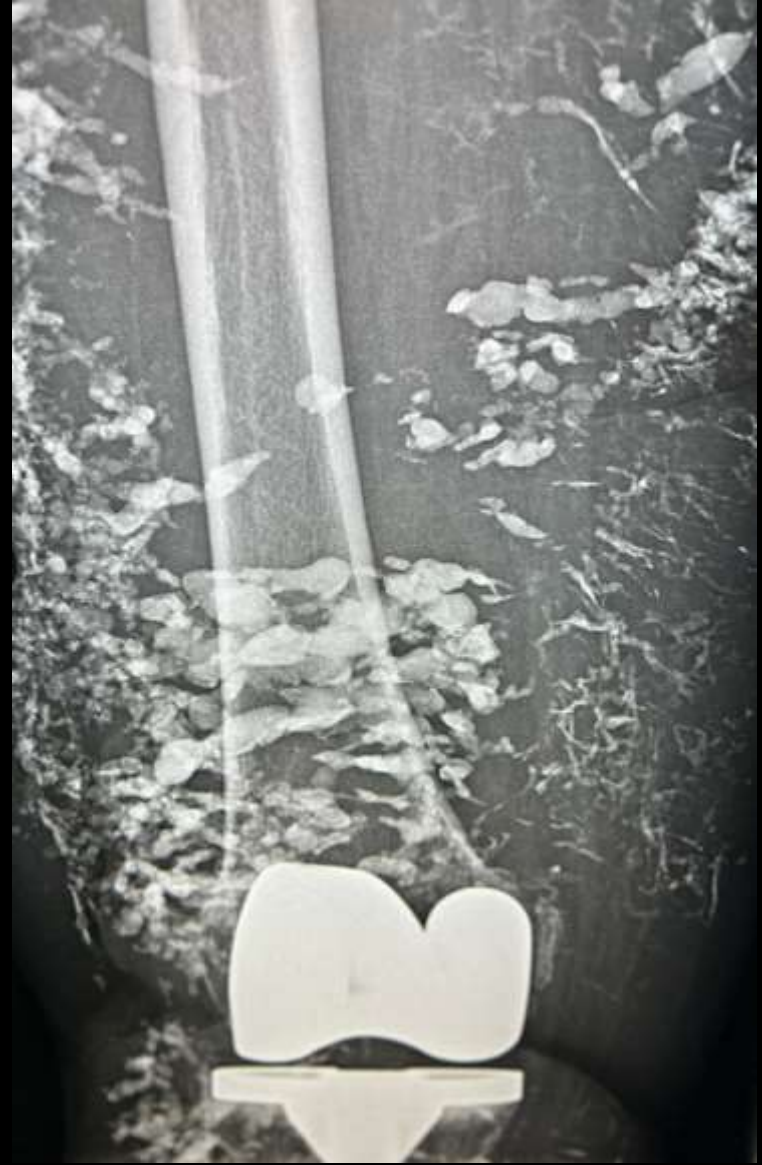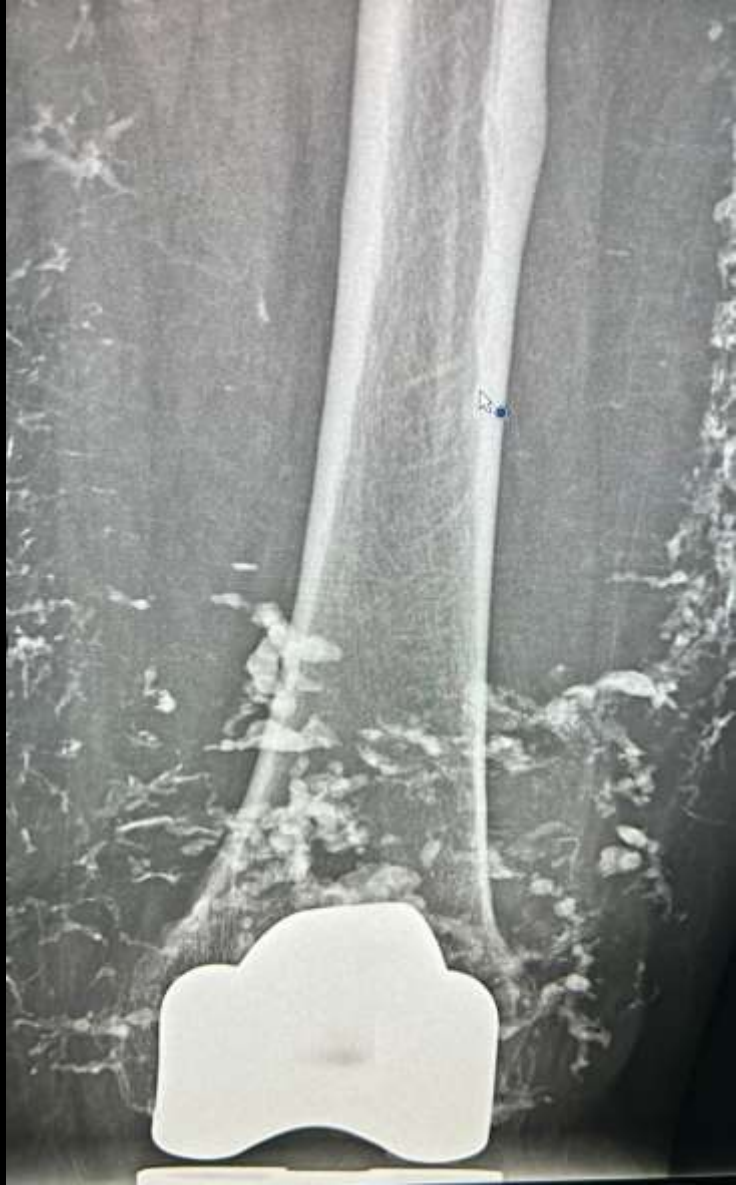
MICOD – 21/03/2024

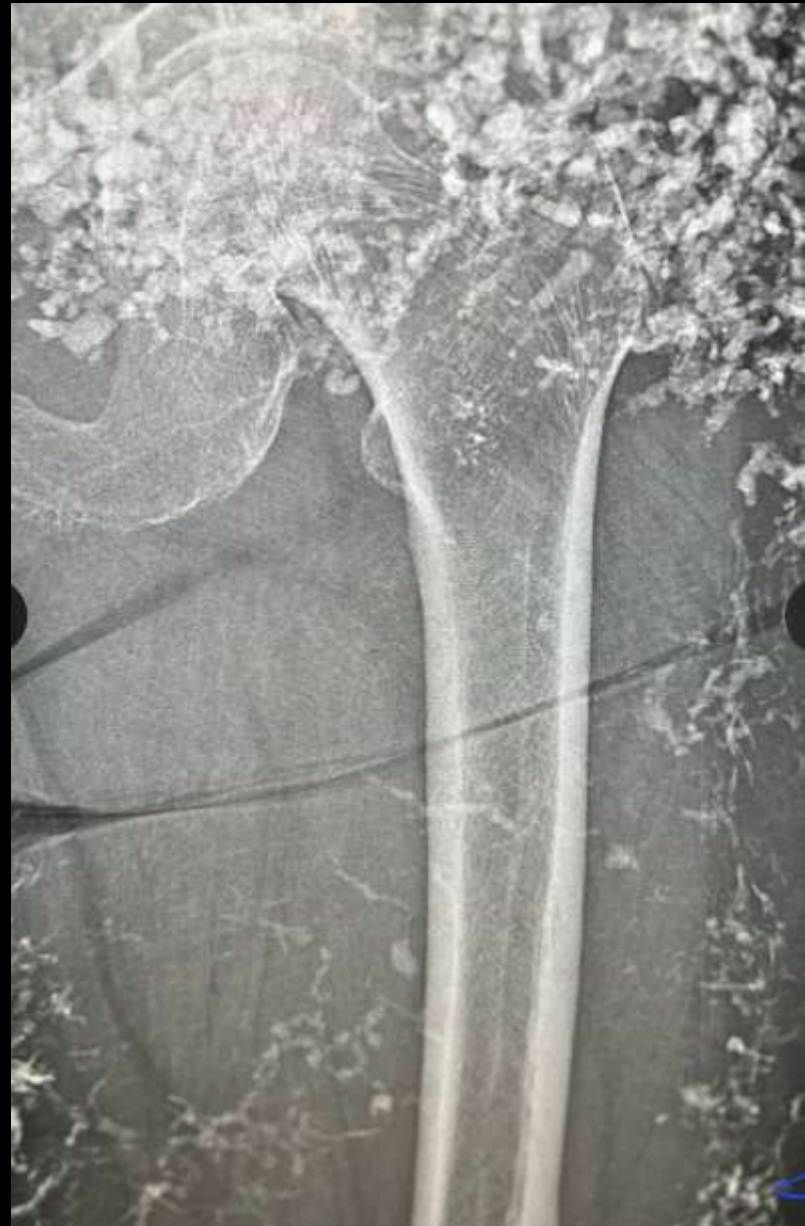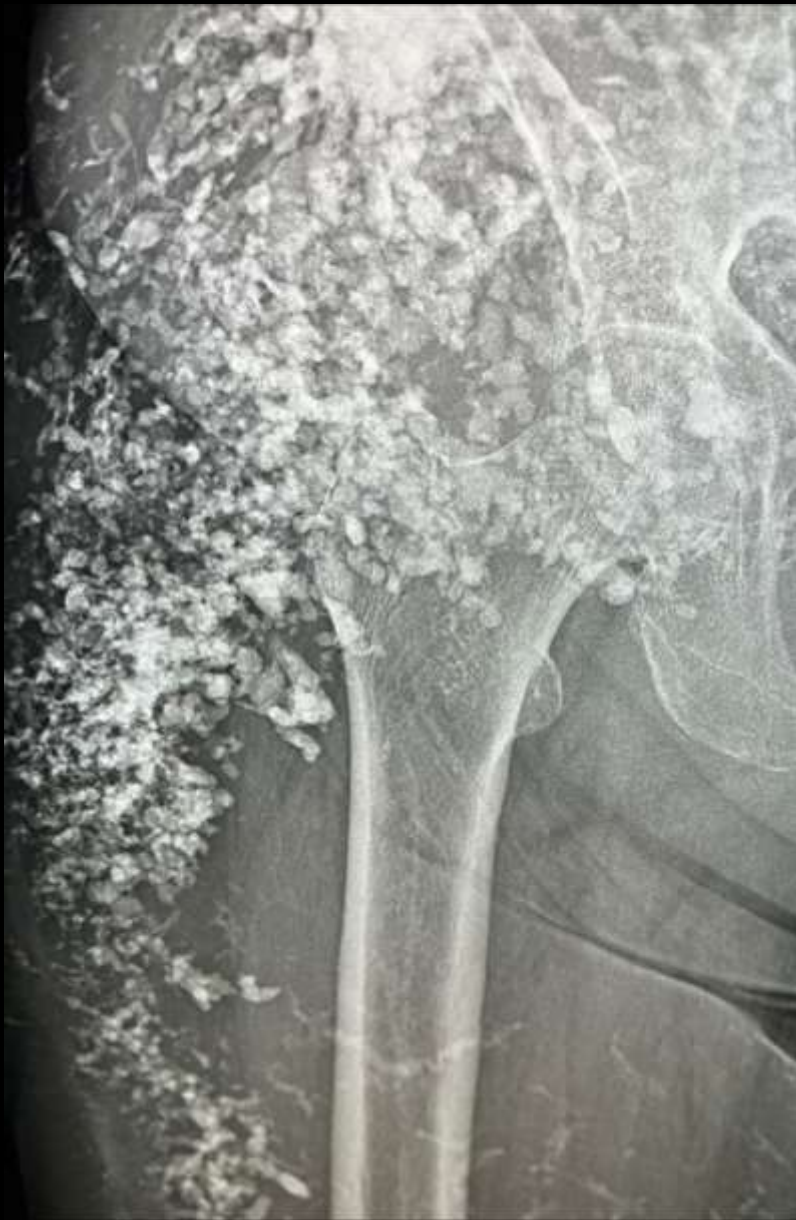Case contributor – Dr. Harun gupta (MSK Teaching Room)

MI-COD

MSS INDIA- Case Of the Day







Middle aged female.

What are the findings and Diagnosis?