

MICOD -20/03/2024

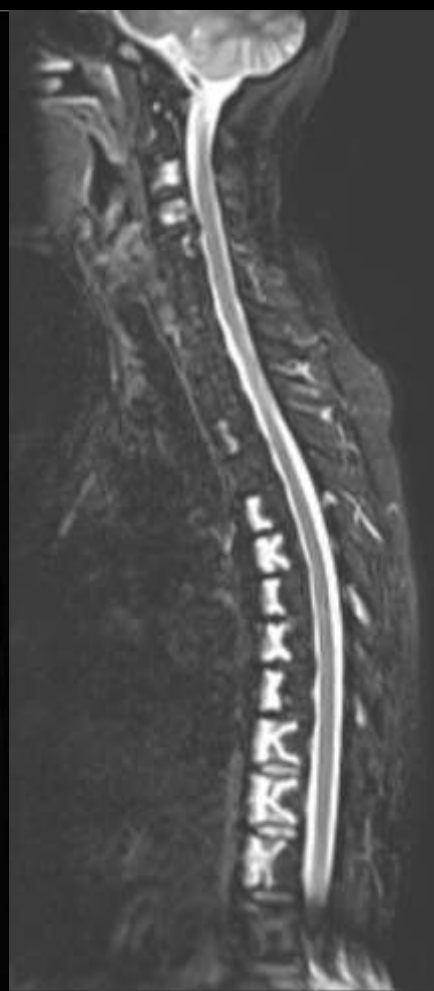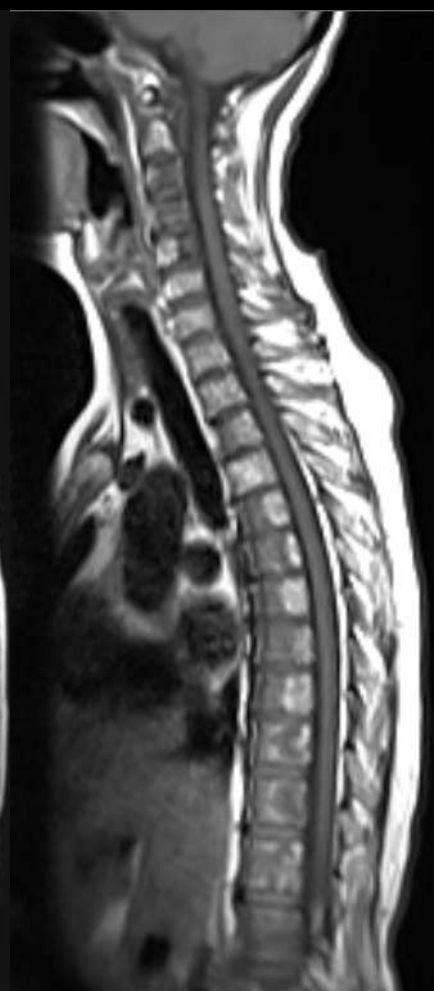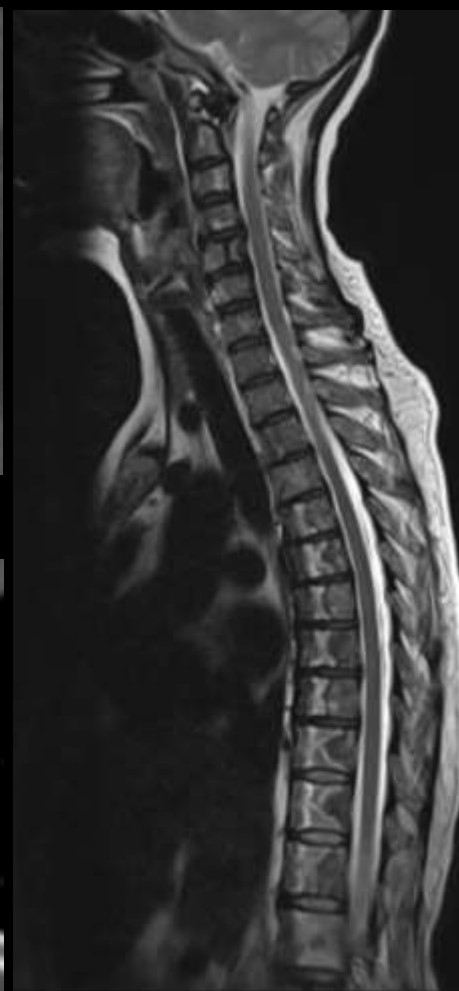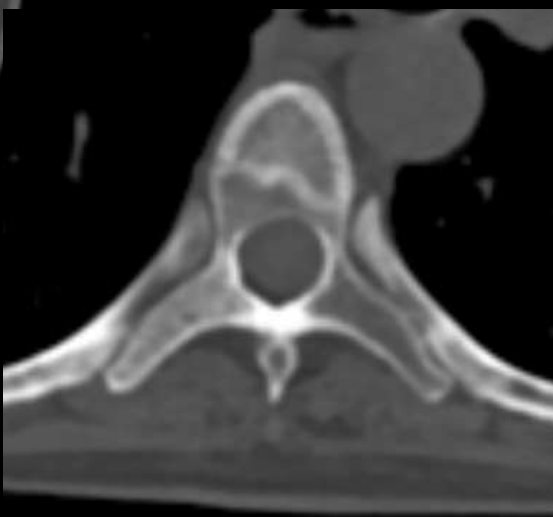
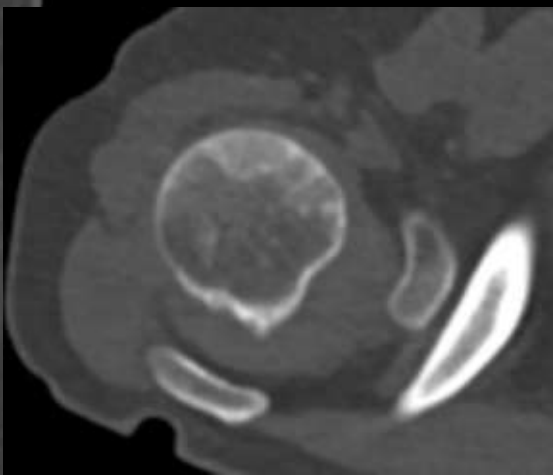
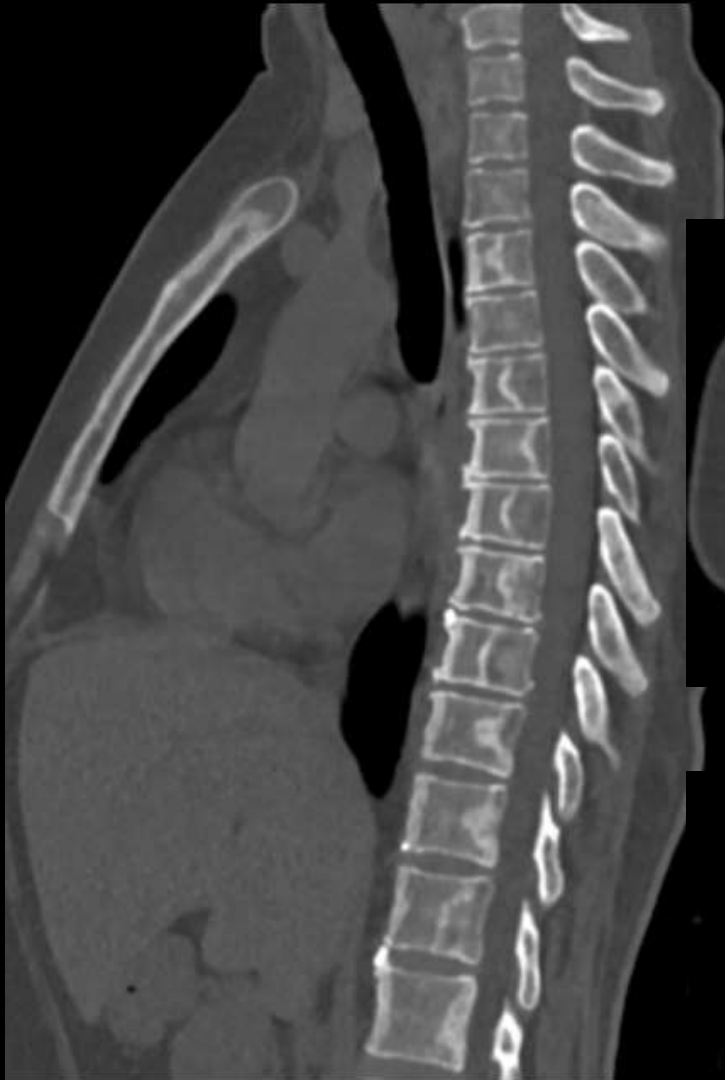Case contributor – Dr. Sonal Saran

MI-COD

MSS INDIA- Case Of the Day



- A 52-year-old woman with Diffuse Large B-cell Lymphoma on treatment (6 cycles of chemotherapy using the R-CVP regimen (Rituximab, Cyclophosphamide, Vincristine, and Prednisolone)).
- During the fifth cycle of chemotherapy, the patient began experiencing breathing difficulties and back pain.
- Subsequent HRCT thorax and MRI of the whole spine were performed.



What is the diagnosis?