


MICOD – 07/03/2024

Case contributor – Dr. Surendra Kumar Bugata

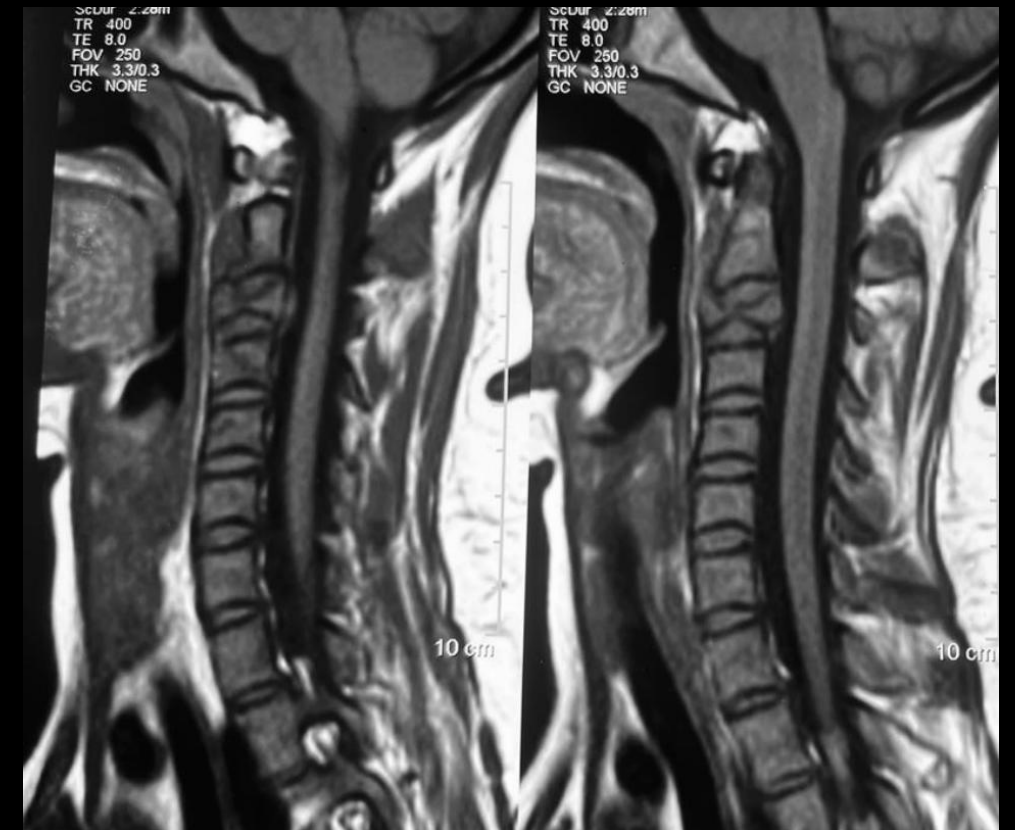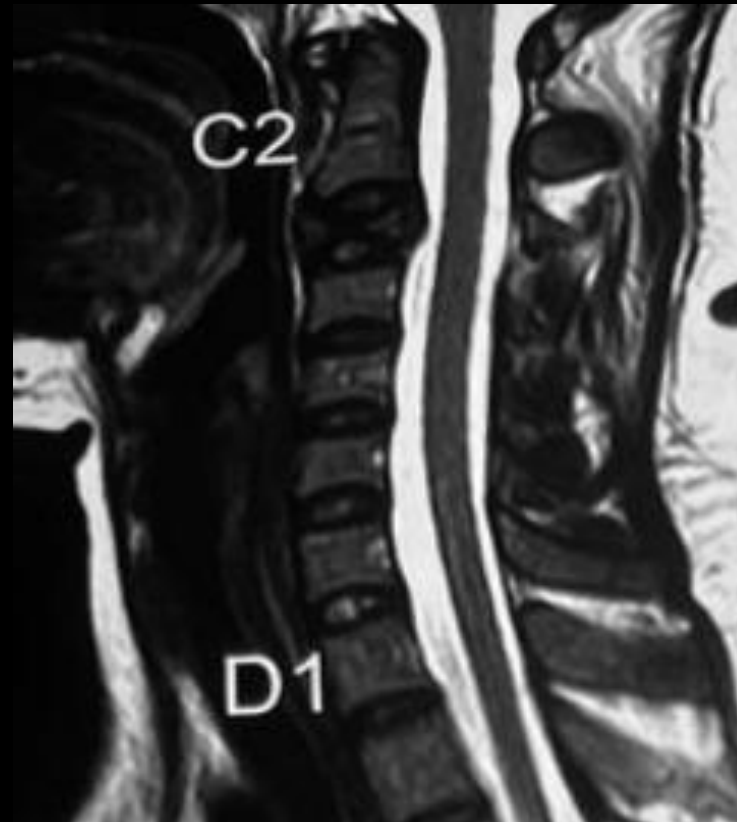
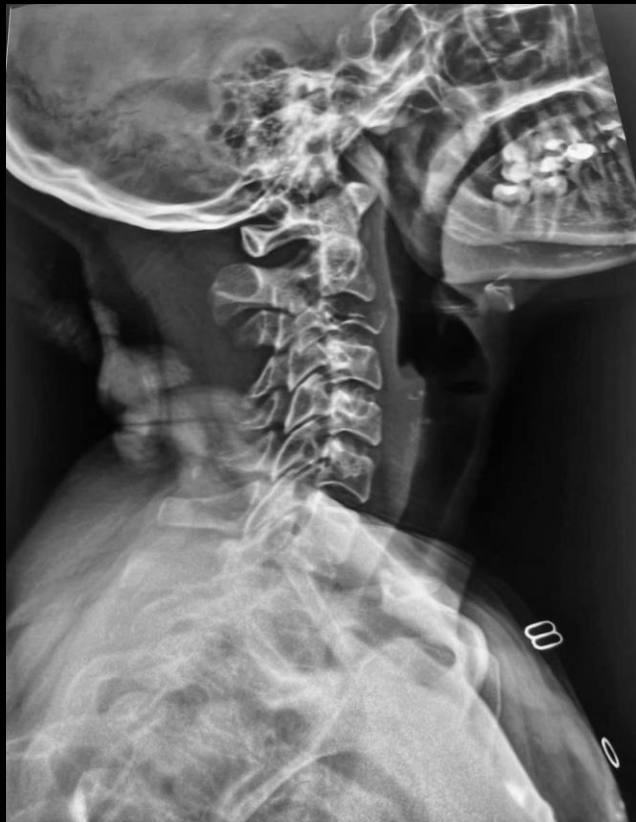MI-COD

MSS INDIA- Case Of the Day



26-year-old lady with history of neck pain, since 6 months
Visited doctor after 3 months from the first symptom and investigated with plain radiograph followed by MRI of cervical spine.

Nov 2023



Patient was lost to follow up, came back with increased neck pain this month, no neurological deficits & repeat Radiograph and MRI were done
What is the diagnosis at this stage?



