

MICOD – 20/02/2024

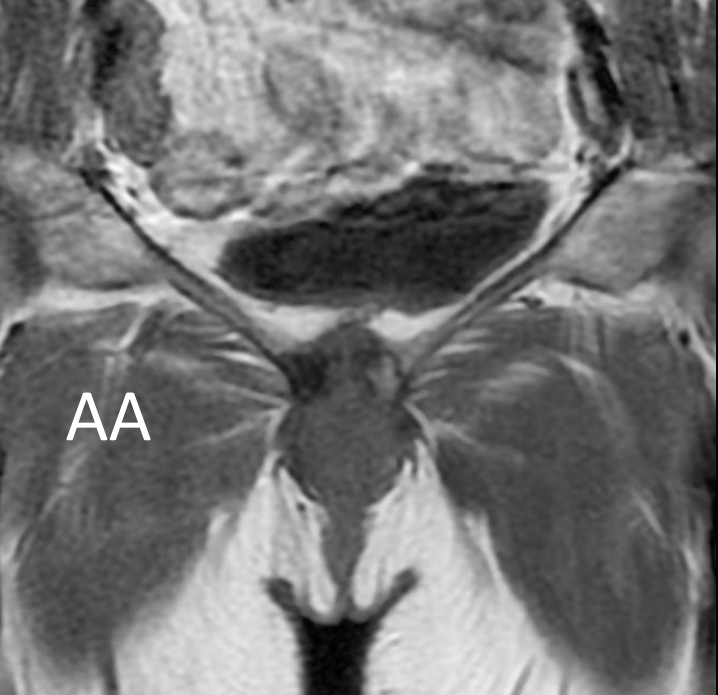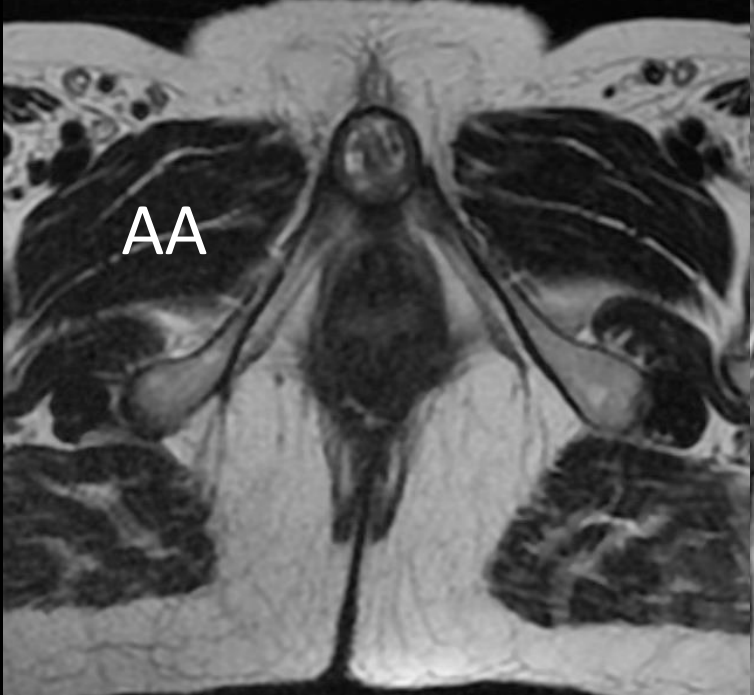
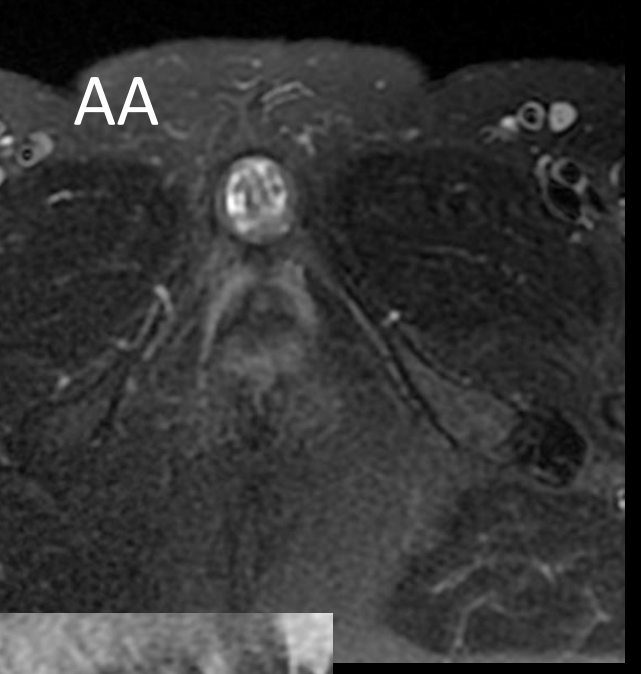
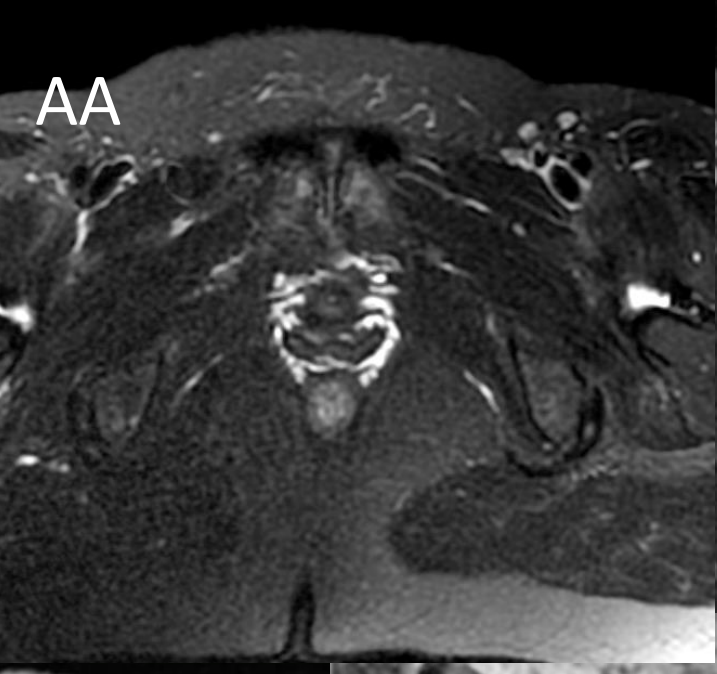
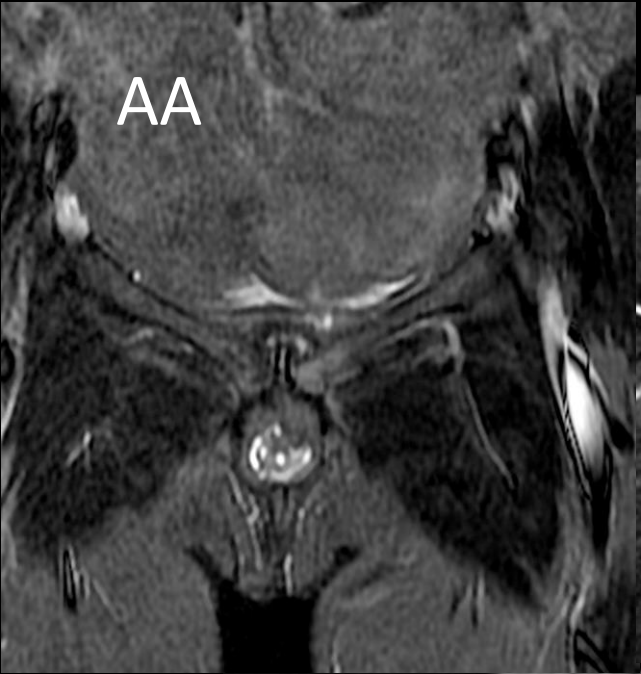Case contributor – Dr. Ankita Ahuja

MI-COD

MSS INDIA- Case Of the Day



- 65 year old female with pubic pain.



- What is your diagnosis?