


MICOD – 14/02/2024

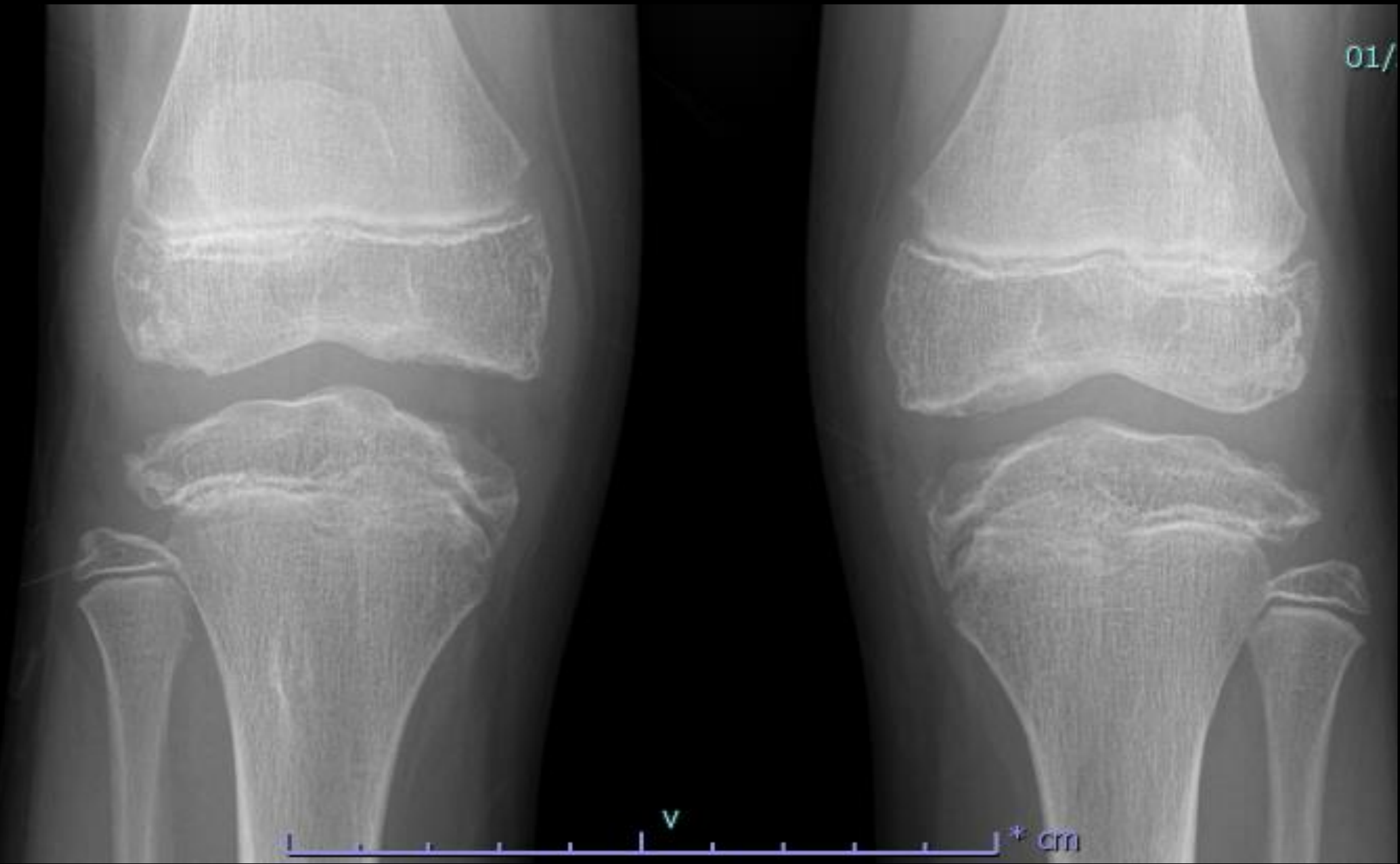
Case contributor – Dr. Sameer Raniga

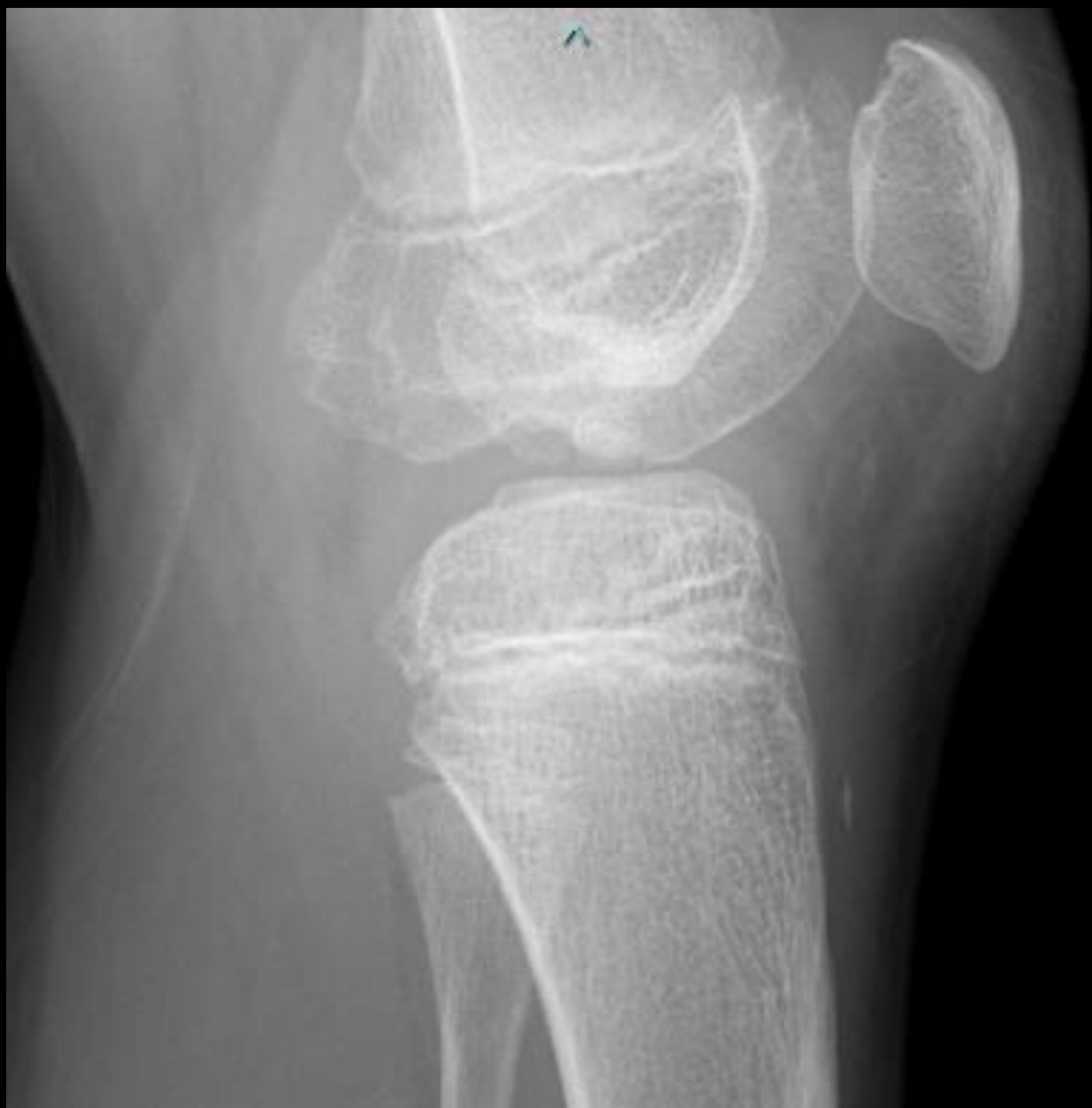# MI-COD

MSS INDIA- Case Of the Day



13 years old with knee pain  
AP and Lateral knee radiographs





# Questions

- 1. What underlying disorder you would consider?**
- 2. Is this a side effect of a treatment used in this disorder?**
- 3. Differential diagnosis?**