

Case Courtesy: Dr. Uma Maheshwara Reddy V, Professor, NMCH  
Consultant Radiologist, Clarity scans, Nellore

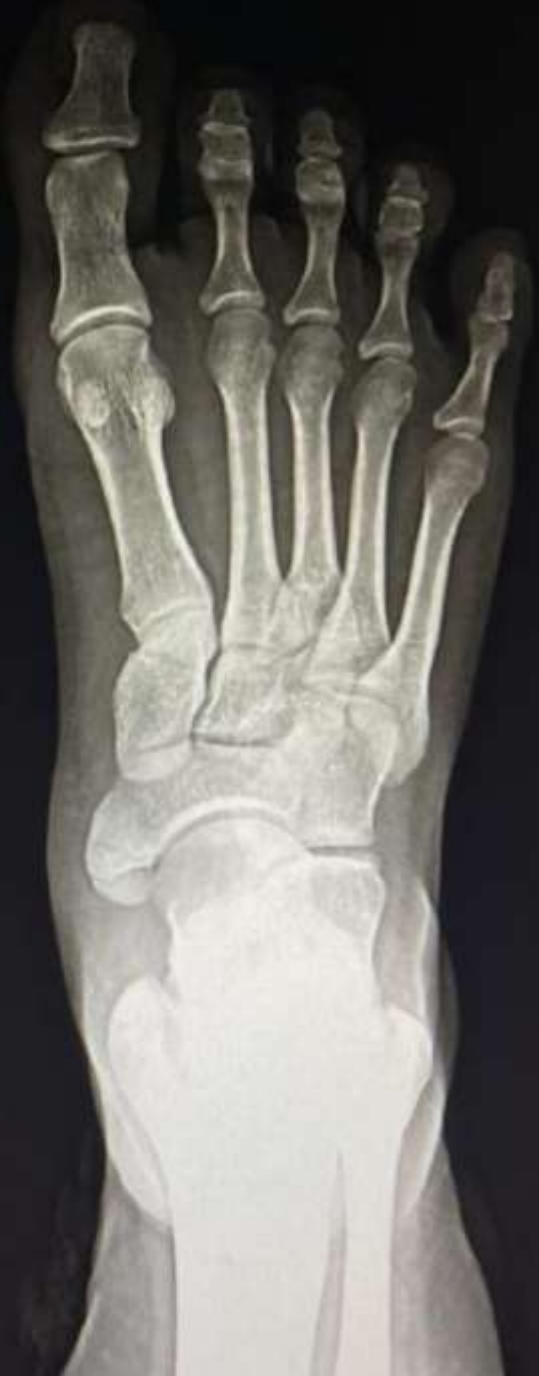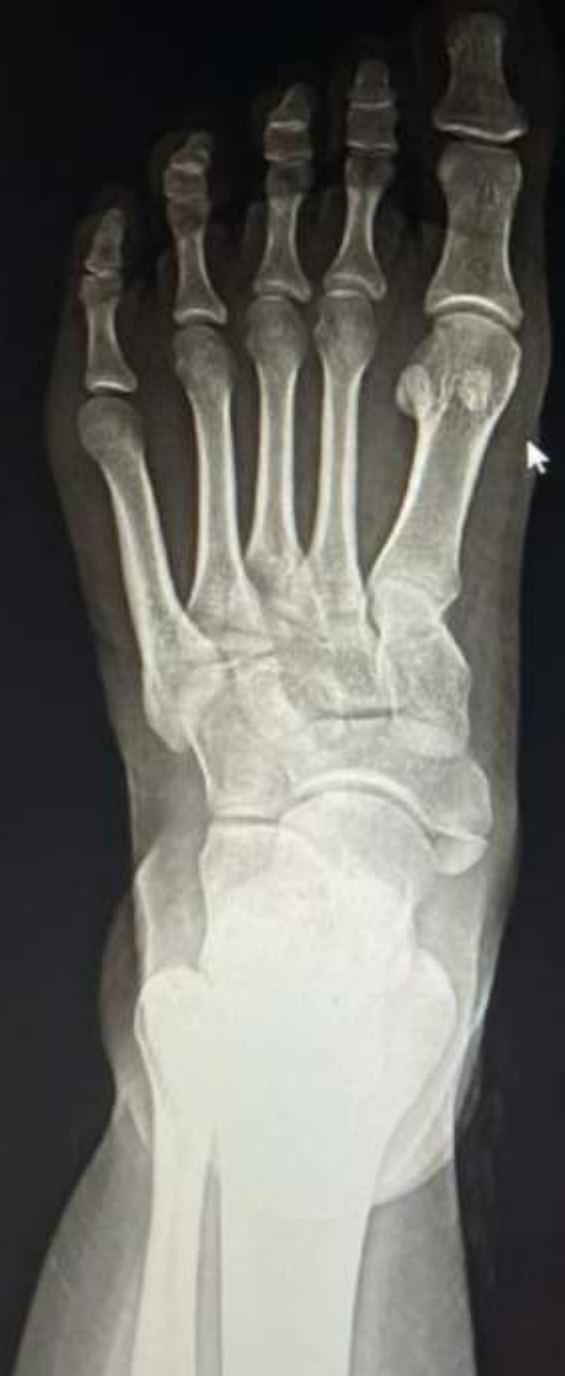# MI-COD

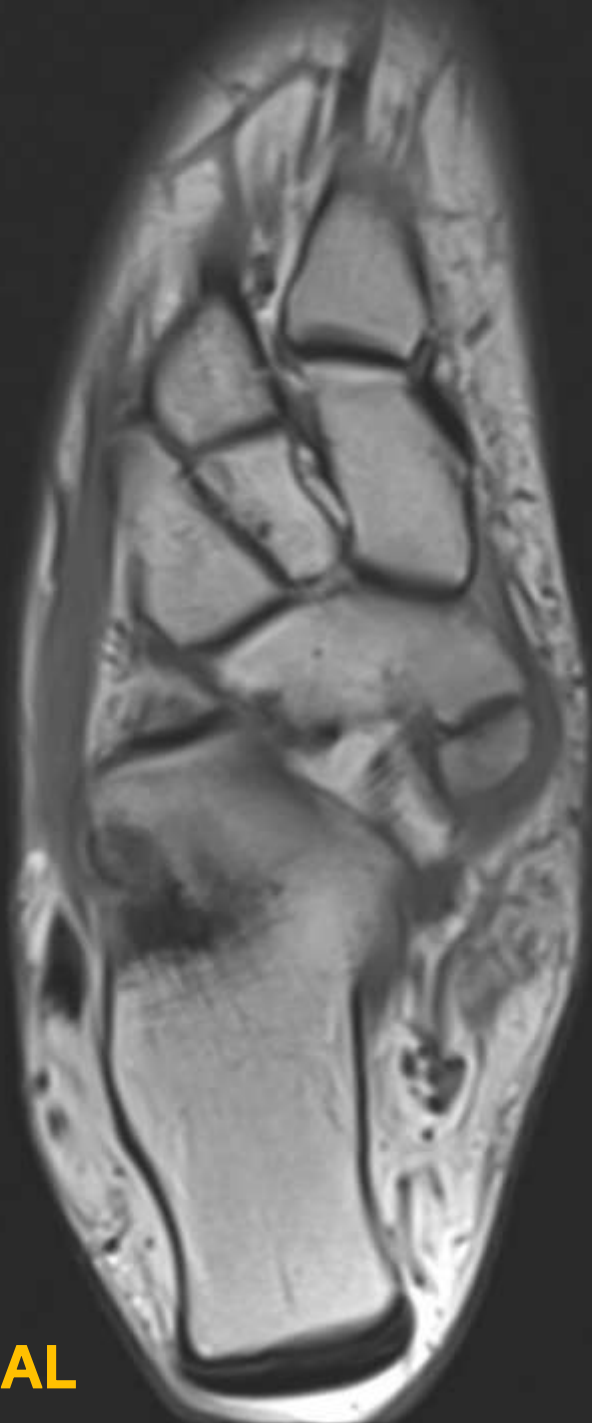
MSS INDIA- Case Of the Day



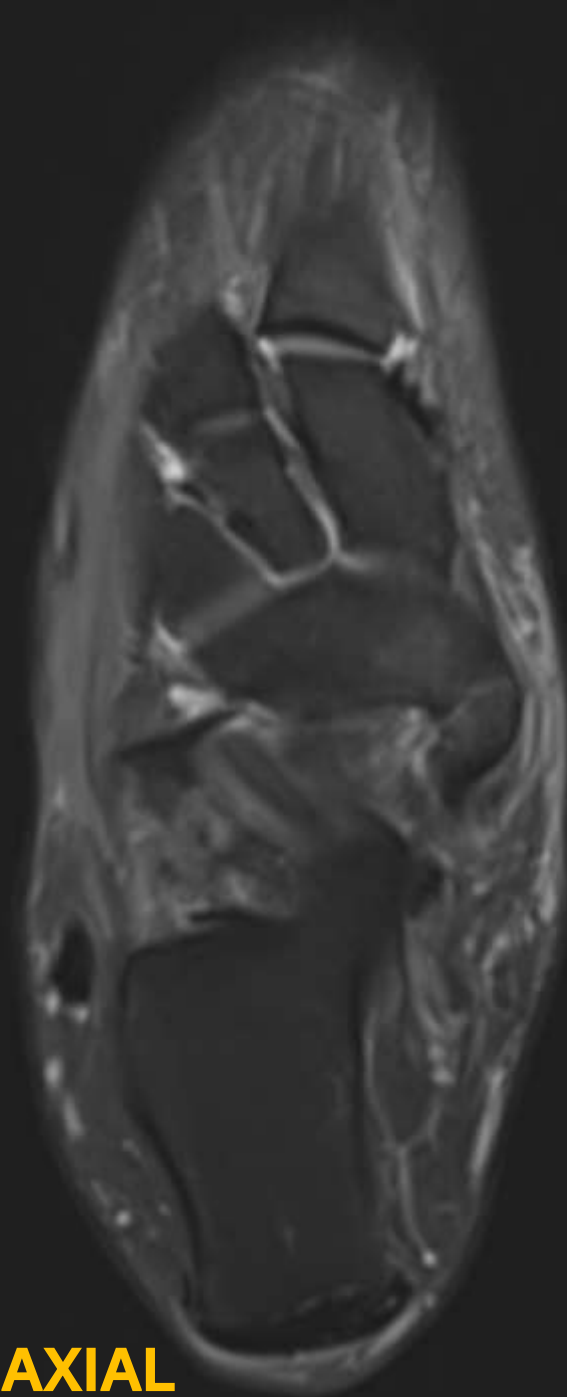
## CLINICAL HISTORY

- 35-year-old male patient presented with swelling and pain over medial aspect of left foot.
- In view of the above clinical history, the patient was subjected to X-ray foot with ankle and MRI Right Foot with Ankle.

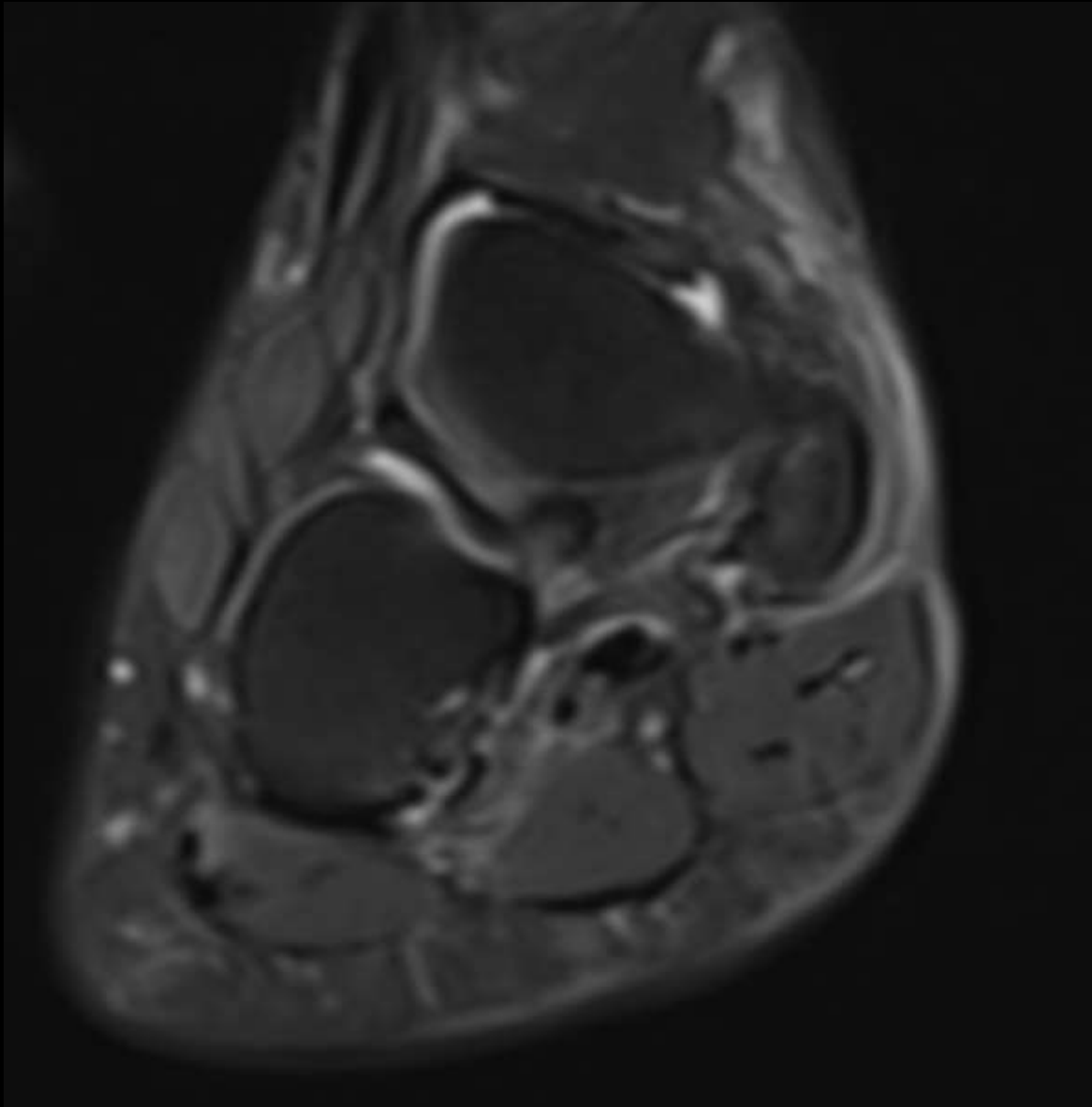




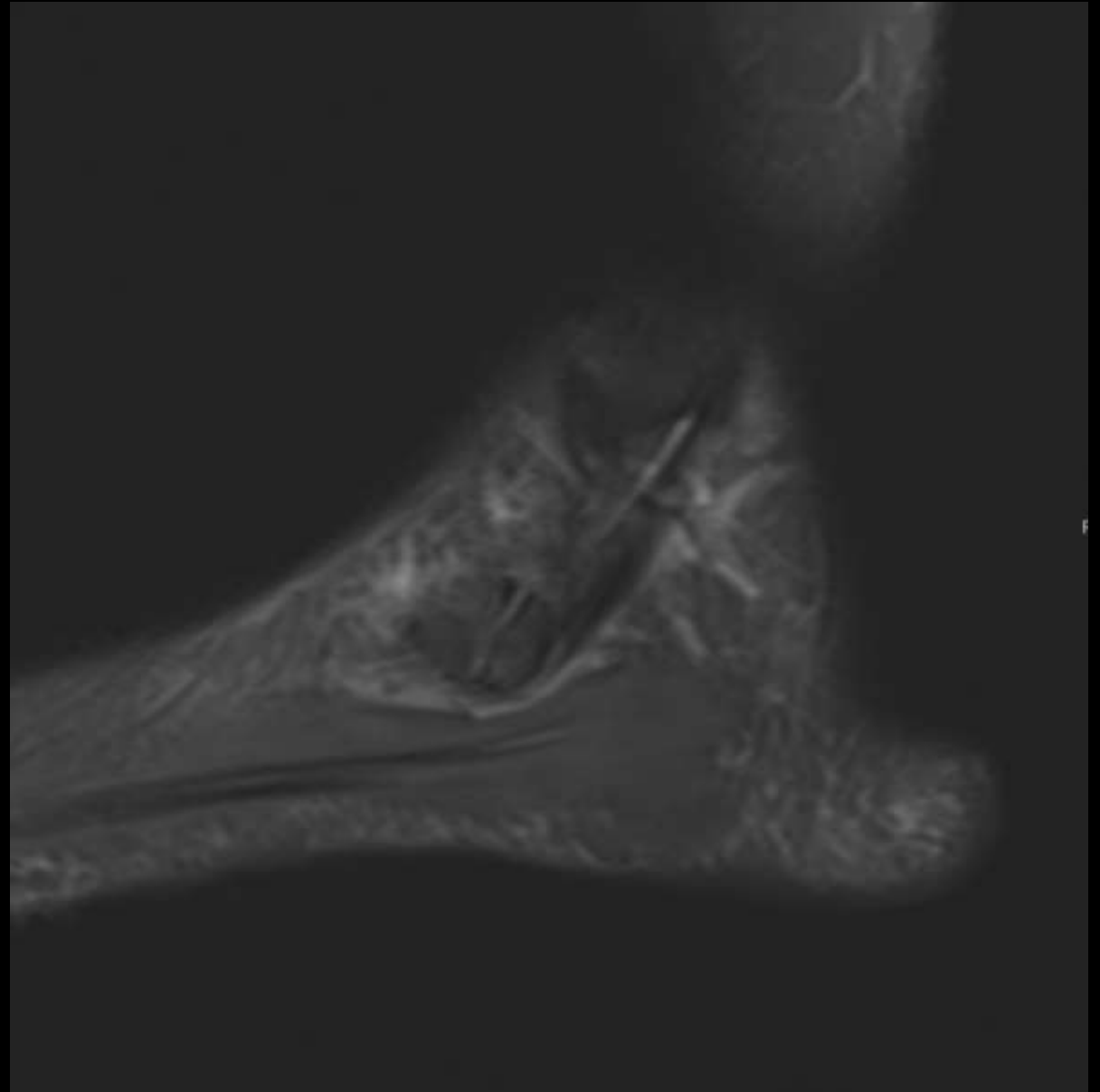
**PD AXIAL**



**PDFS AXIAL**



**PDFS CORONAL**



**PDFS SAGITTAL**

1. What are the findings ?

2. What is pathophysiology for this condition, what are aggravating factors ?

3. What is the final diagnosis ?