

MICOD – 08/02/2024

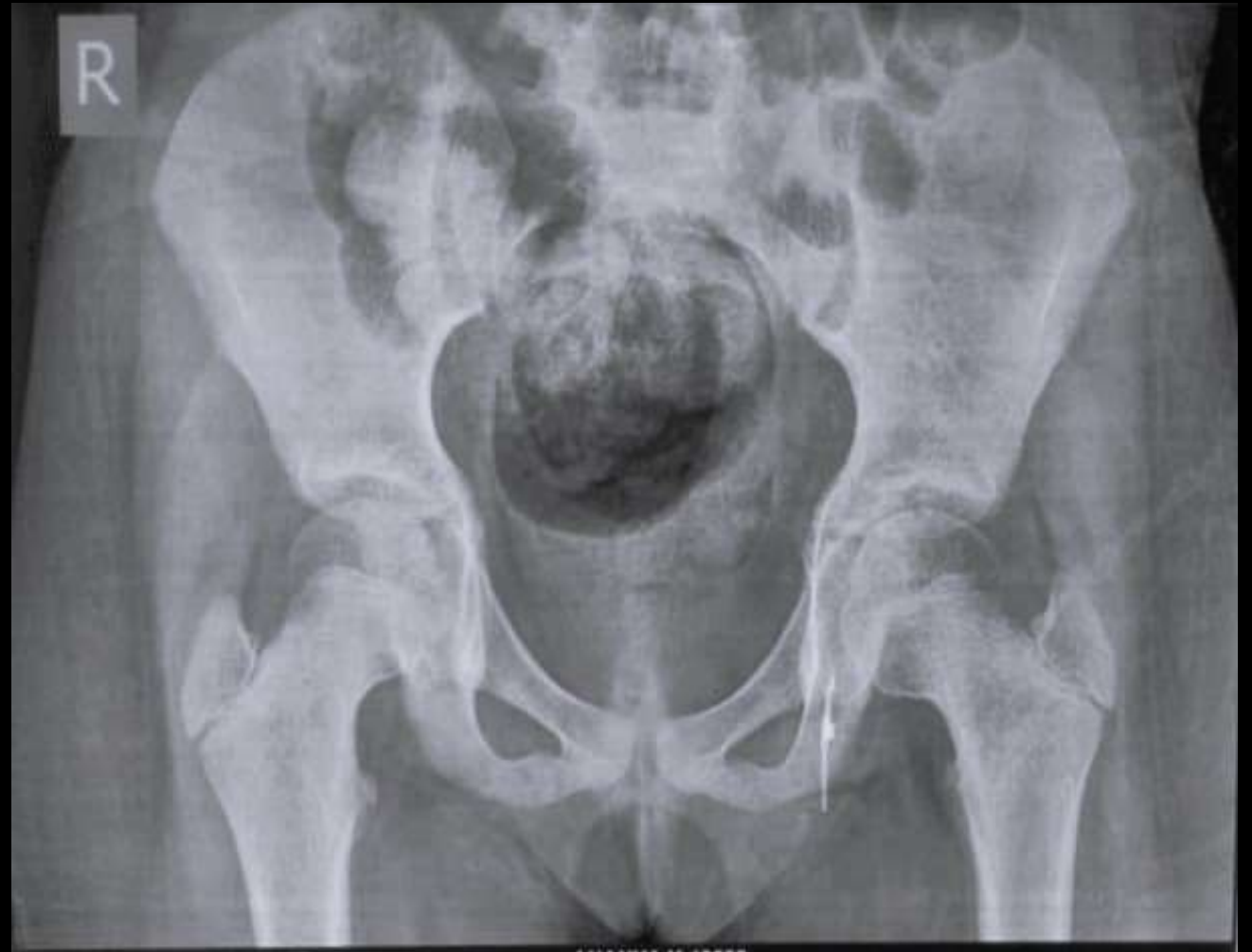Case contributor – Dr. Ravinder Kaur

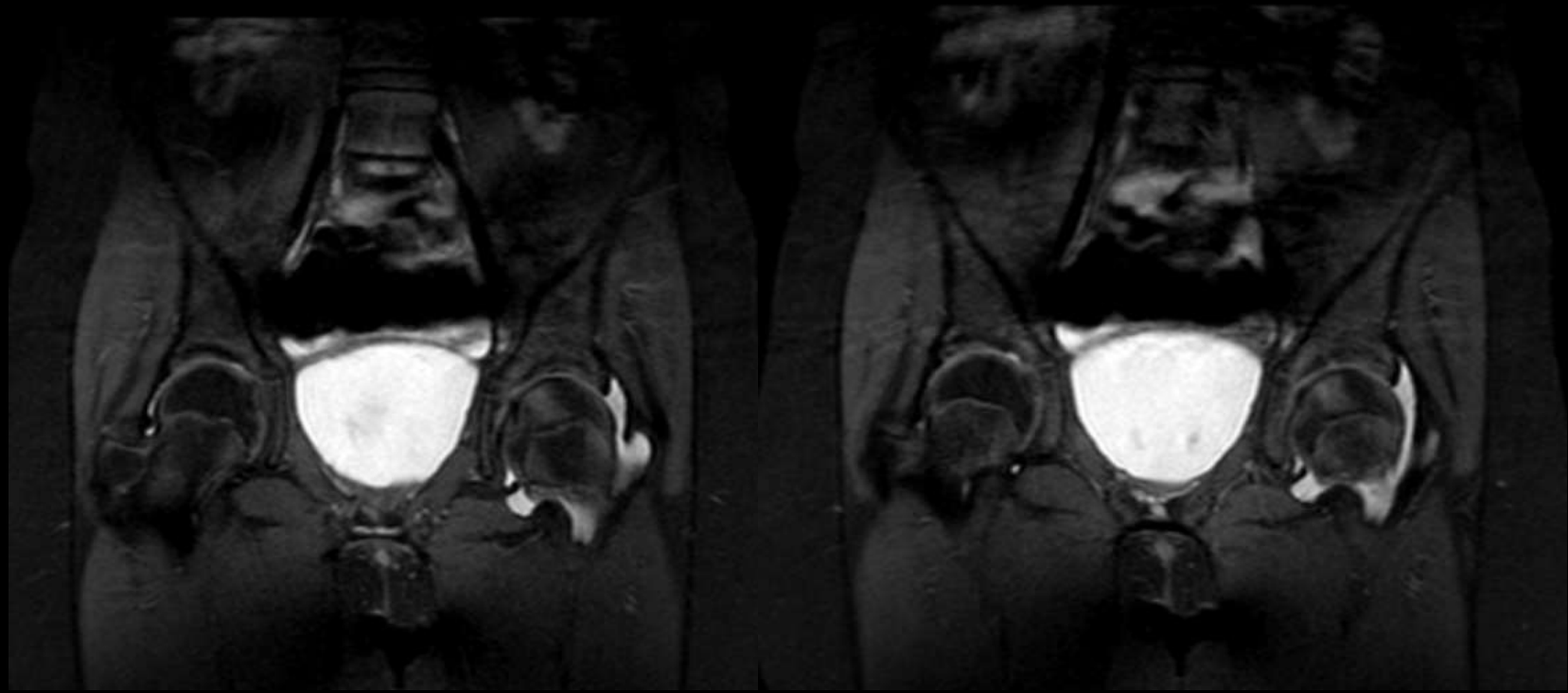
# MI-COD

MSS INDIA- Case Of the Day

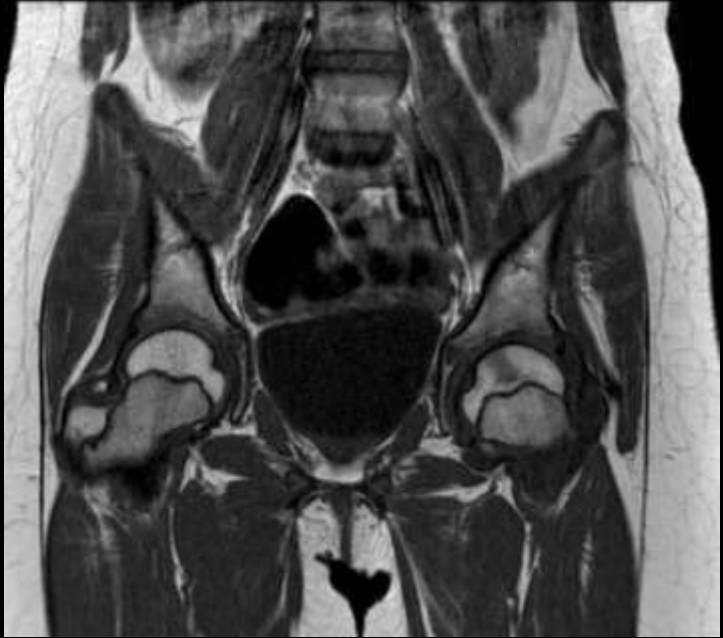

9 year old female with H/O of pain & restricted movements in left hip joint for one month.  
No H/O fever , significant trauma .  
TLC/DLC/ESR/CRP - Normal

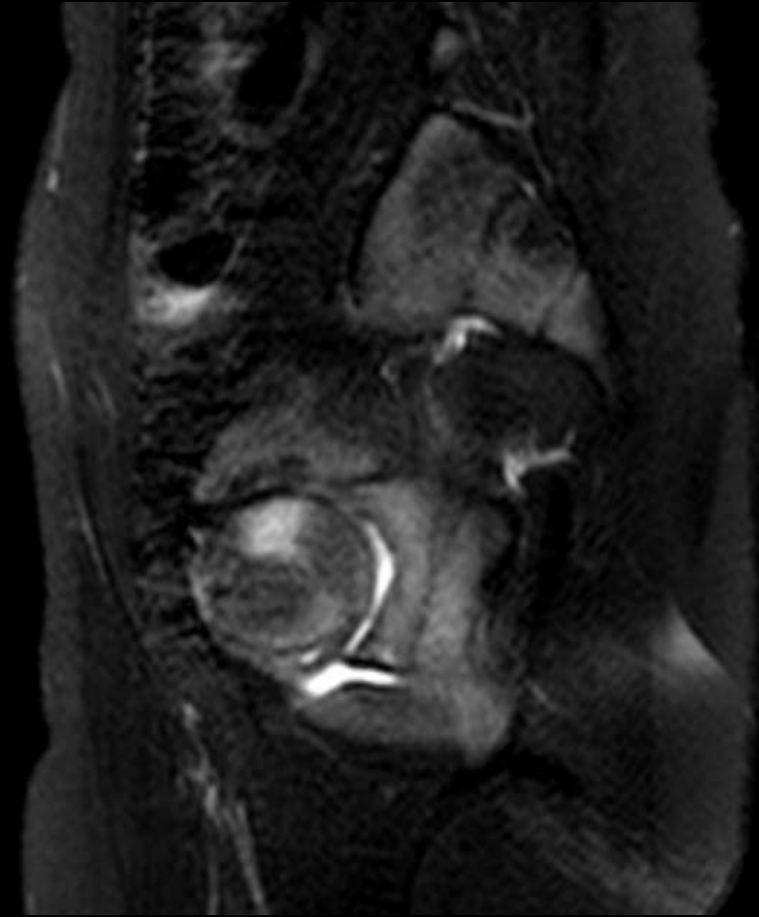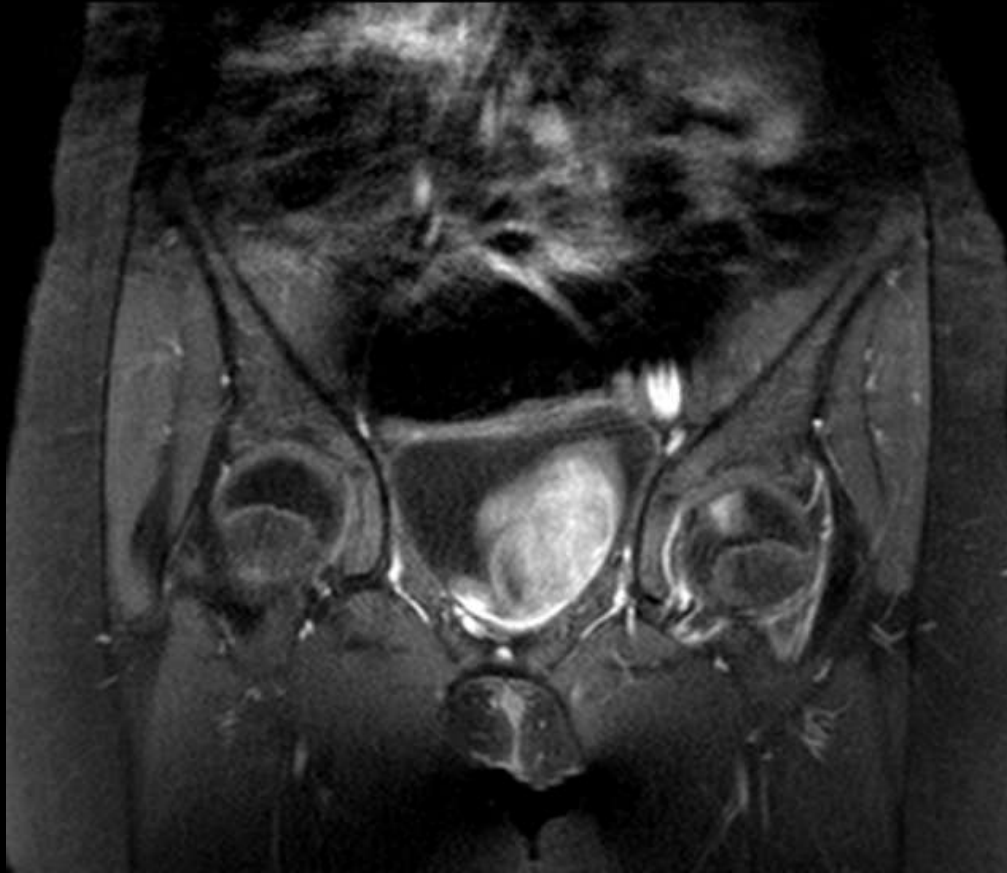




STIR



T1W



Post contrast

Diagnosis?