

MICOD – 06/02/2024

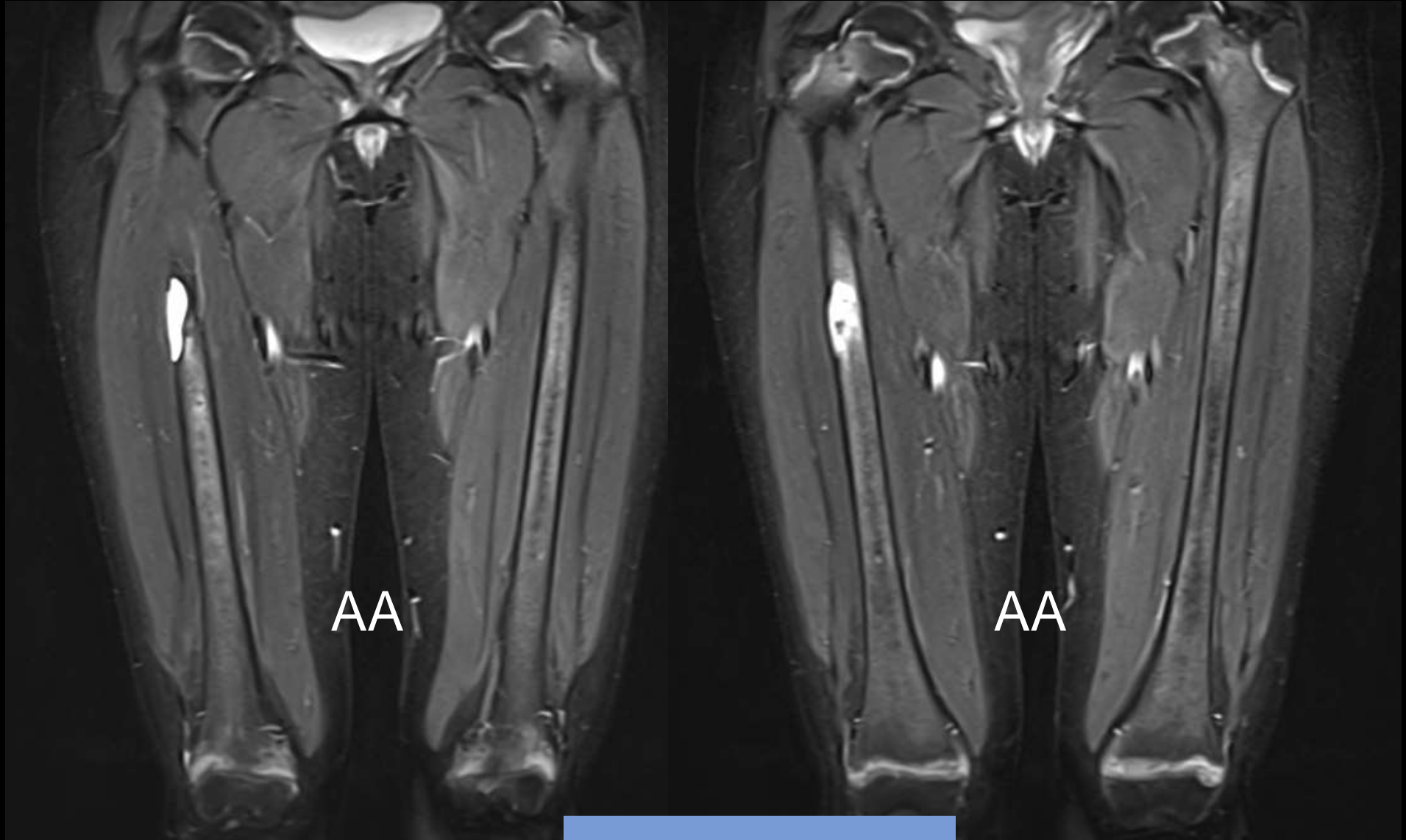
Case contributor – Dr. Ankita Ahuja

# MI-COD

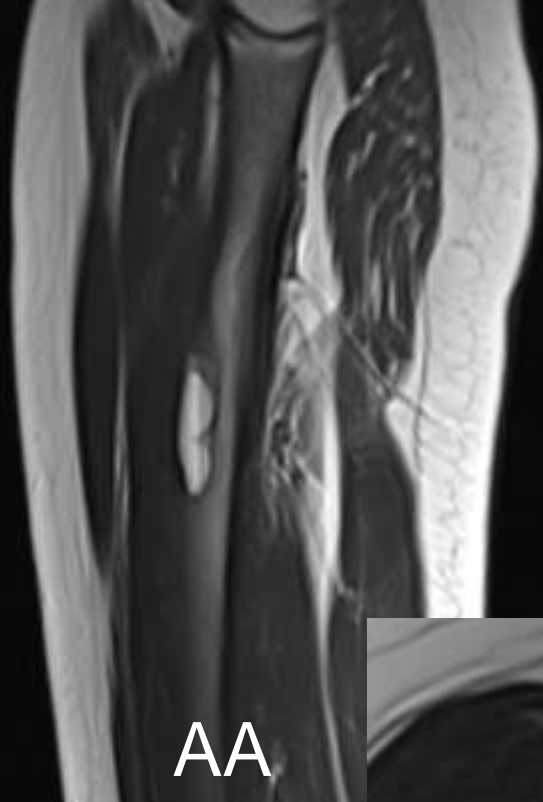
MSS INDIA- Case Of the Day



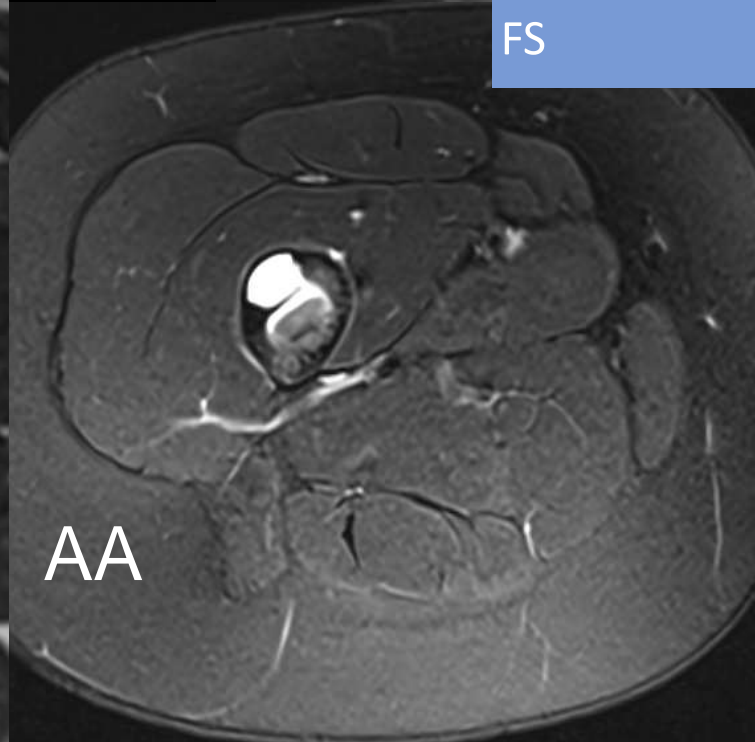
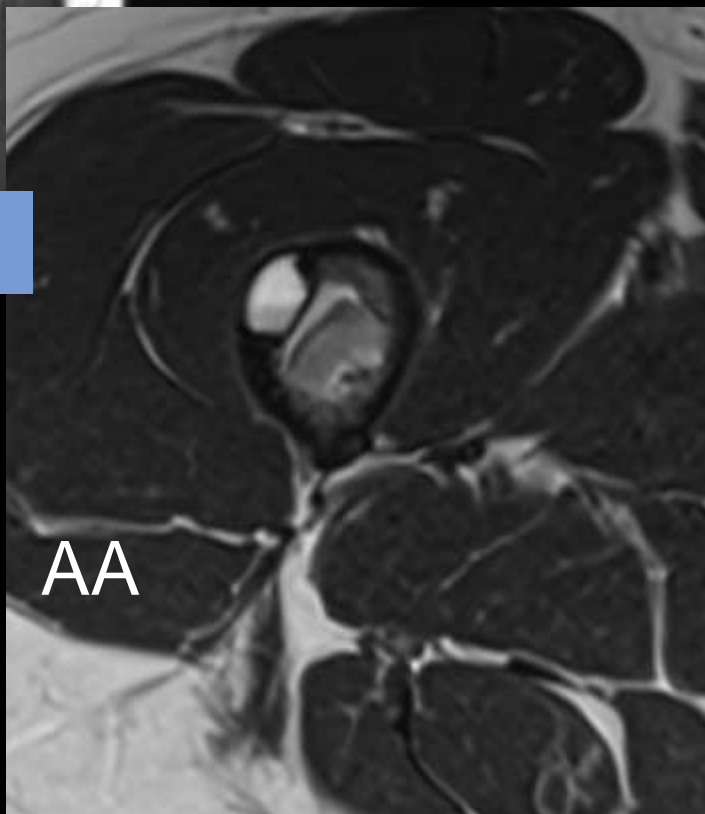
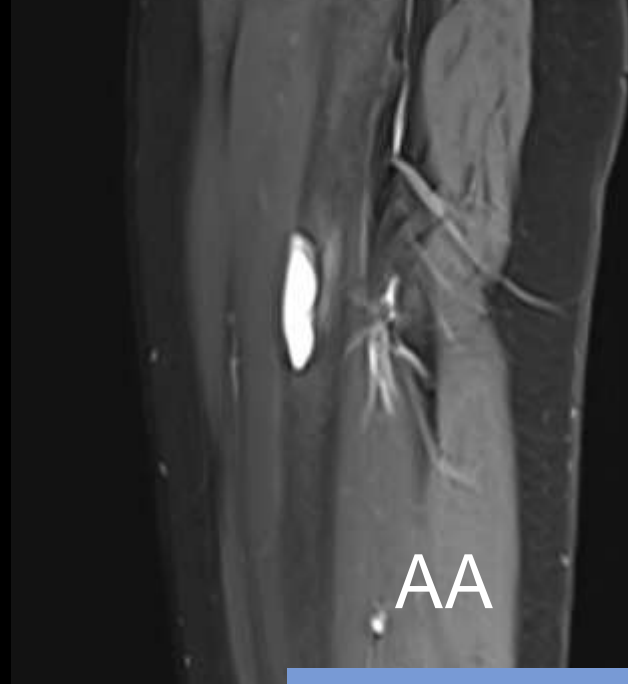
**A young female with pain in right thigh.**

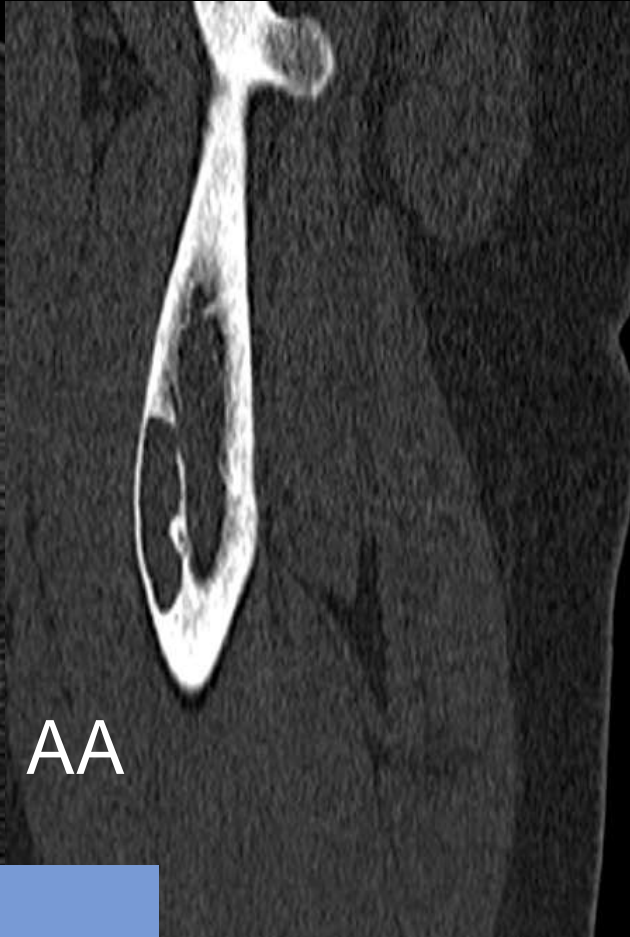
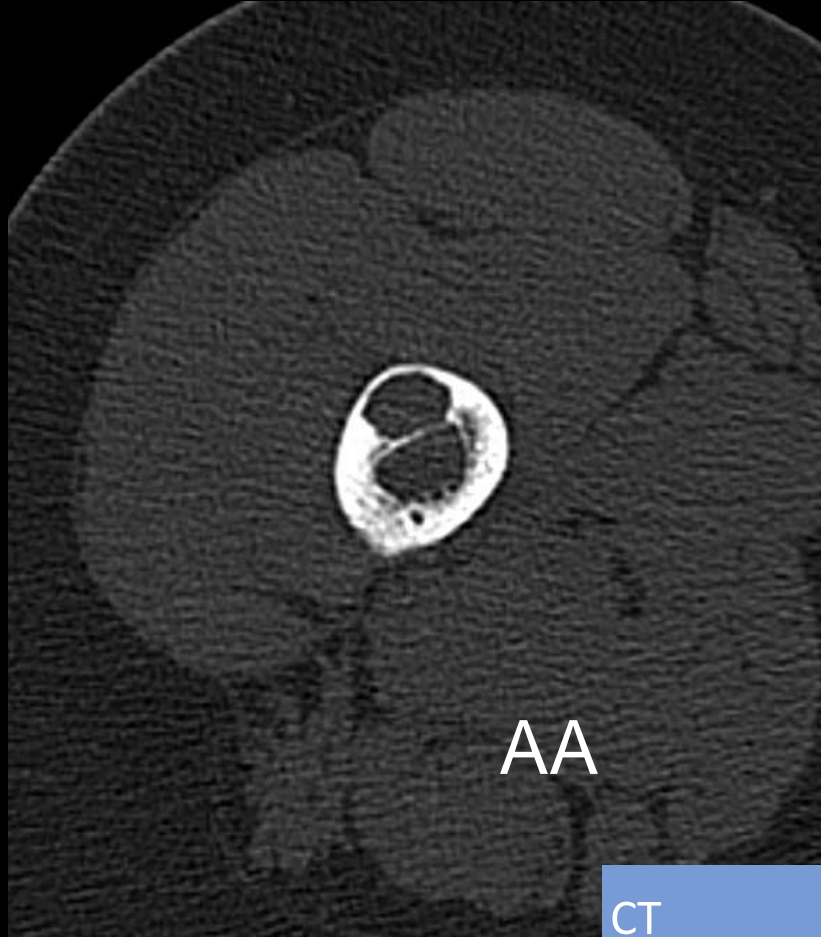


STIR Coronal



T2





- **What are the findings?**
- **What further investigation you would suggest?**
- **What is your diagnosis?**