

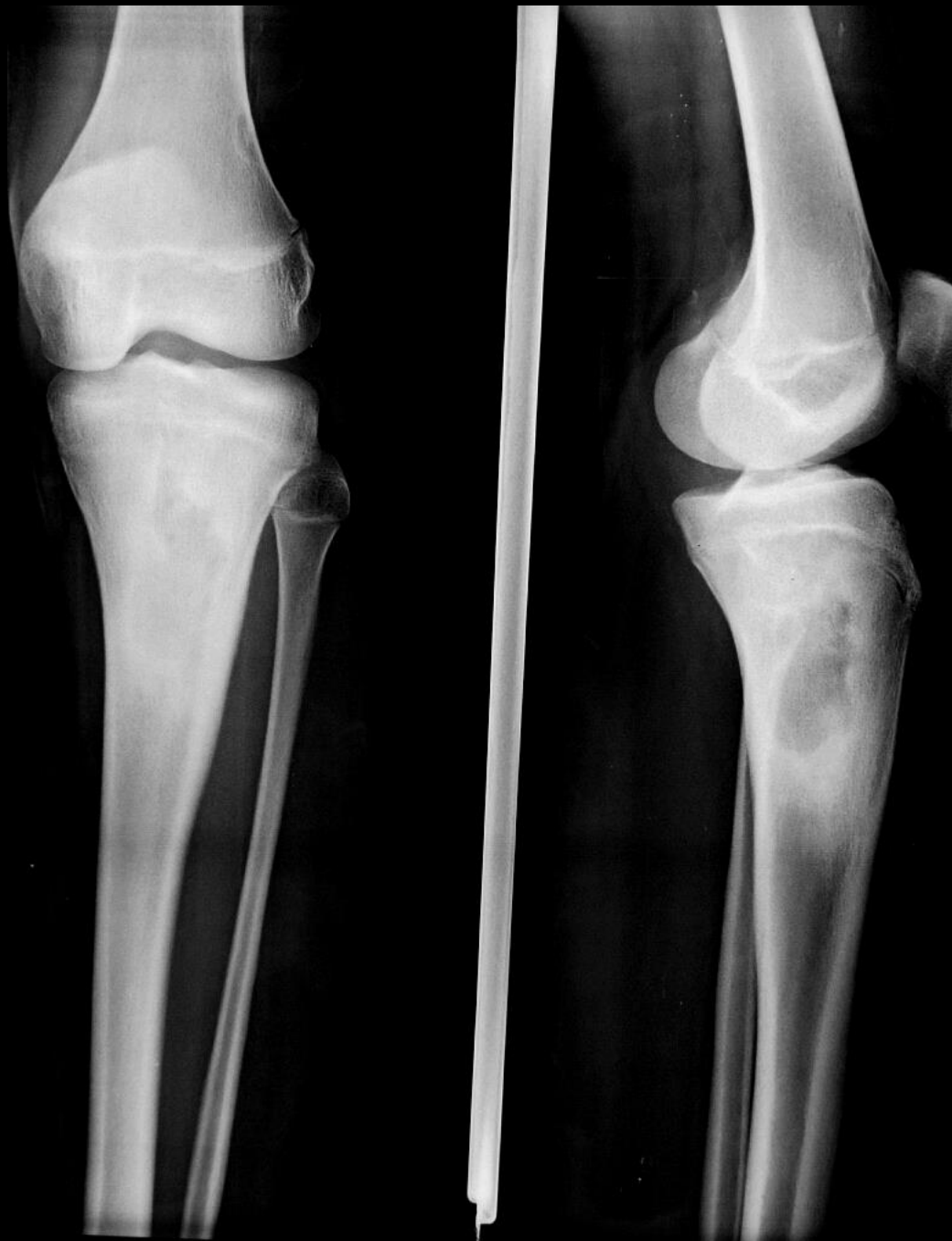
**MICOD - 31/01/2024**

**Case contributor – Dr. Vijinder Arora**

# MI-COD

MSS INDIA- Case Of the Day





CASE 5  
17 yrs old boy  
with h/o pain in  
leg for last two  
months