

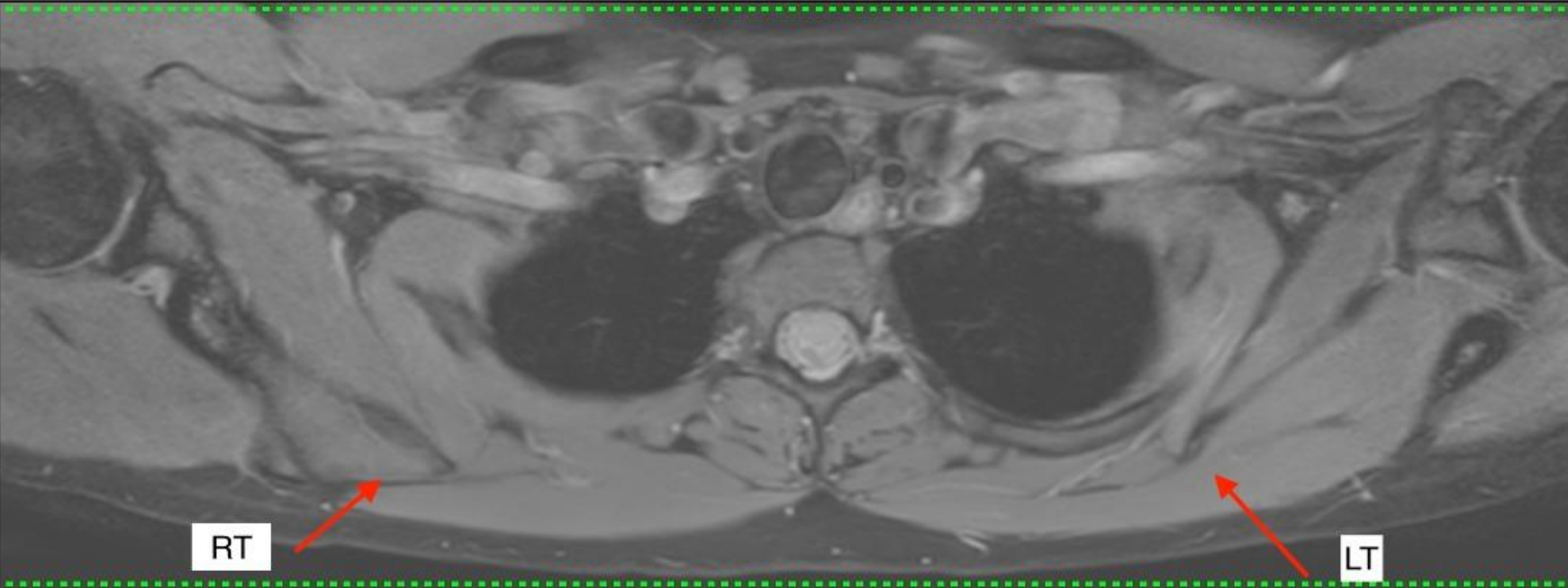
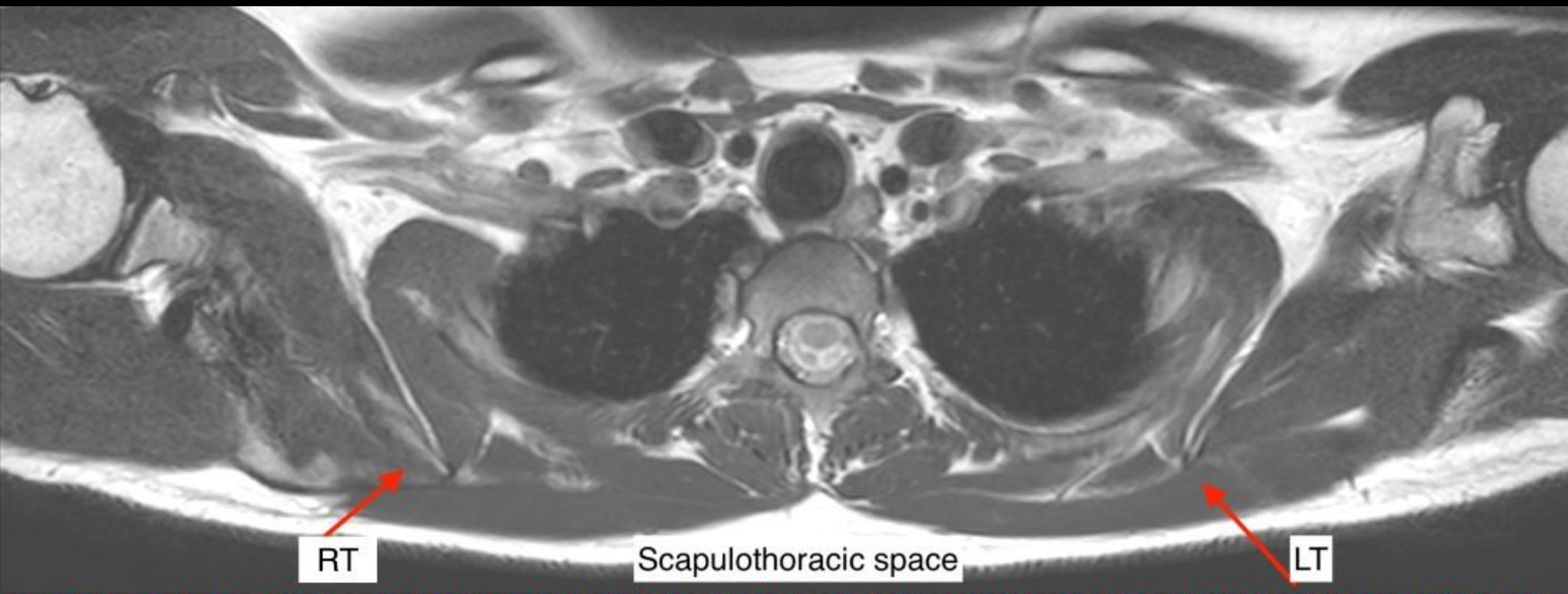
MICOD – 17/01/2024

Case contributor – Dr.Khushboo Pilonia

MI-COD

MSS INDIA- Case Of the Day





22 Year old male with left shoulder blade pain.