

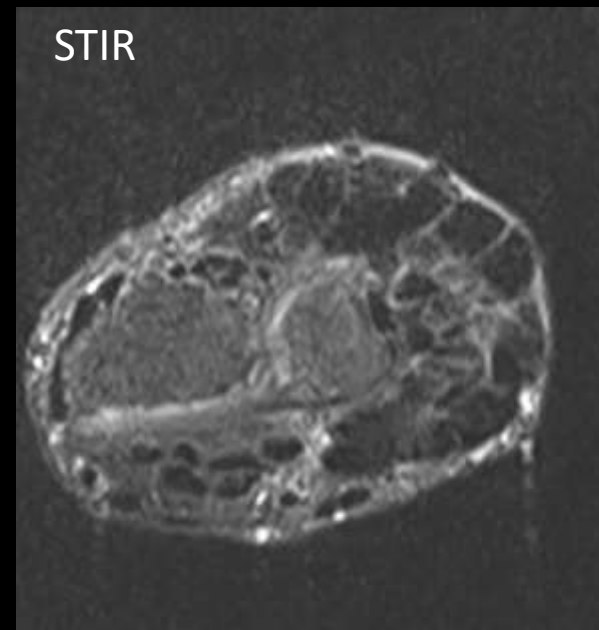
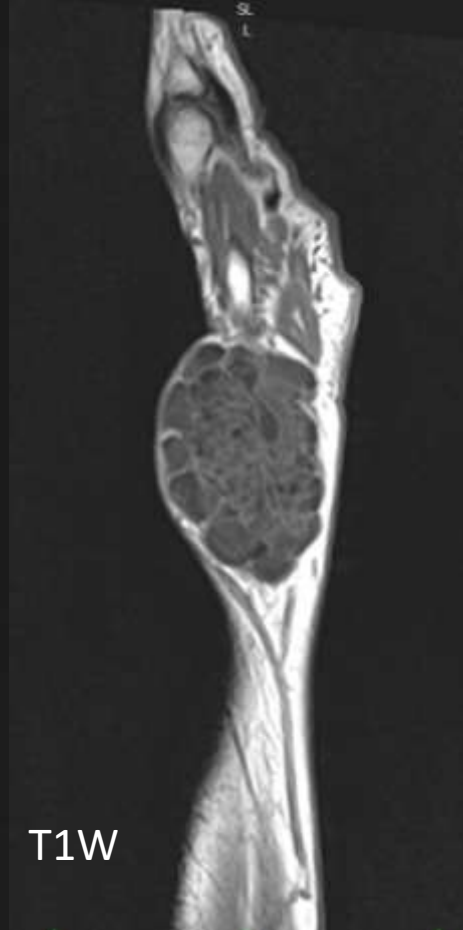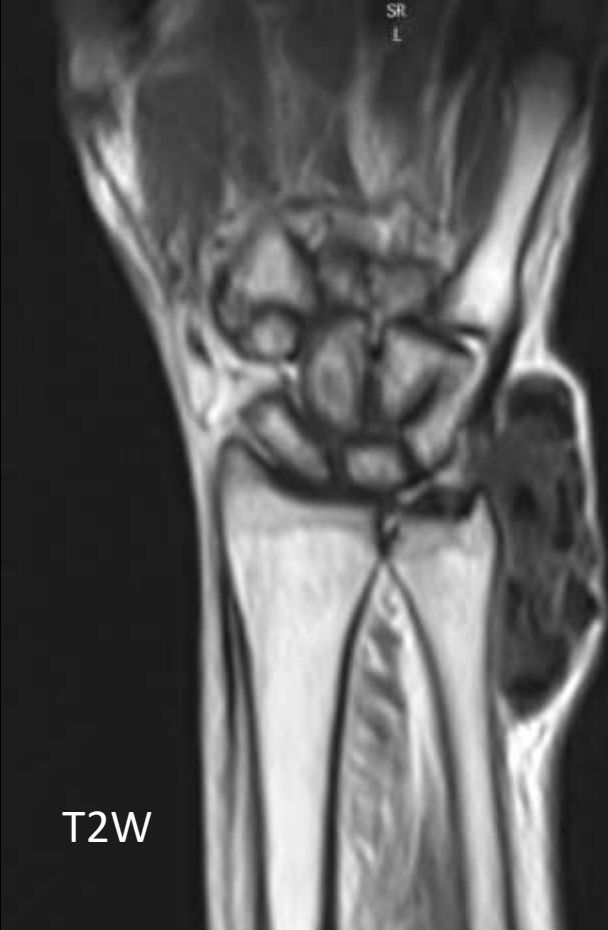
MICOD – 05/01/2024

Case contributor – Dr. Ankur Shah

MI-COD

MSS INDIA- Case Of the Day





55 year male with swelling
No history of trauma
No family history of similar complaint
Patient is on Dialysis for Renal failure