

MICOD – 04/01/2024

Case contributor – Dr. Shayeri Roy Choudhury

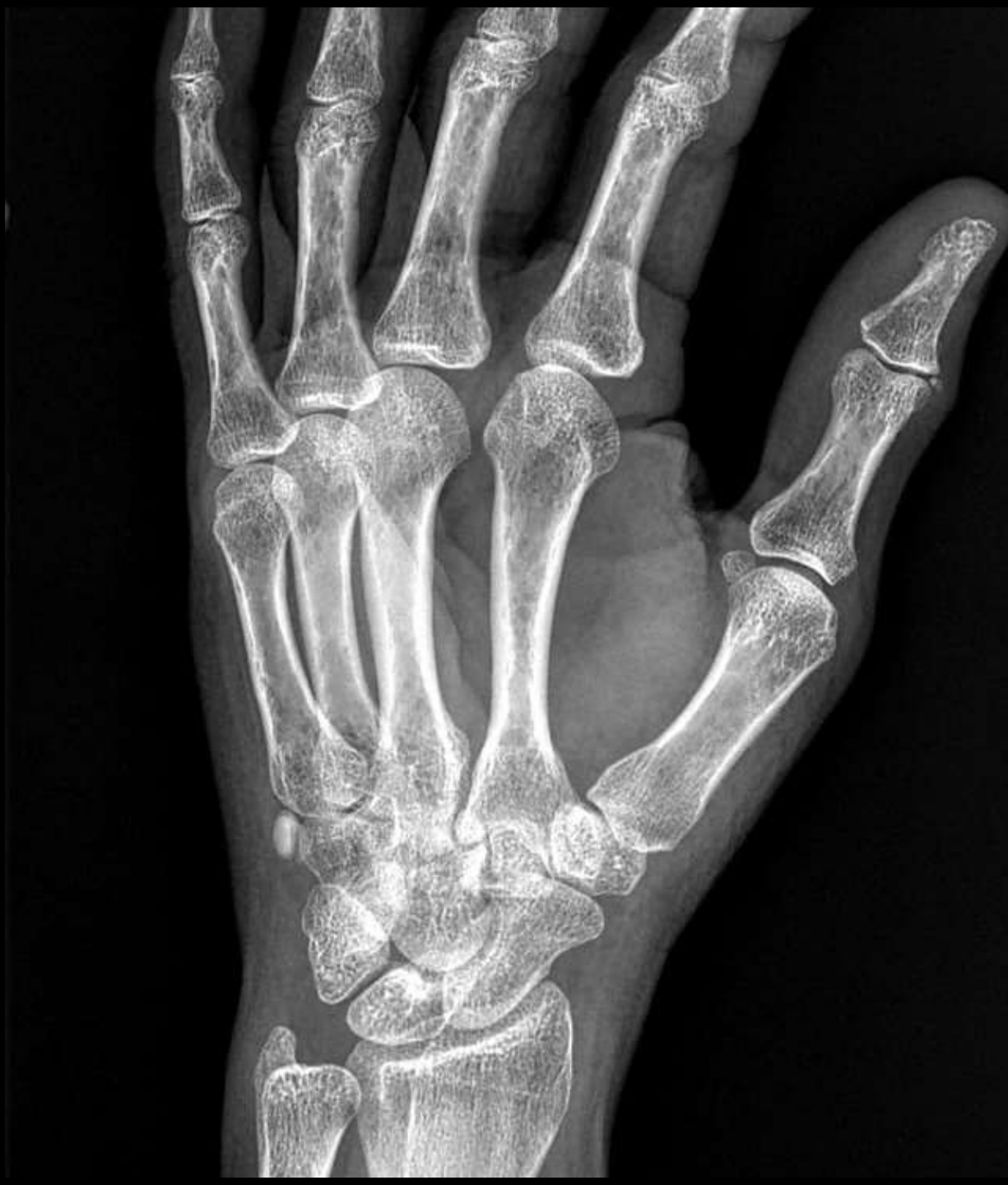# MI-COD

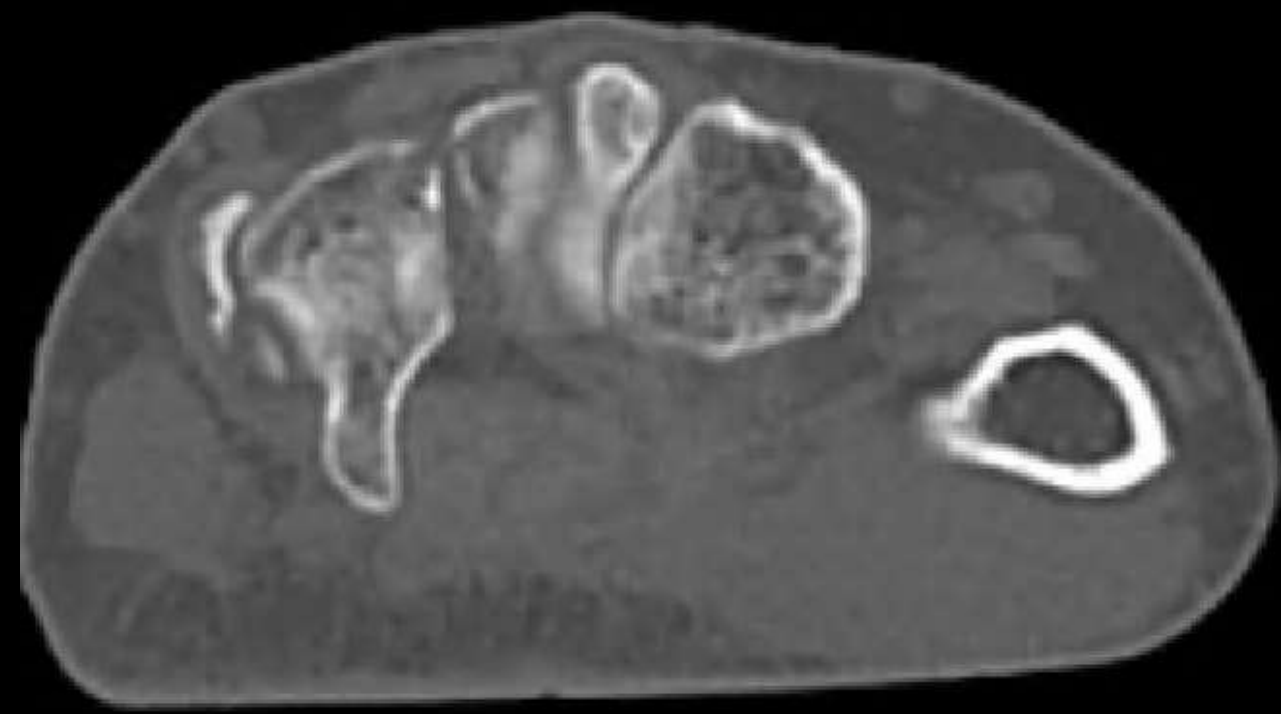
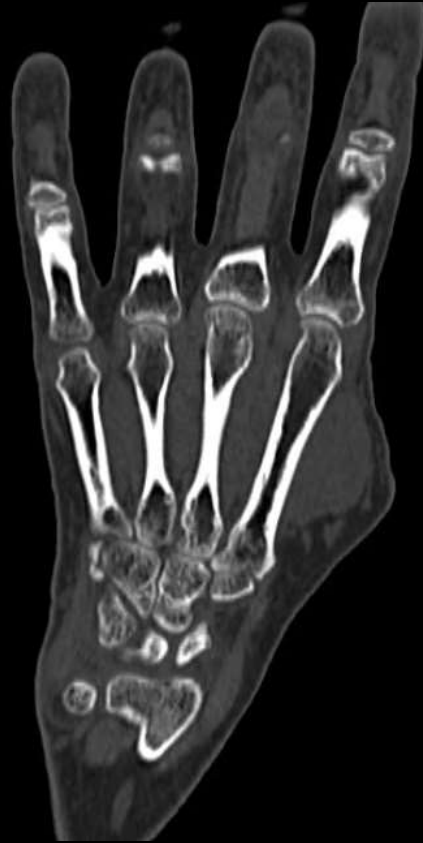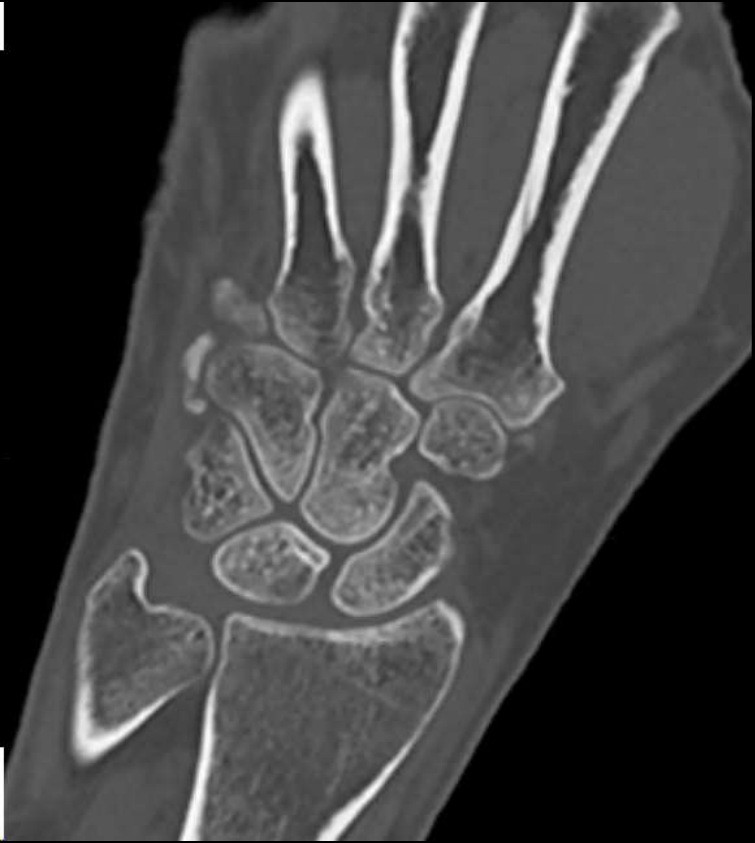MSS INDIA- Case Of the Day



# CLINICAL HISTORY

- 50 y/female
- 1 month history of pain along the ulnar aspect of palm
- No history of trauma





What is the diagnosis?