


**MICOD 27.12.2023**  
**Contributor - Dr. Abhimanyu Kelkar**

**MI-COD**

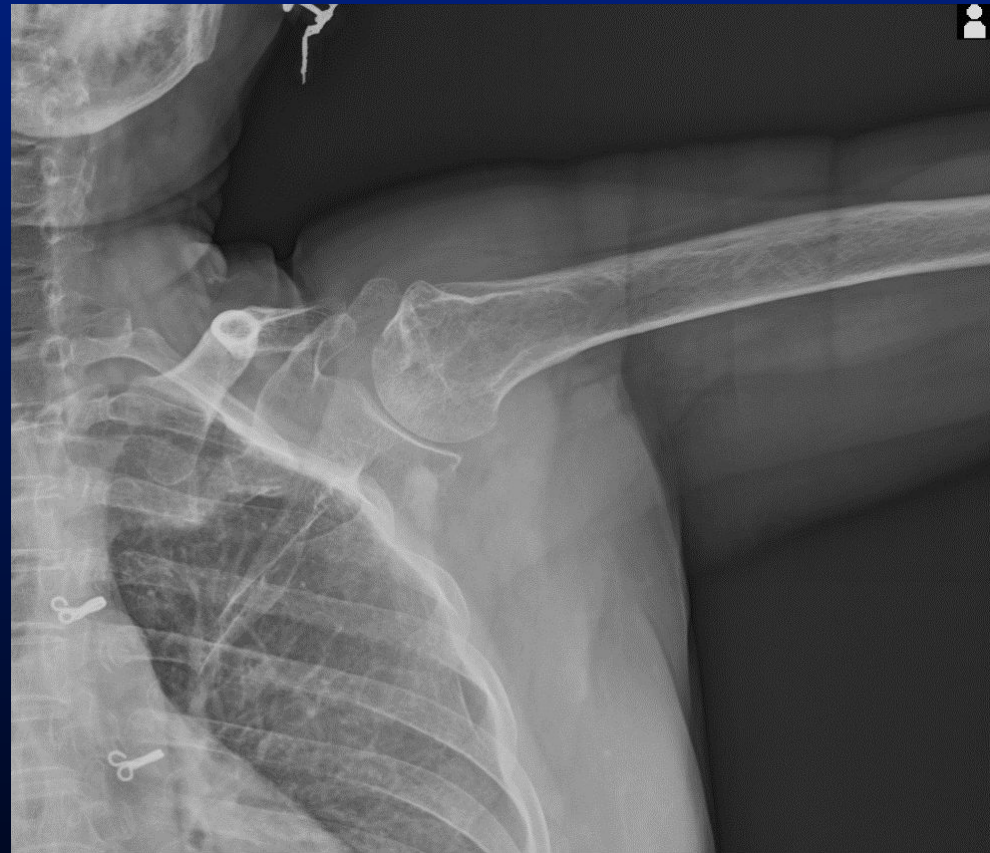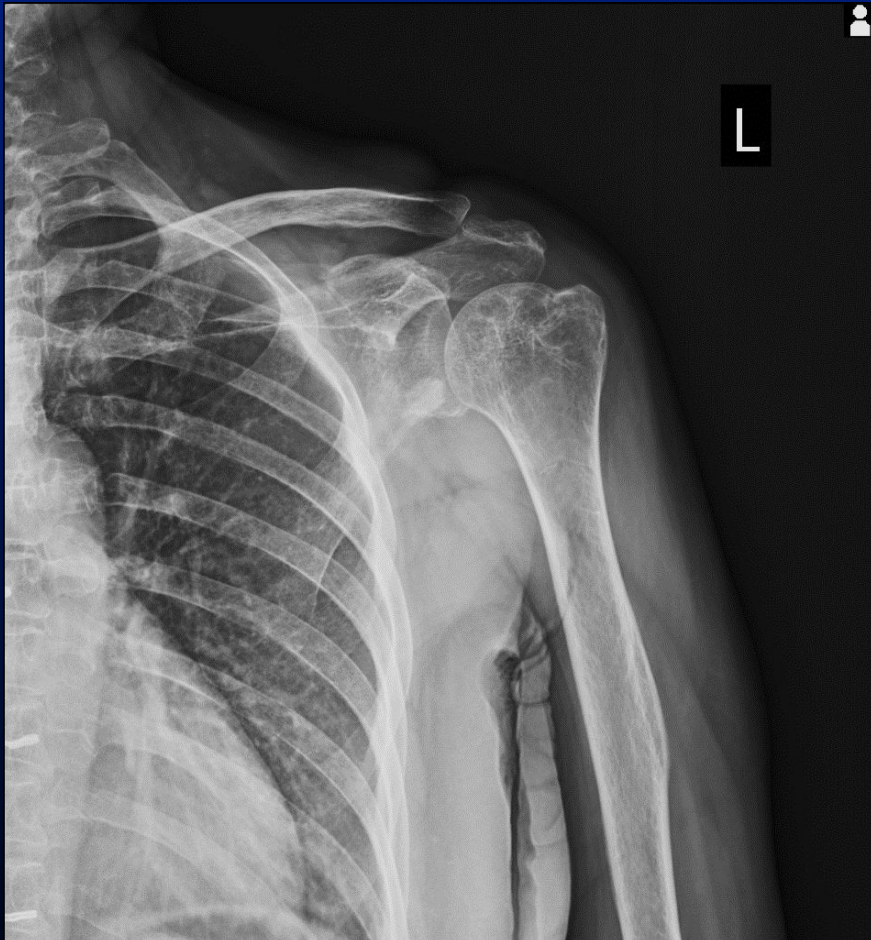
MSS INDIA- Case Of the Day



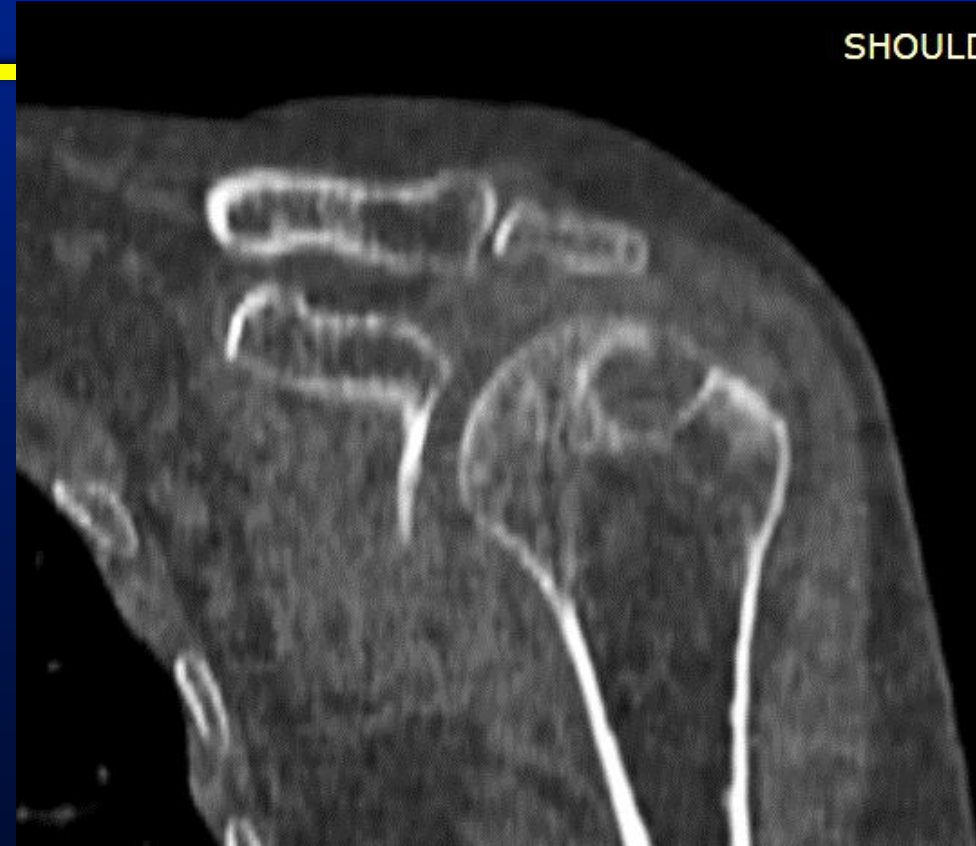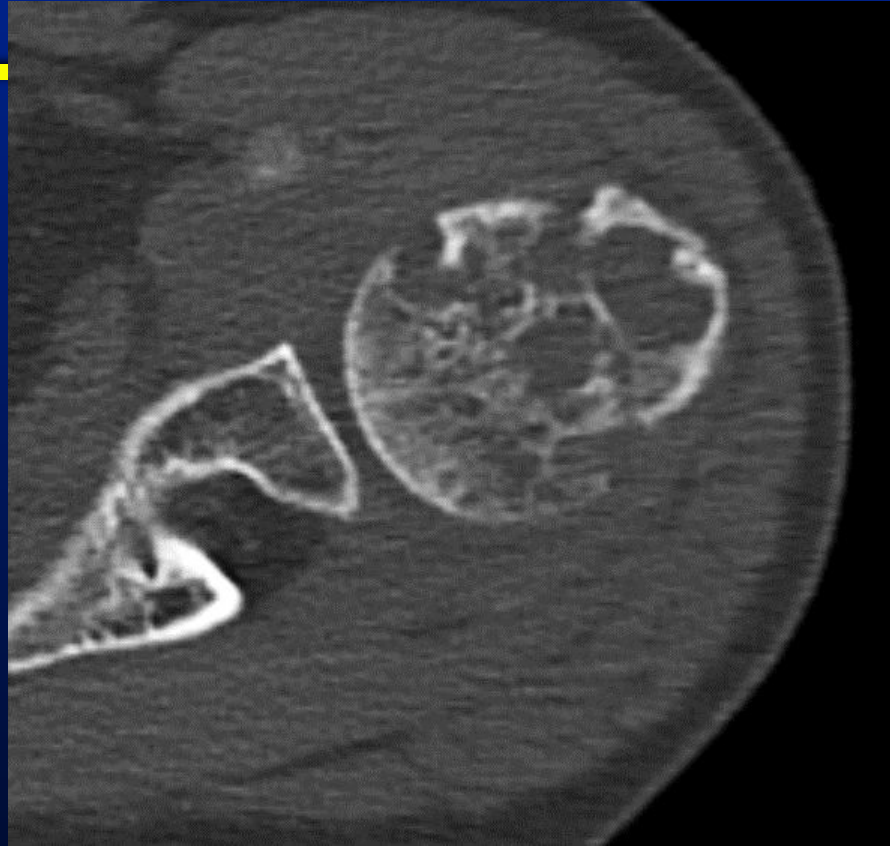---

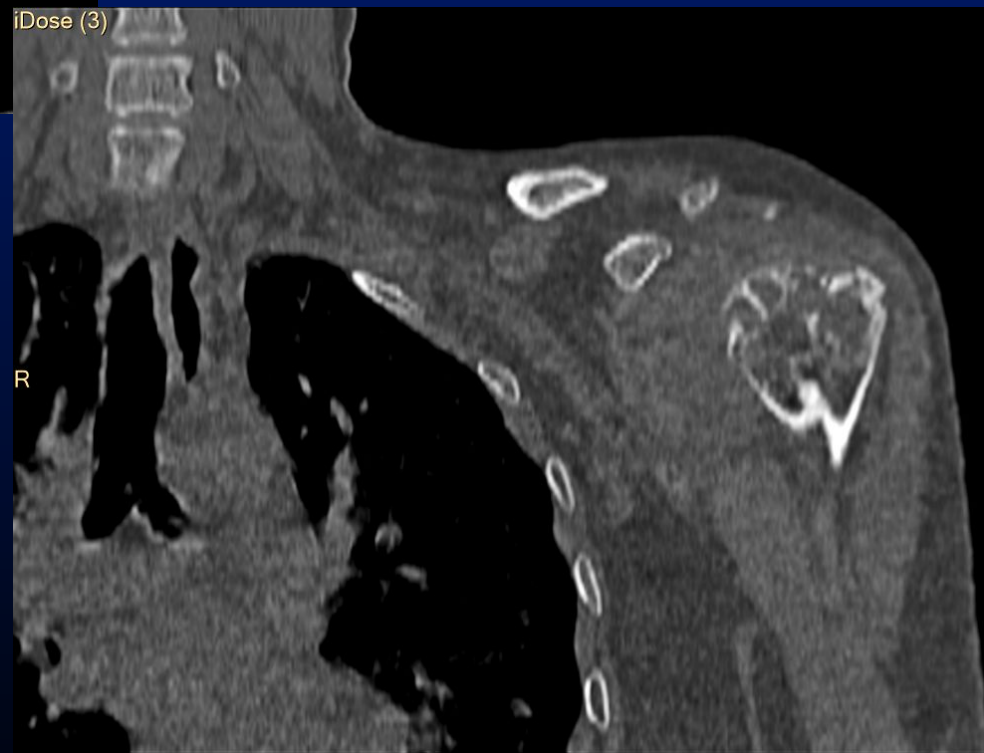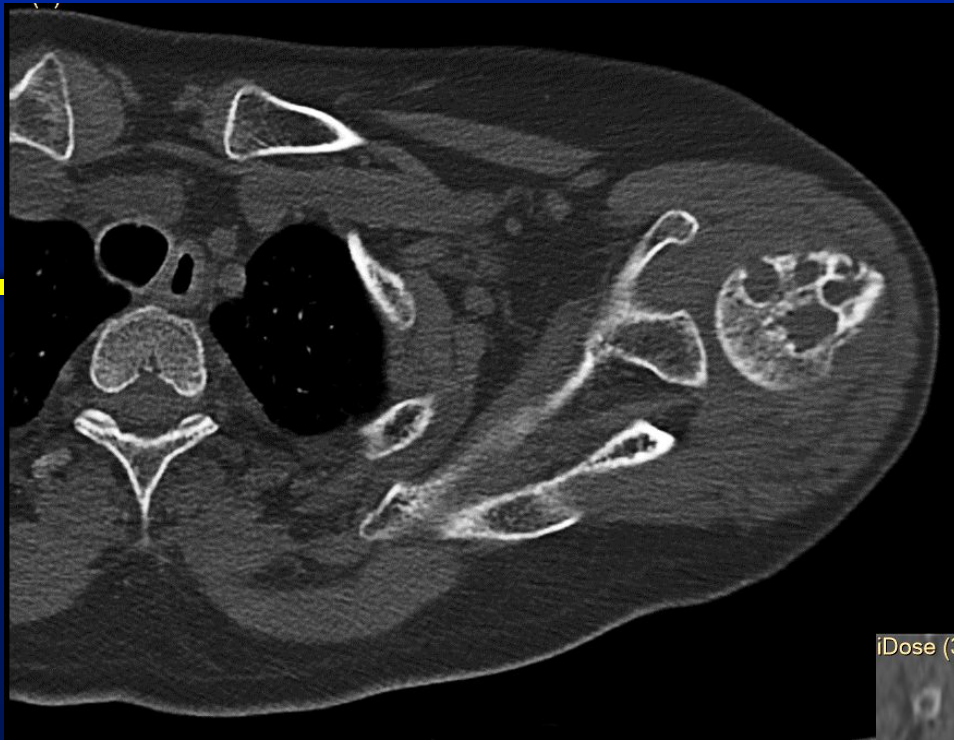58 yr old lady, shoulder pain and  
restriction of movements  
Clinically, Adhesive capsulitis

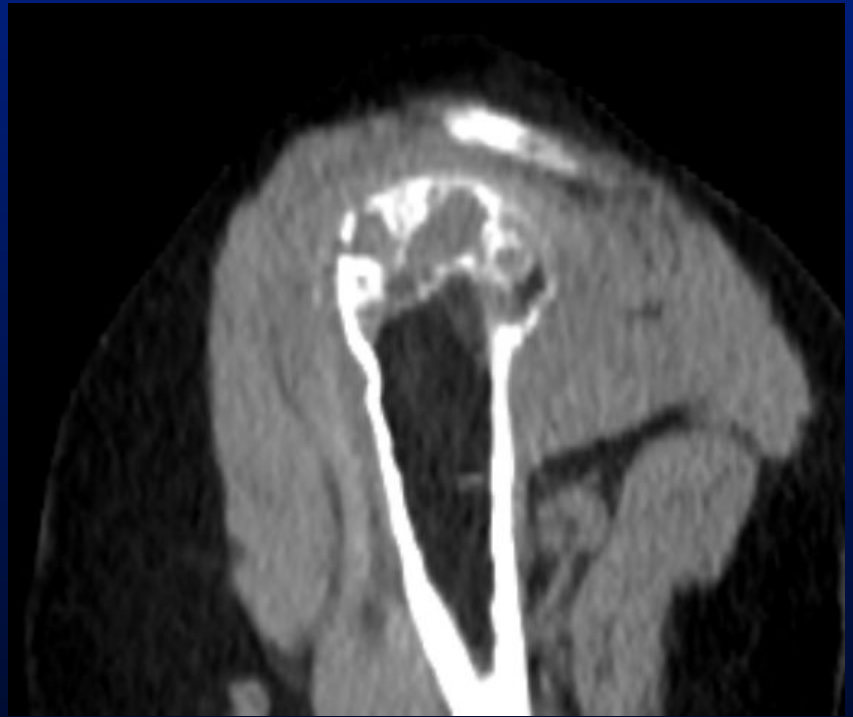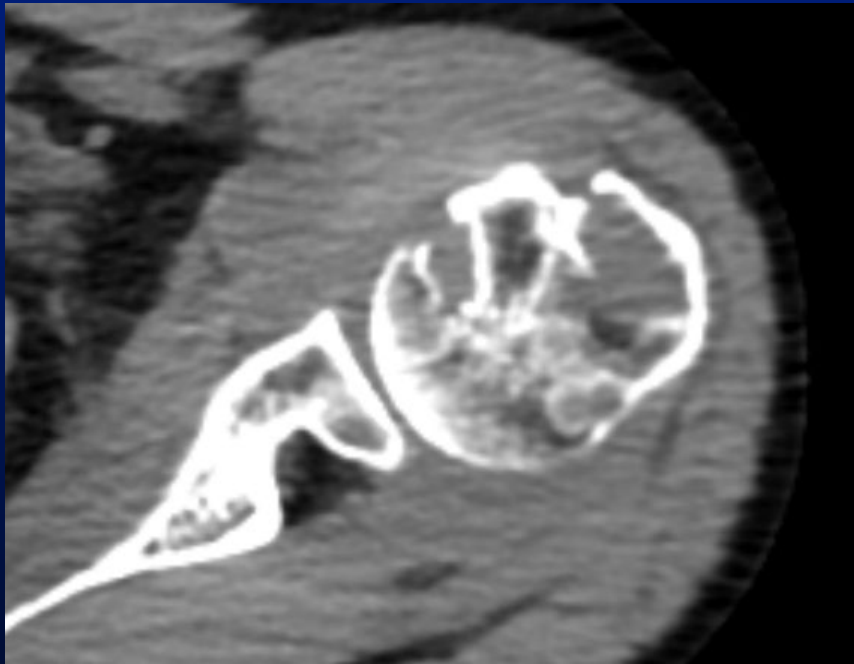
# Multiple lytic lesions in humeral head



# CT



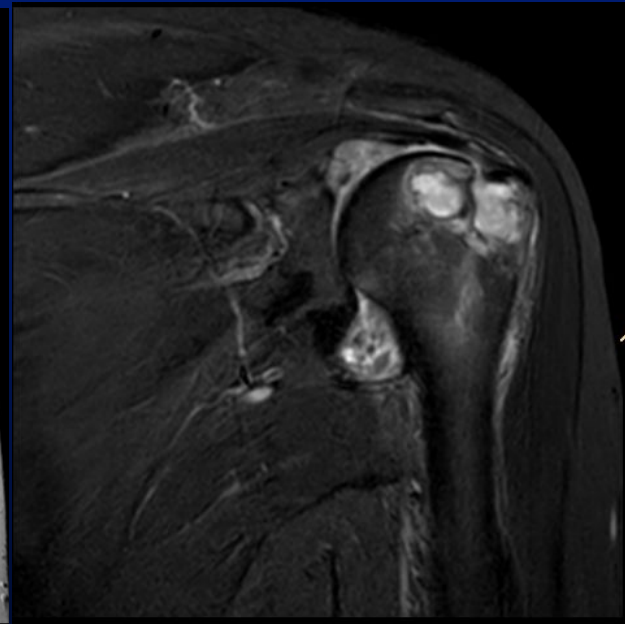
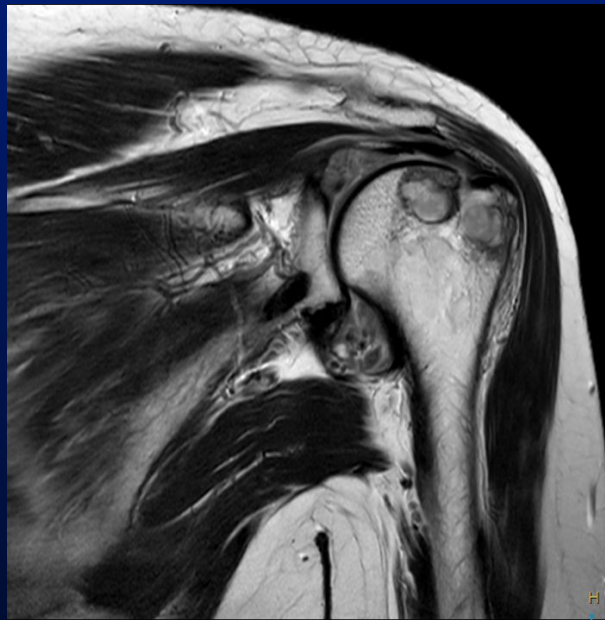
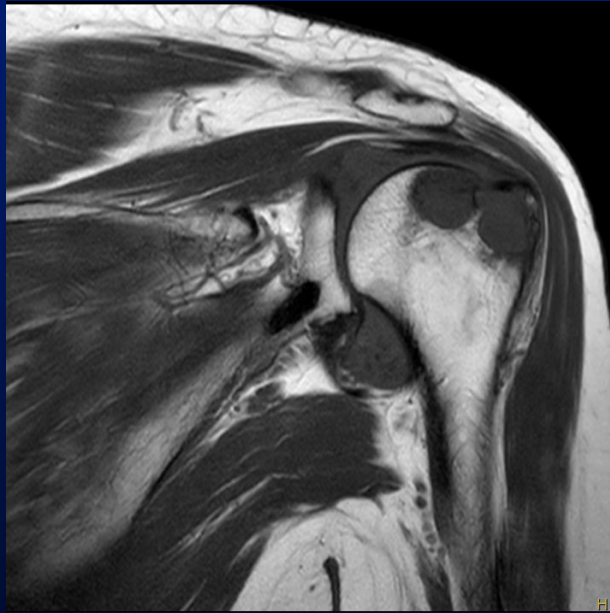


- 
- ❖ At this stage we can ask differentials and then show MRI pre and post contrast
  - ❖ We can also ask whether MRI would give additional information.

# T1, T2, STIR

---





---

What are your differentials now?

# Post Gad

