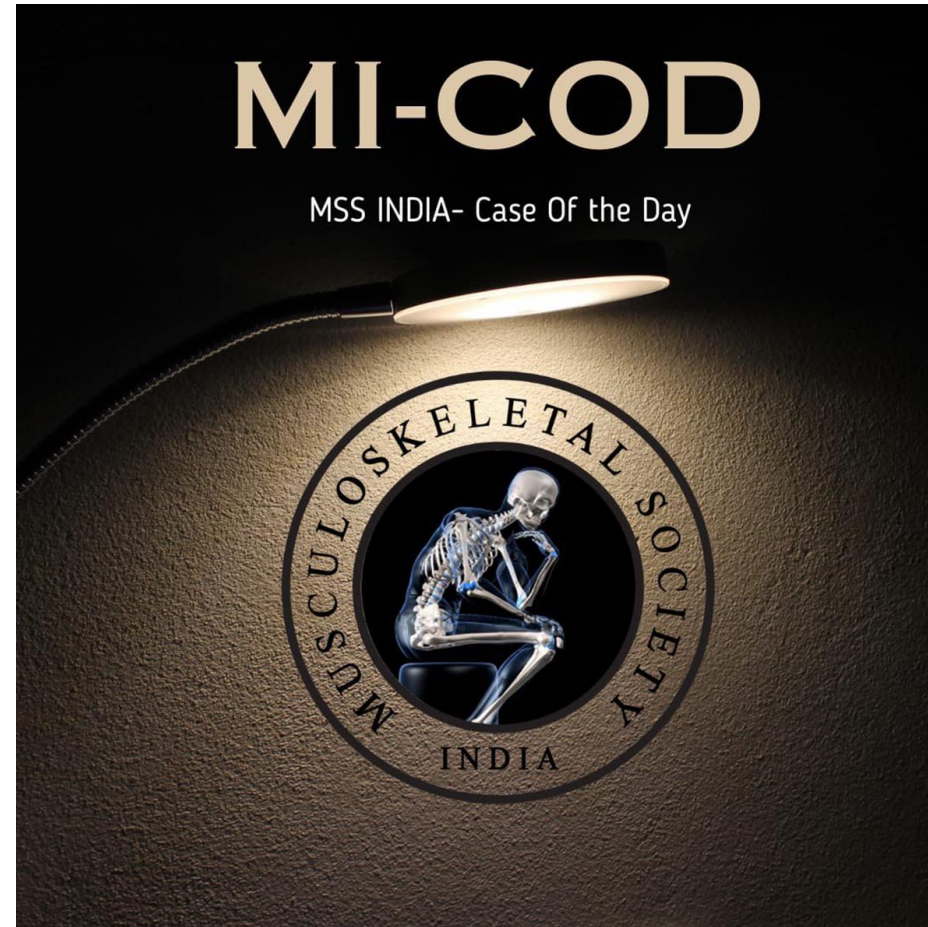


MICOD – 25.12.2023

Case contributor – Dr. Harun Gupta



35 yr M hip pain

