

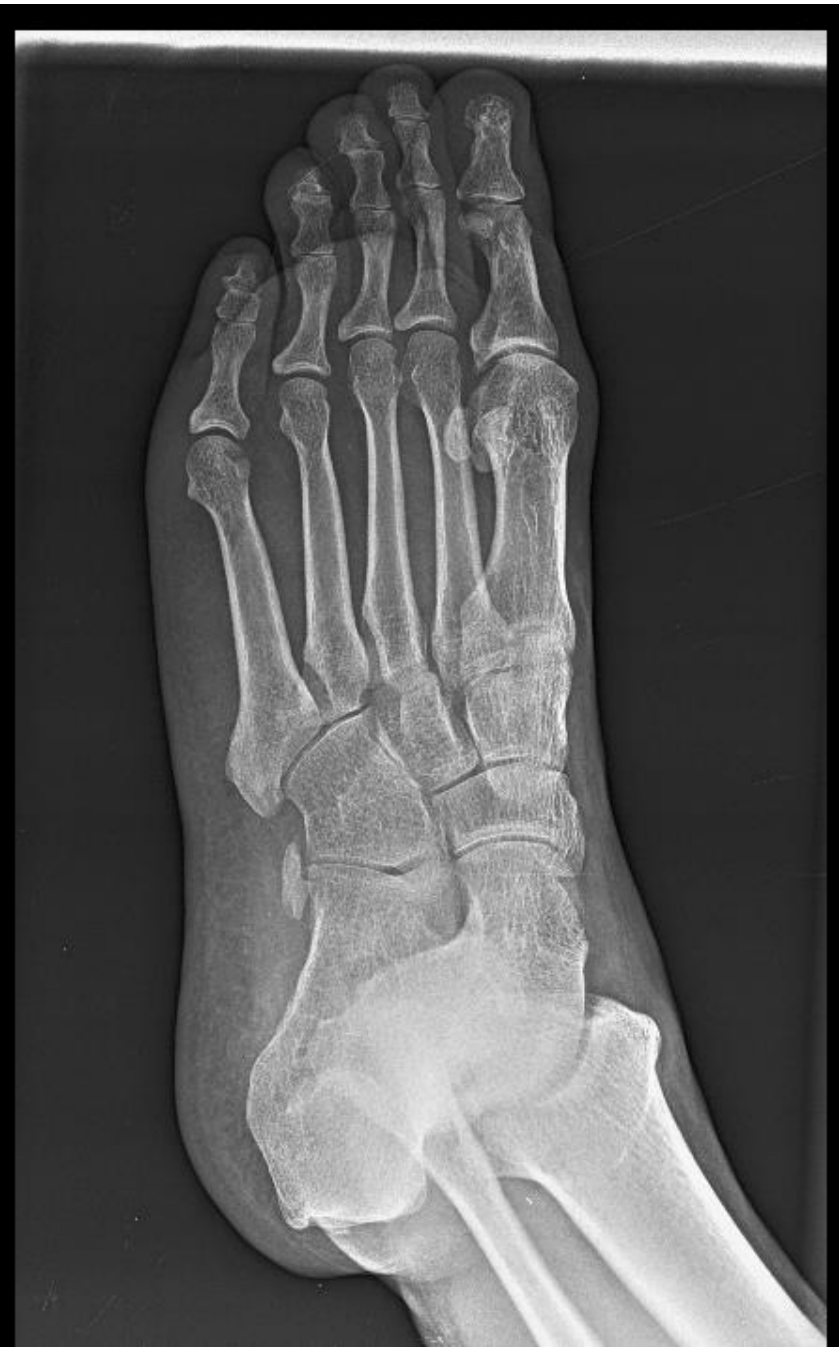
MICOD – 22.12.2023
Case contributor – Dr. Vikas Batra

MI-COD

MSS INDIA- Case Of the Day



A 40 years old male patient presenting with c/o pain in lateral aspect of right foot for past 3-4 months. No obvious history of trauma.



AP oblique radiograph of right foot.

- MR was advised.

