

MI-COD

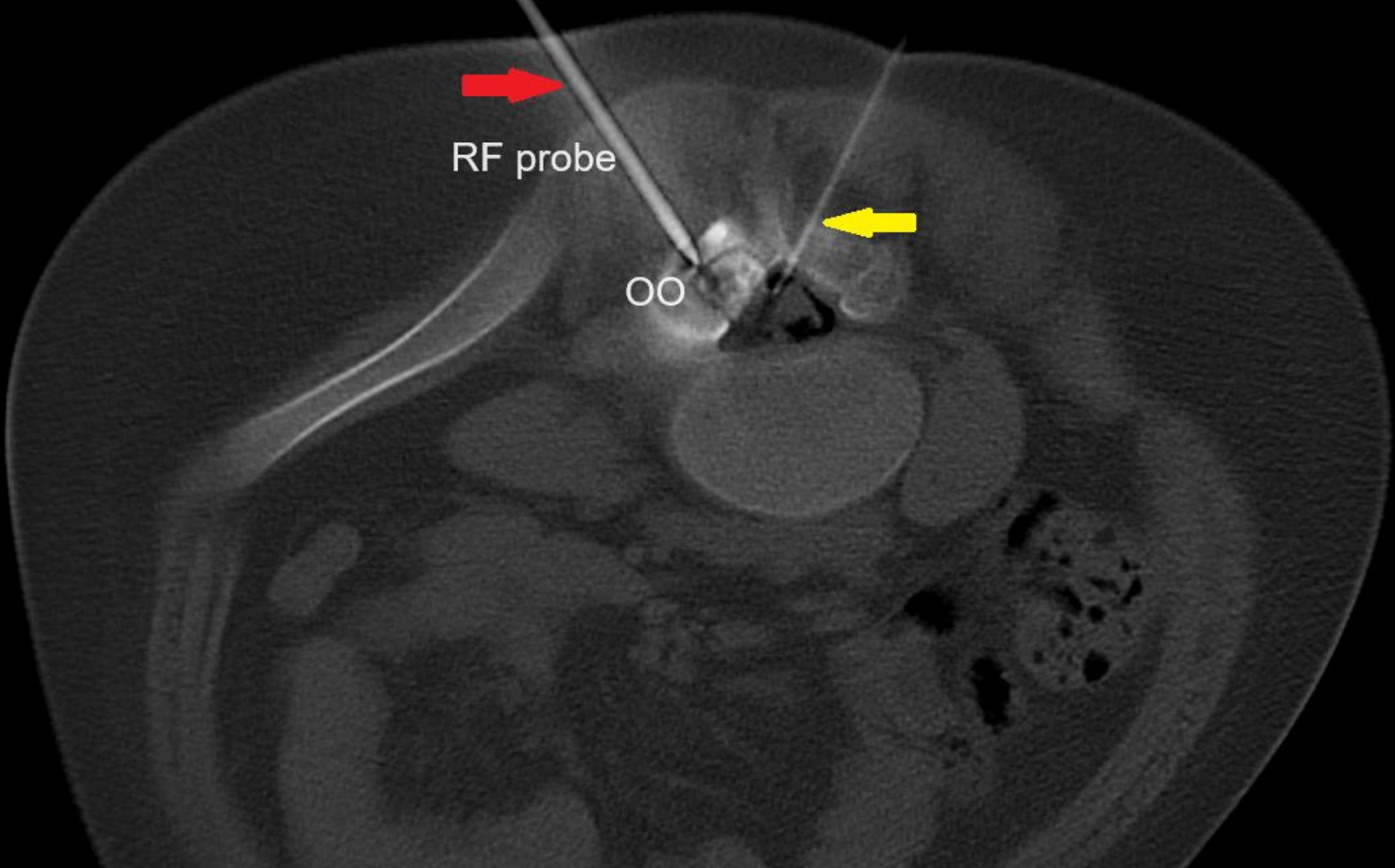
MSS INDIA- Case Of the Day



Contributor: Dr. D. K. Singh

**14 year young male with painful scoliosis. Radiofrequency ablation of osteoid -
osteoma at posterior element spine was performed.**

P



RF probe

OO