

MICOD – 06/12/2023

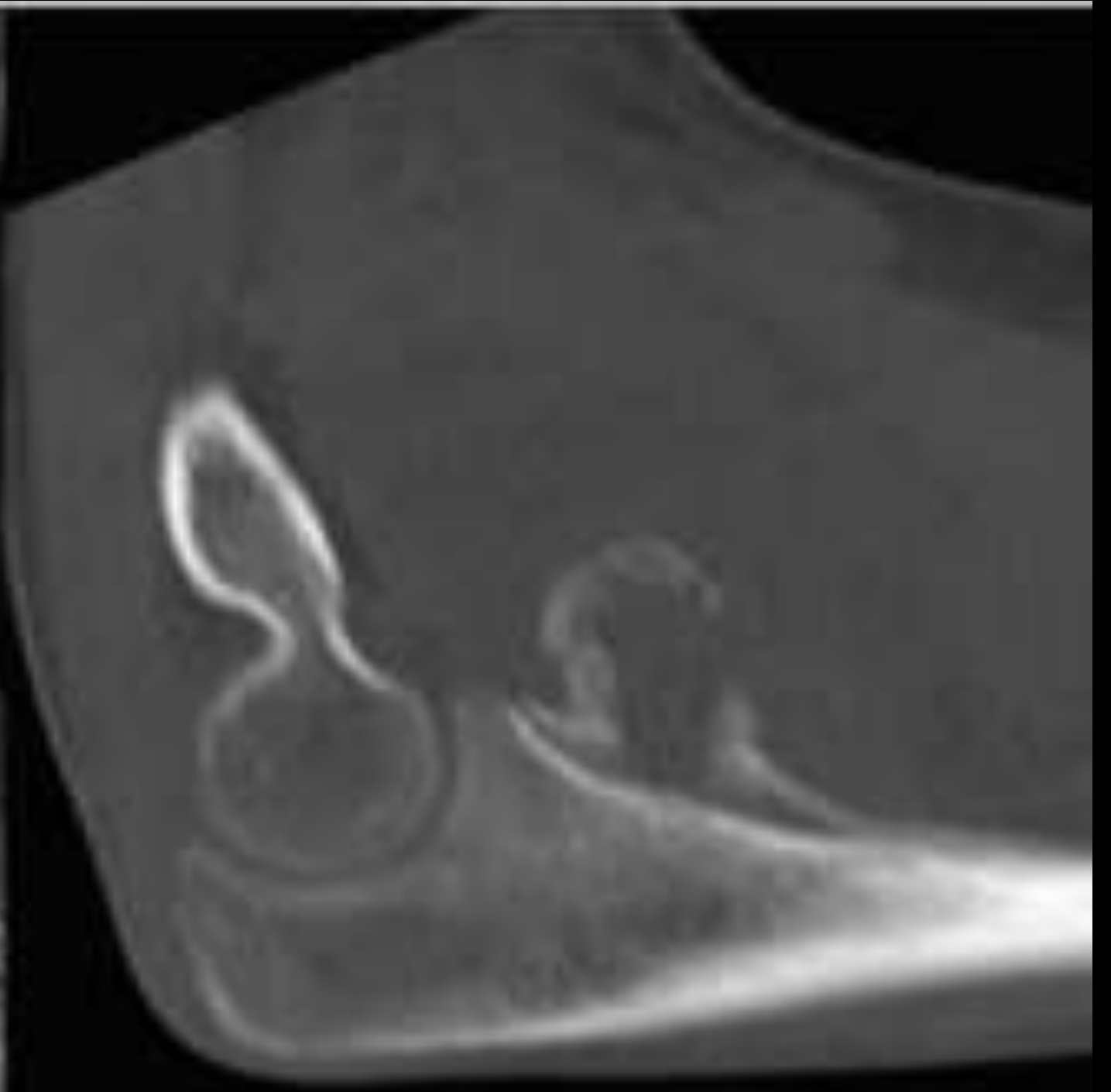
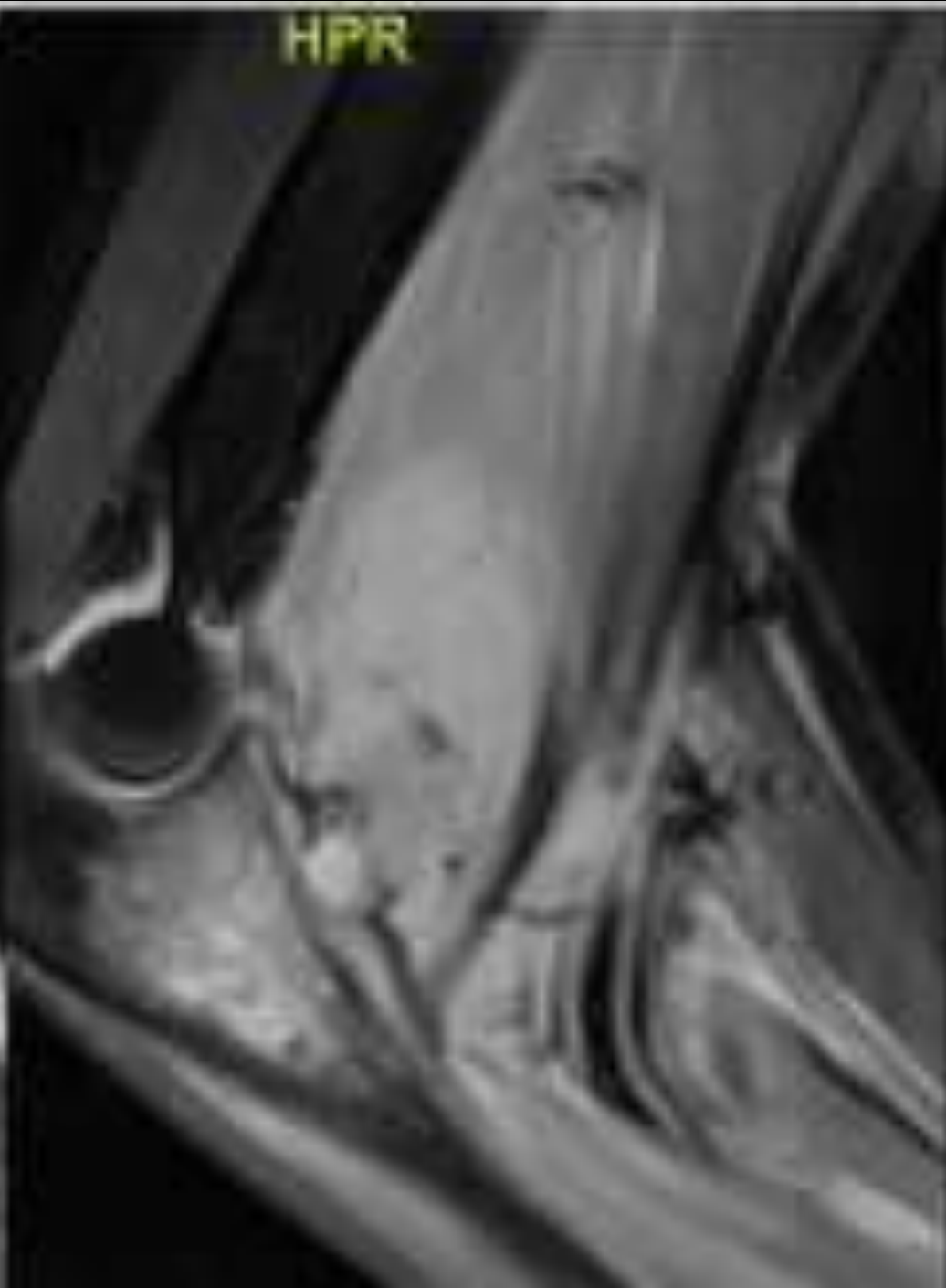
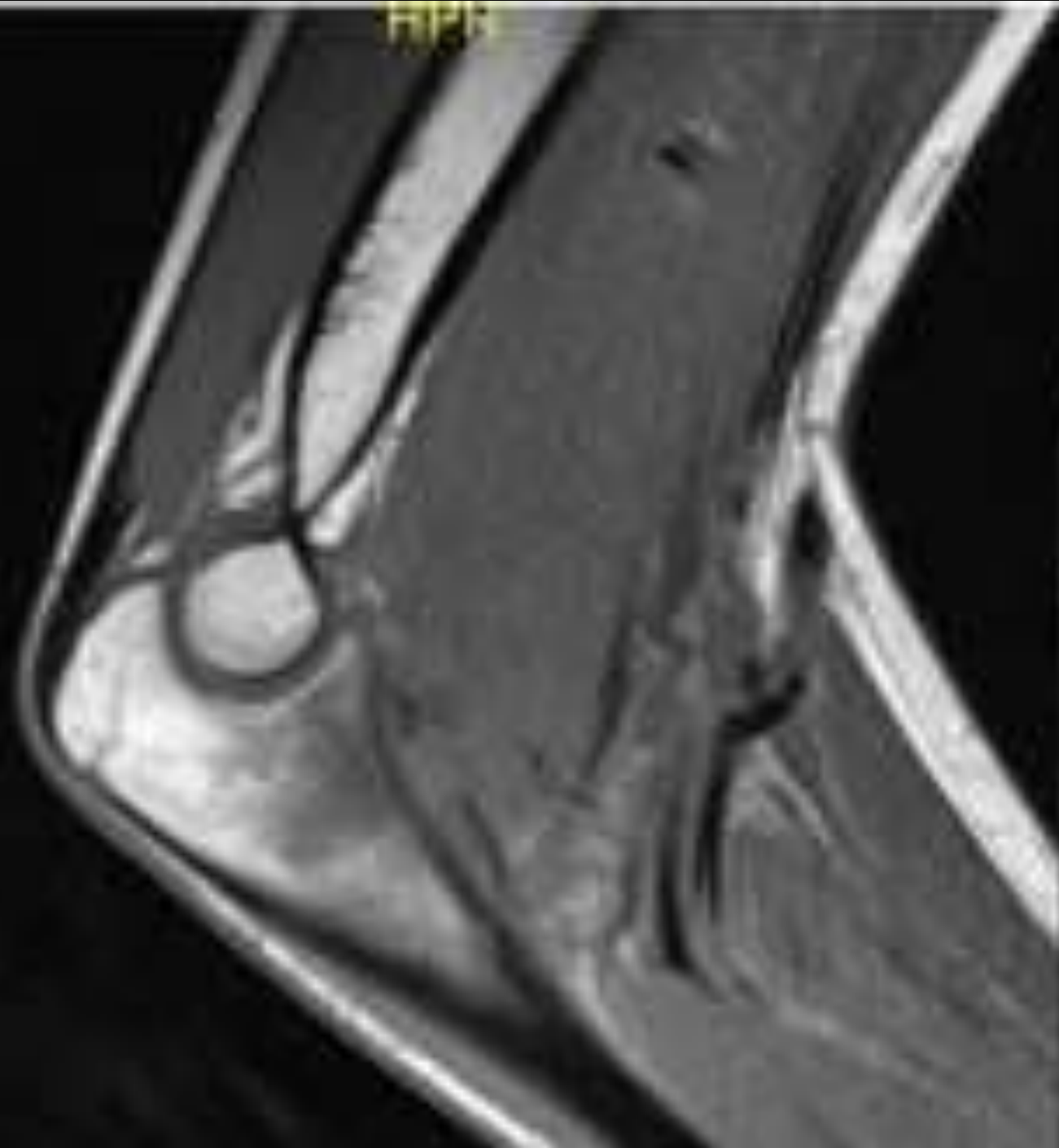
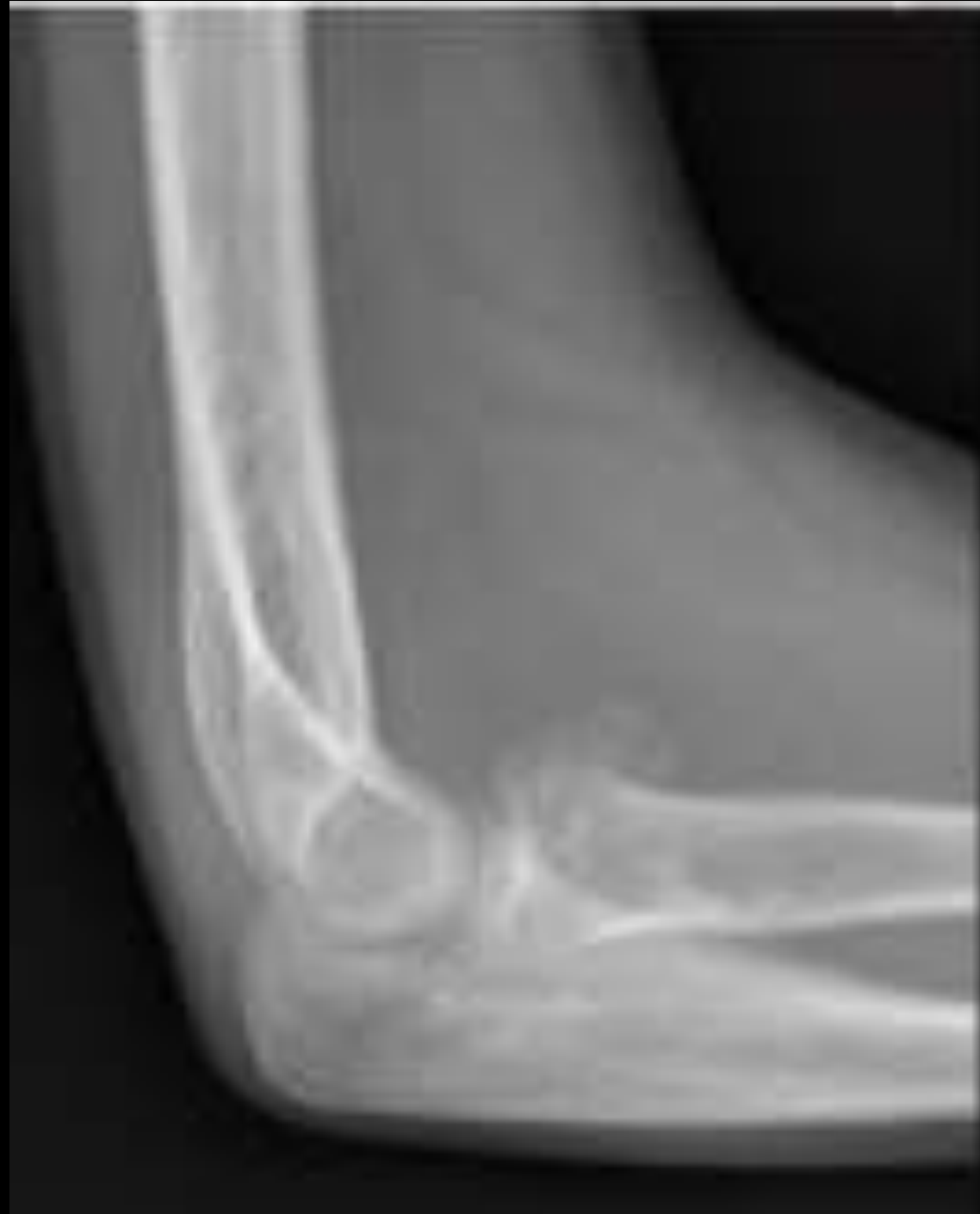Case contributor – Dr. Rajesh Botchu

# MI-COD

MSS INDIA- Case Of the Day







What are the differentials and the diagnosis?