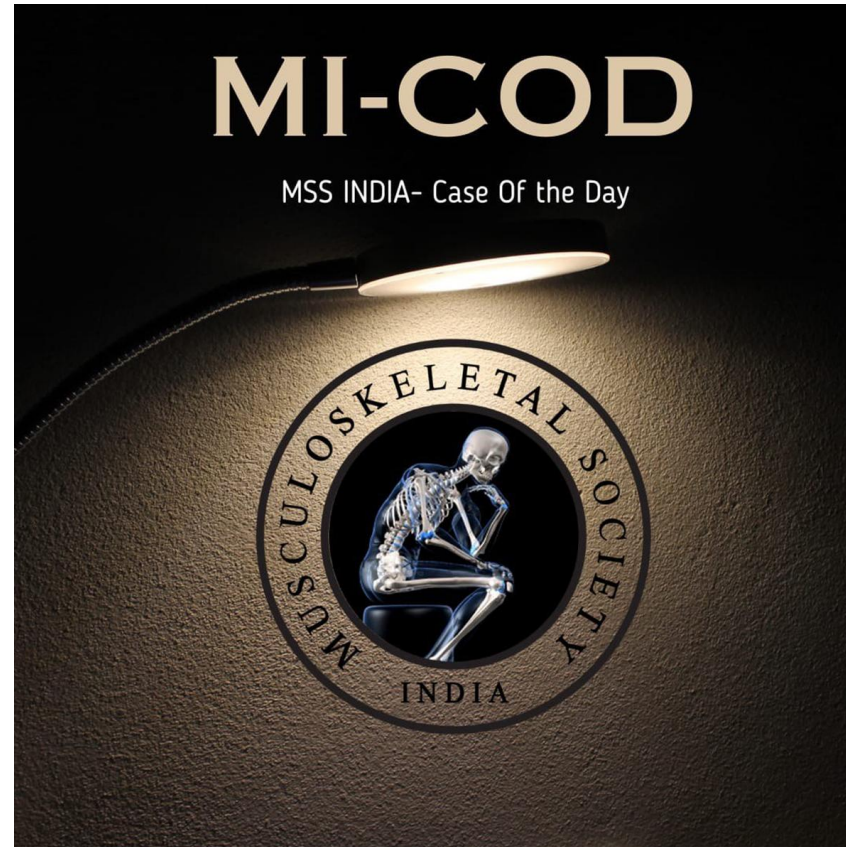


MICOD -29/08/2023

Case contributor – **Dr Amogh VN**

Aster RV hospital

Bengaluru



62 year old male patient with left hip limp.

