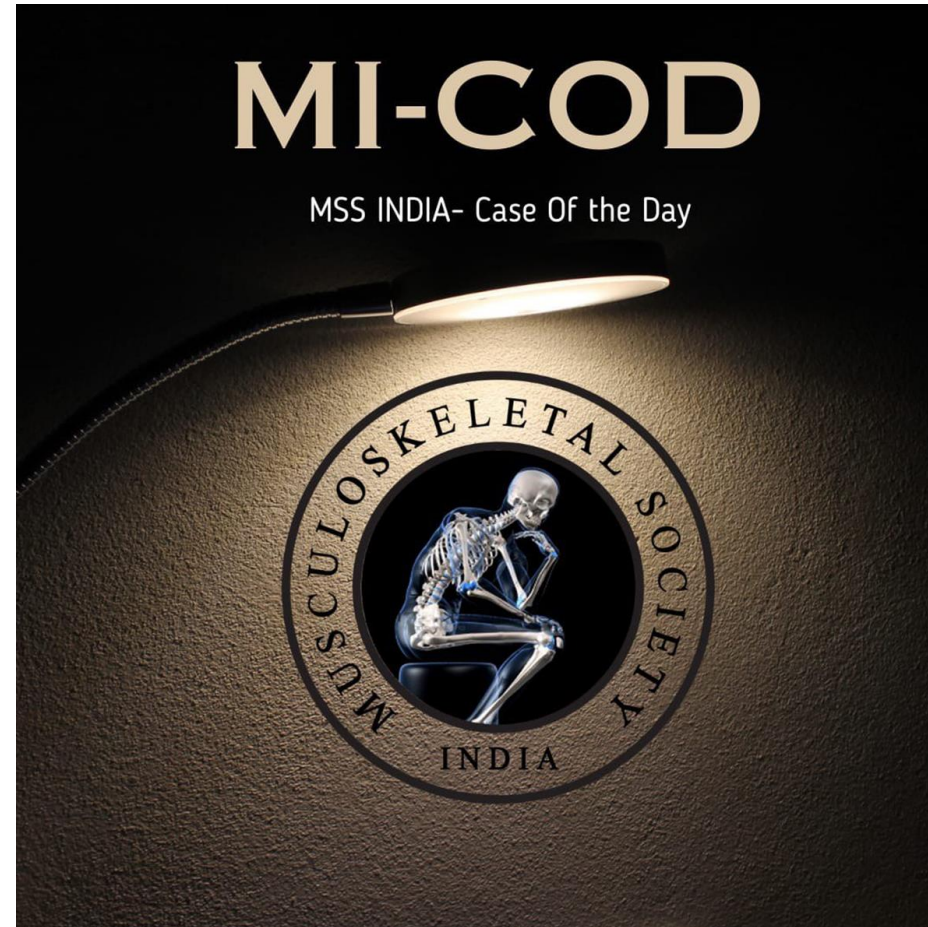


MICOD -28/08/2023

Case contributor – Dr. Harun Gupta

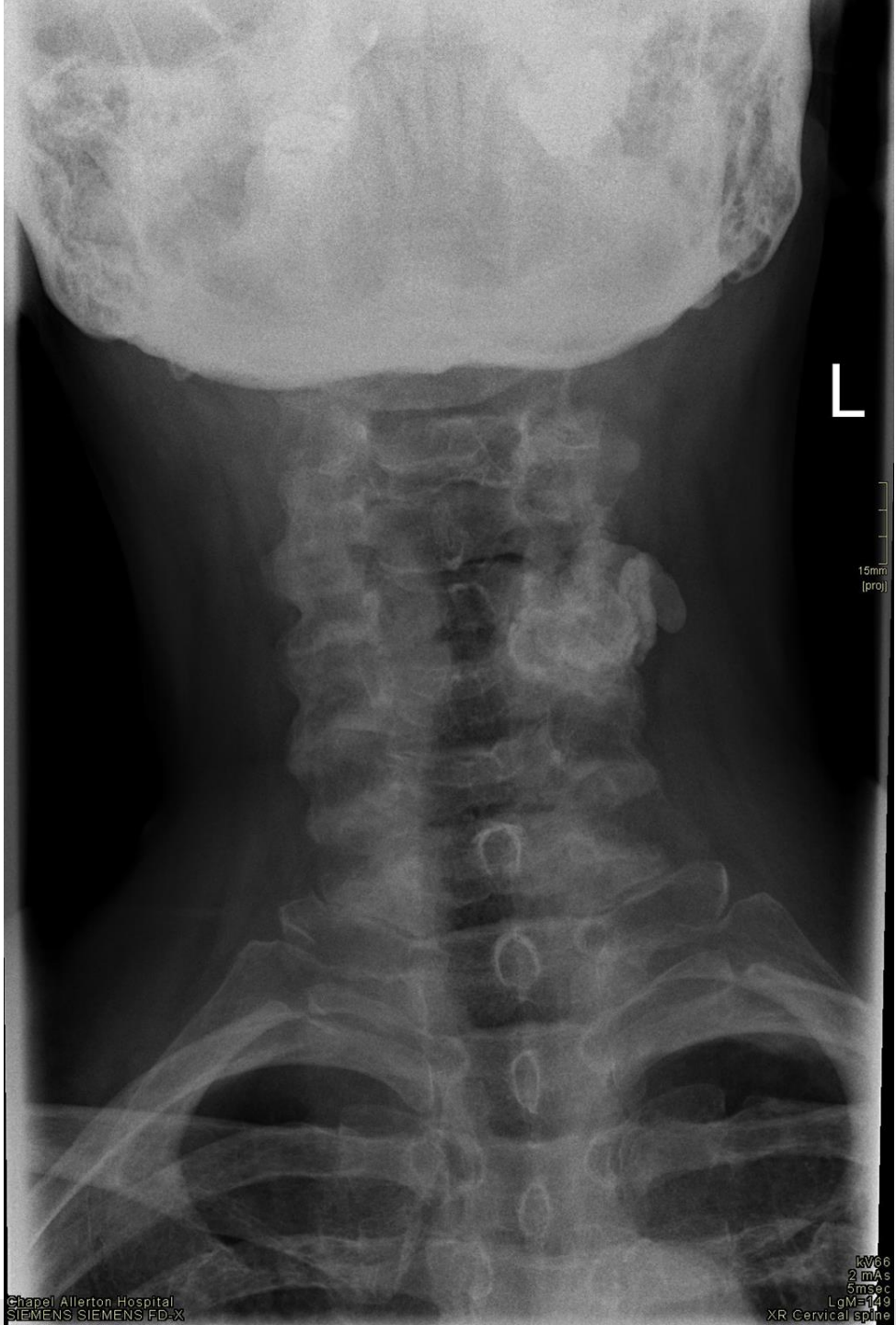
@mskteachingroom



- 68 year old Female
- C/o Neck pain with occipital headache radiating down arm
- ?facet joint involvement

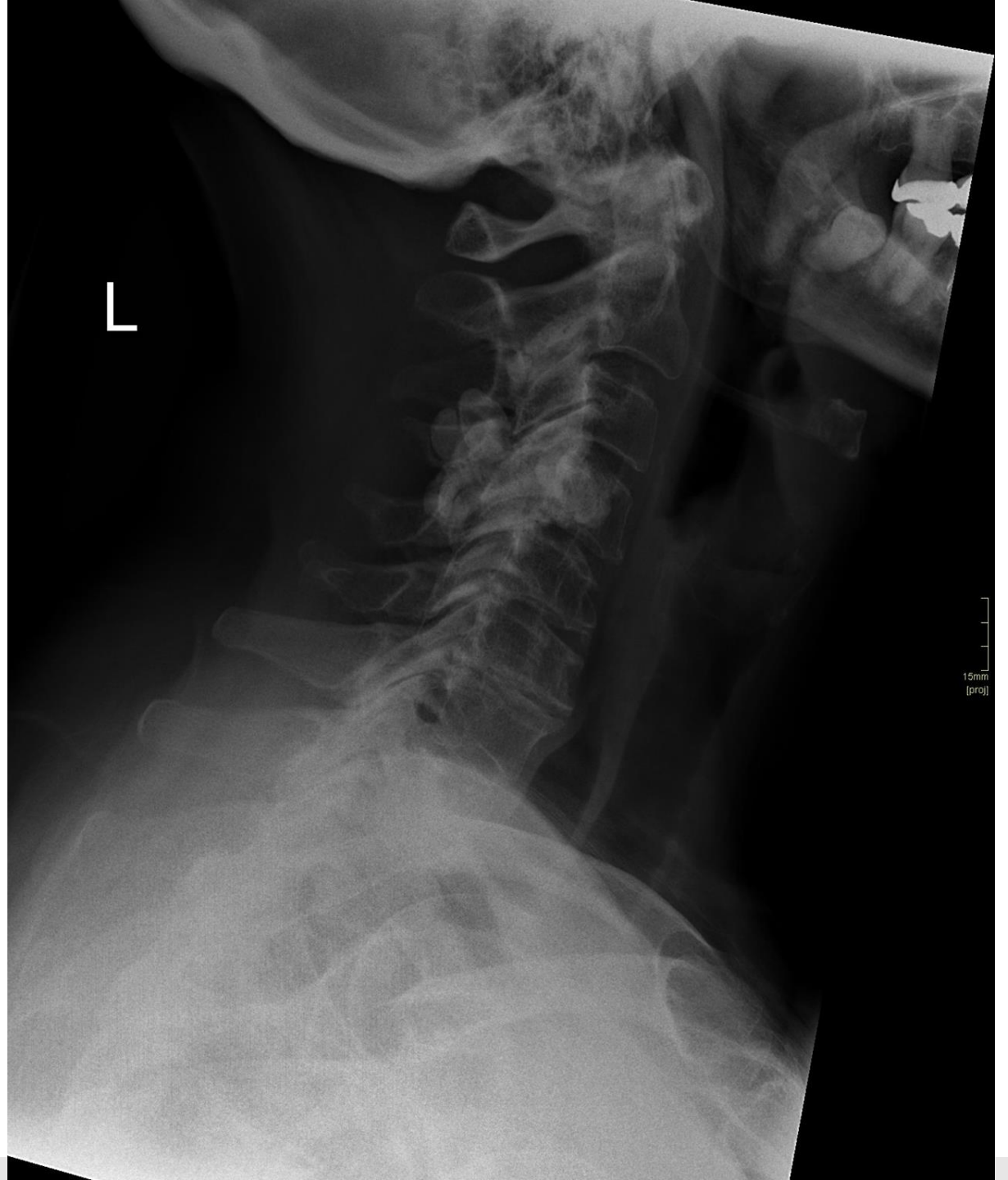
- Link to full DICOM case

<https://www.cmradiology.com/cases/1362929375>



Chapel Allerton Hospital  
SIEMENS SIEMENS FD-X

kV66  
2 mAs  
5 msec  
LgM=149  
XR Cervical spine



15mm  
[proj]

