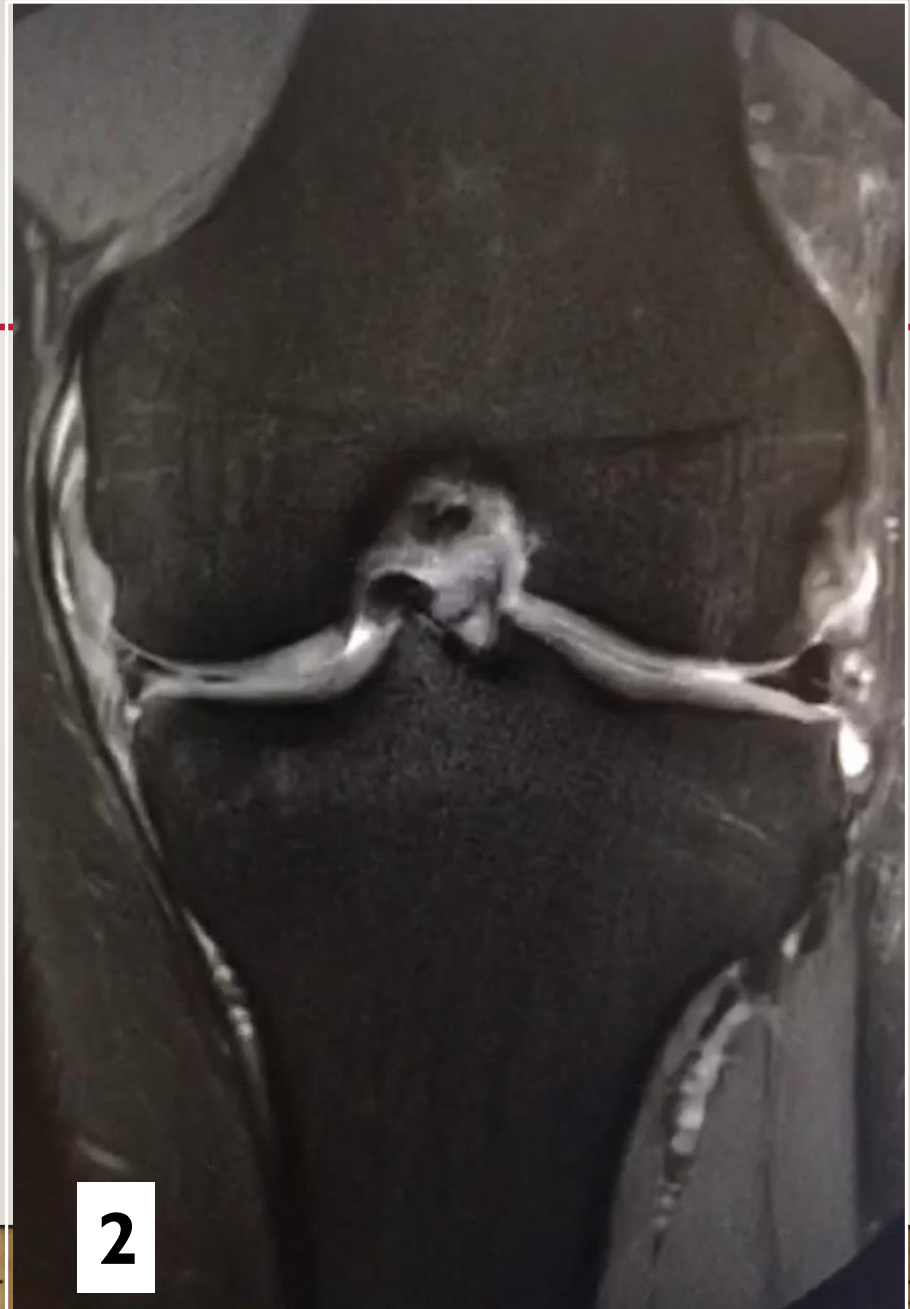
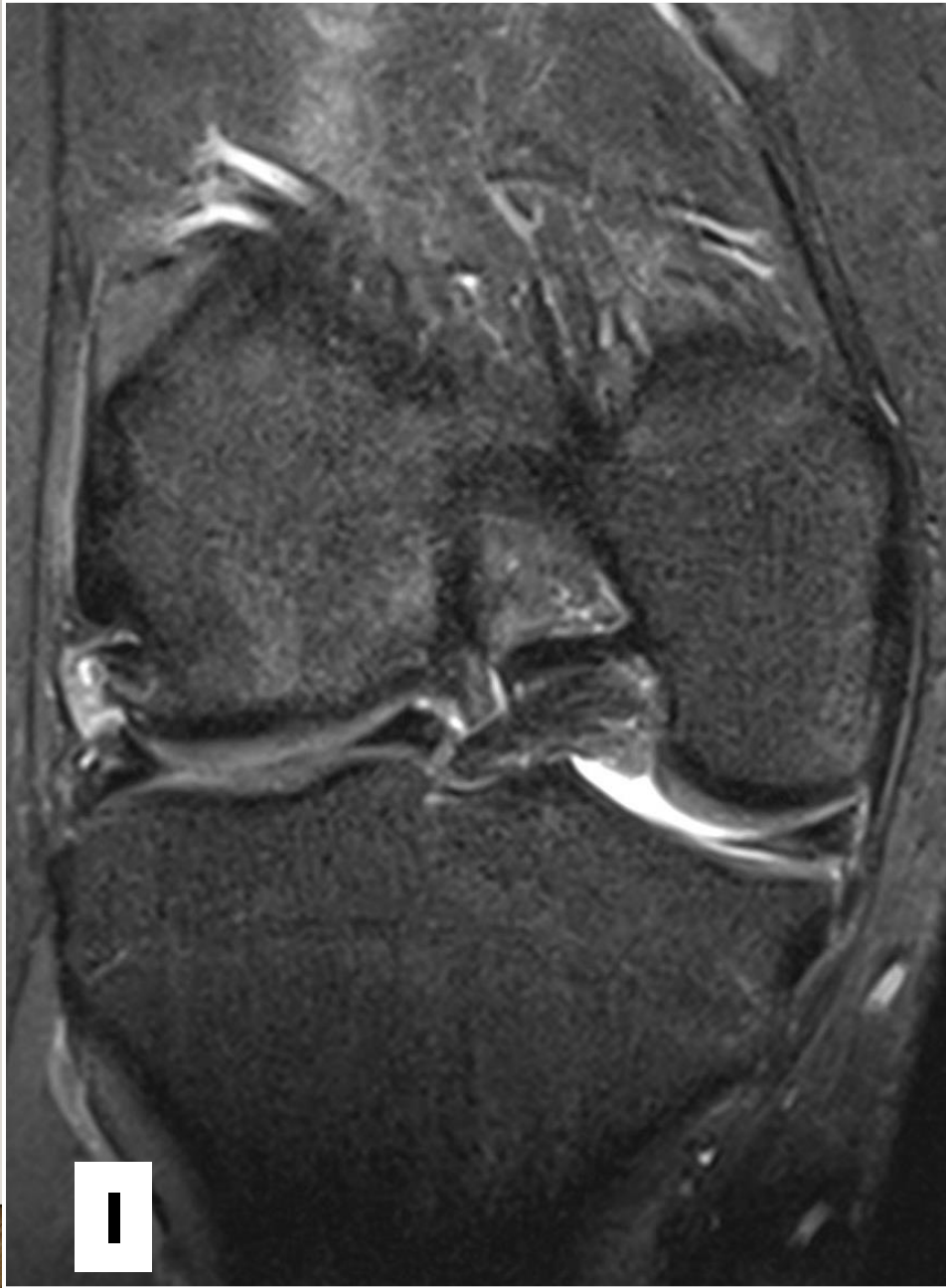


MICOD -27/08/2023

Case contributor – Dr.Neha Nischal & Dr. Rajesh Botchu





# QUESTIONS

- What is the diagnosis in case 1?
- What is the diagnosis in case 2?
- How will you differentiate between the two?