

MICOD -26/08/2023

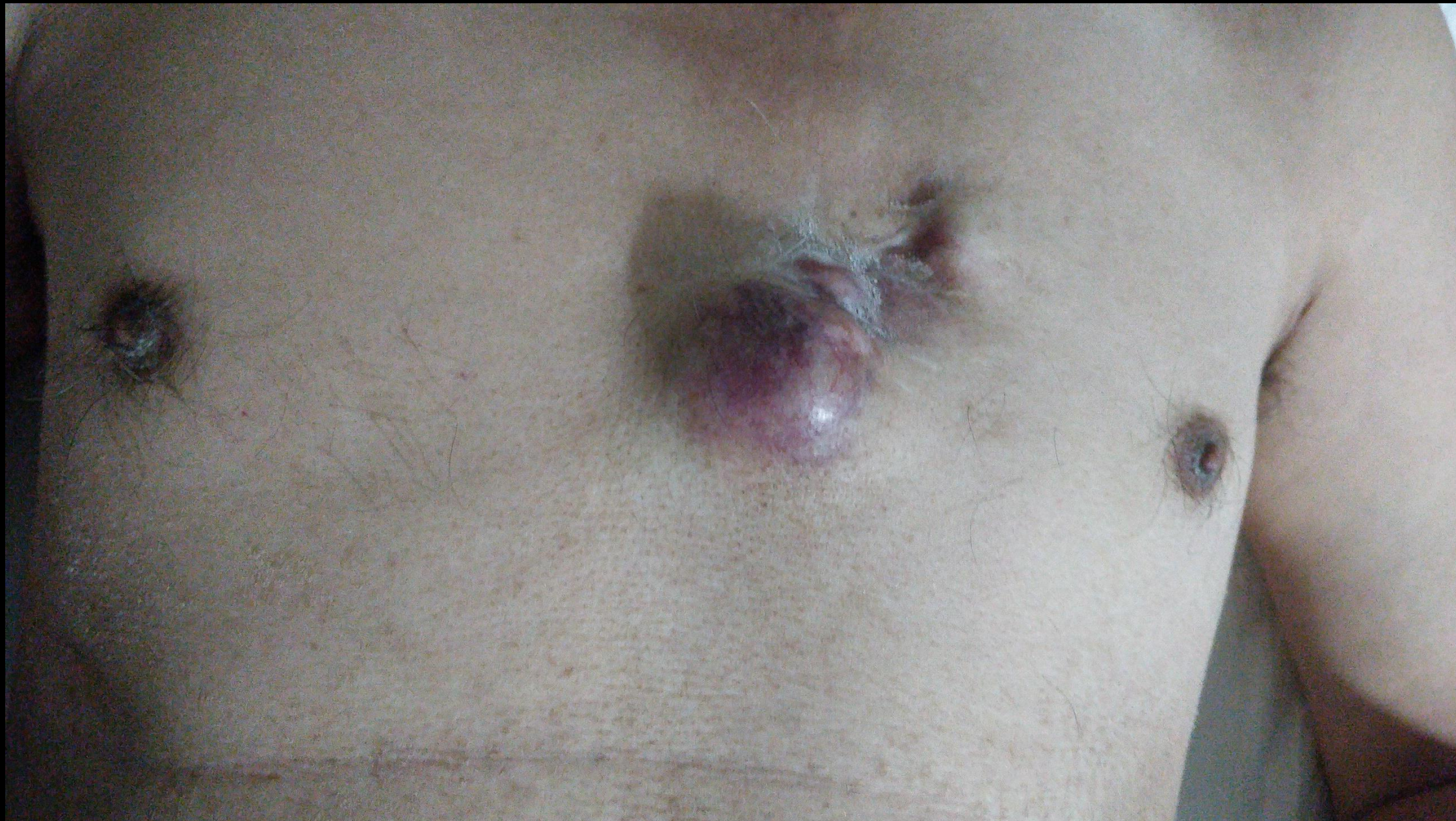Case contributor – Dr. Sonal Saran

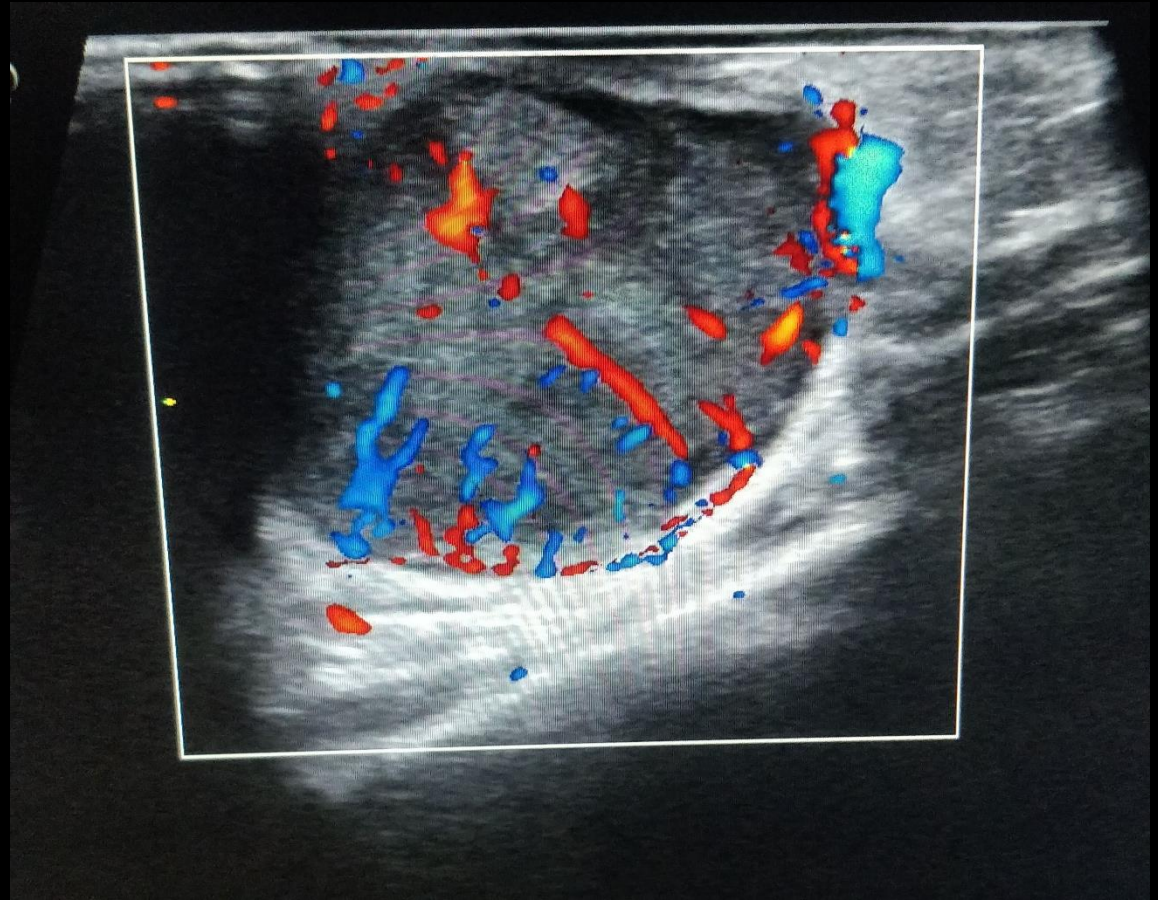
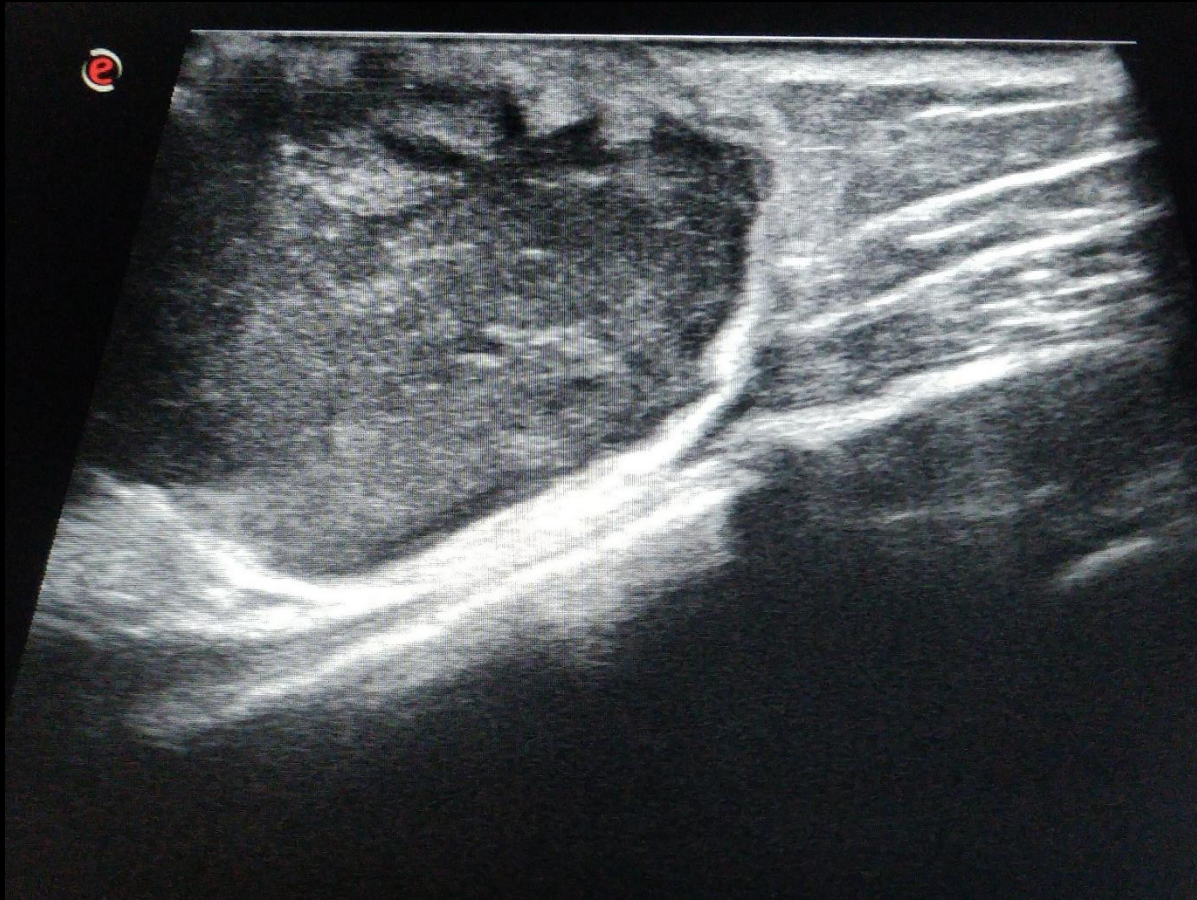
MI-COD

MSS INDIA- Case Of the Day



Middle age adult patient presented with swelling in anterior chest for 6 months





25.10

g*
mm

