
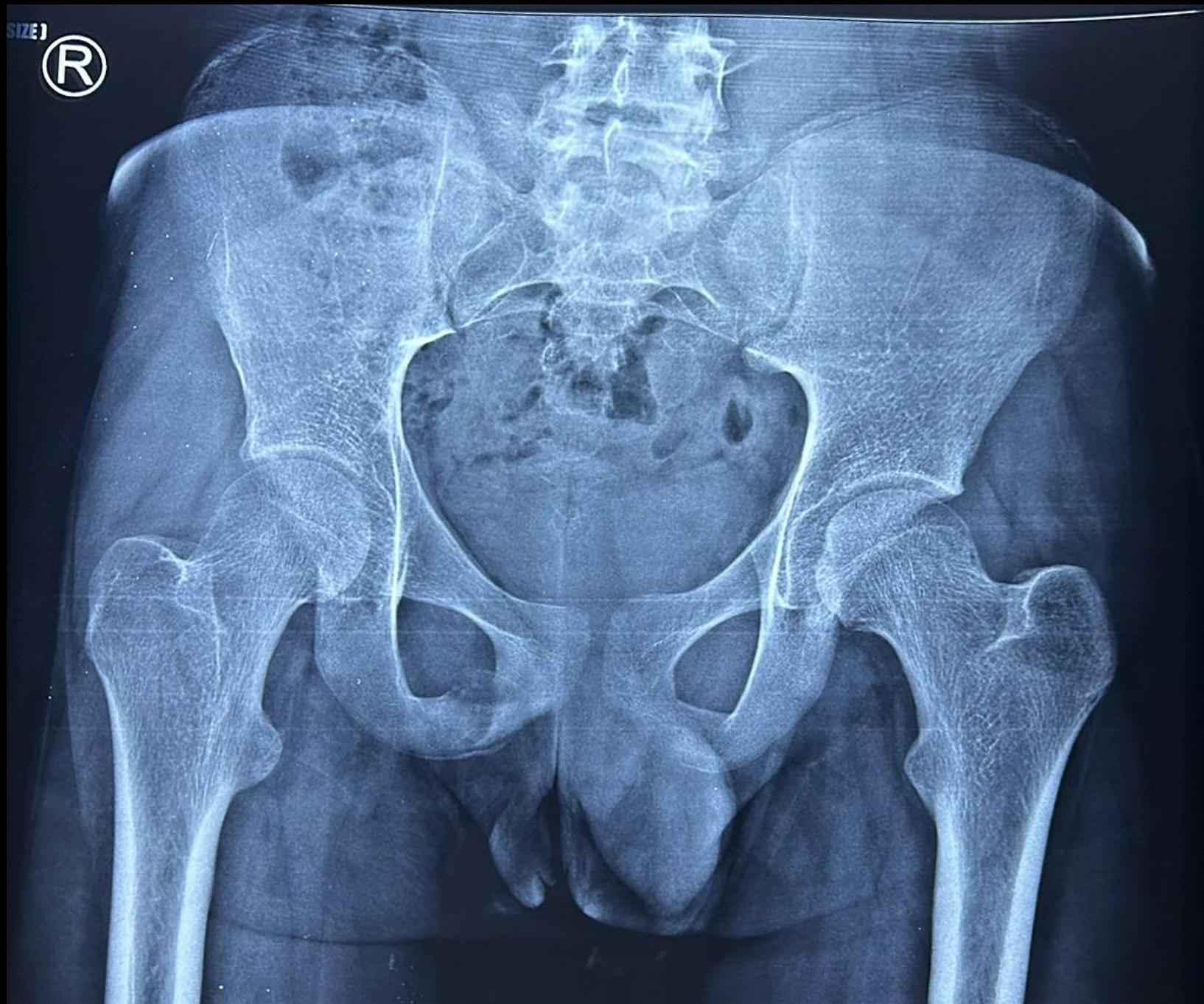


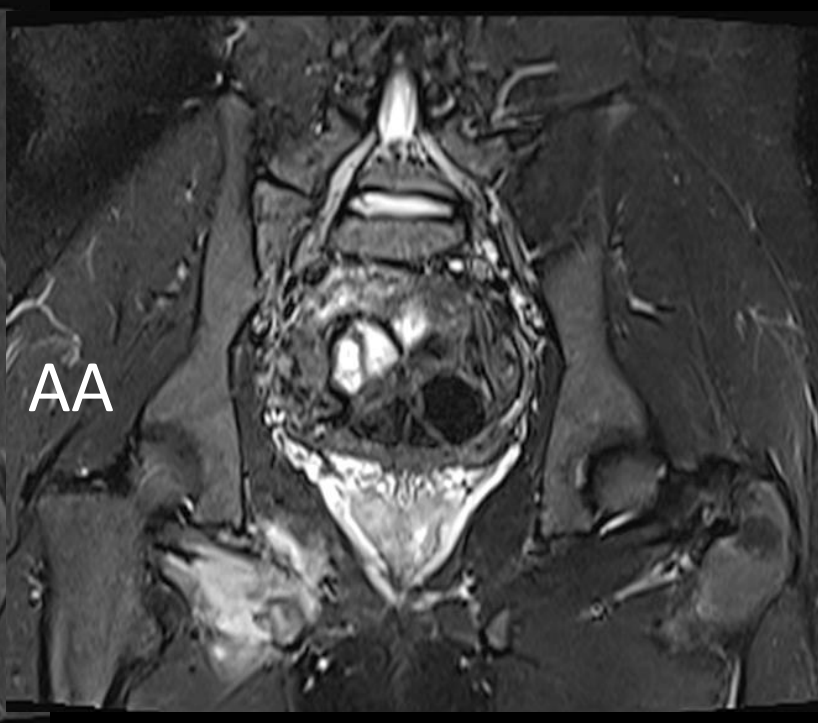
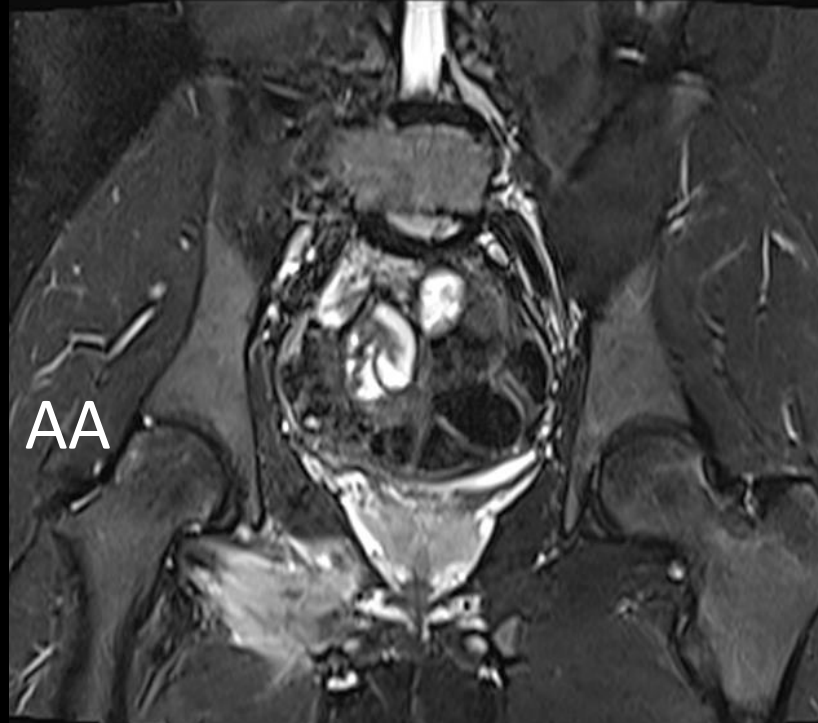
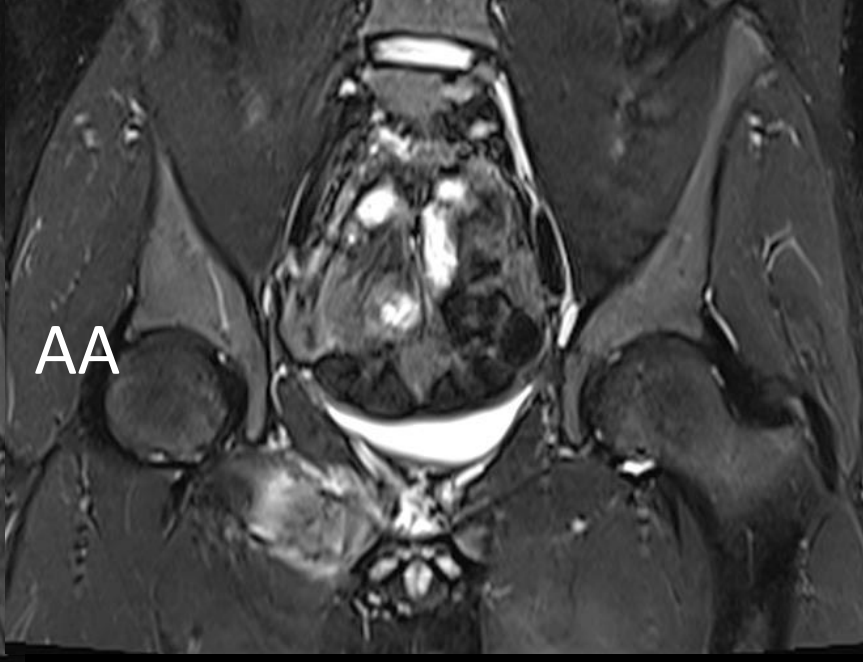
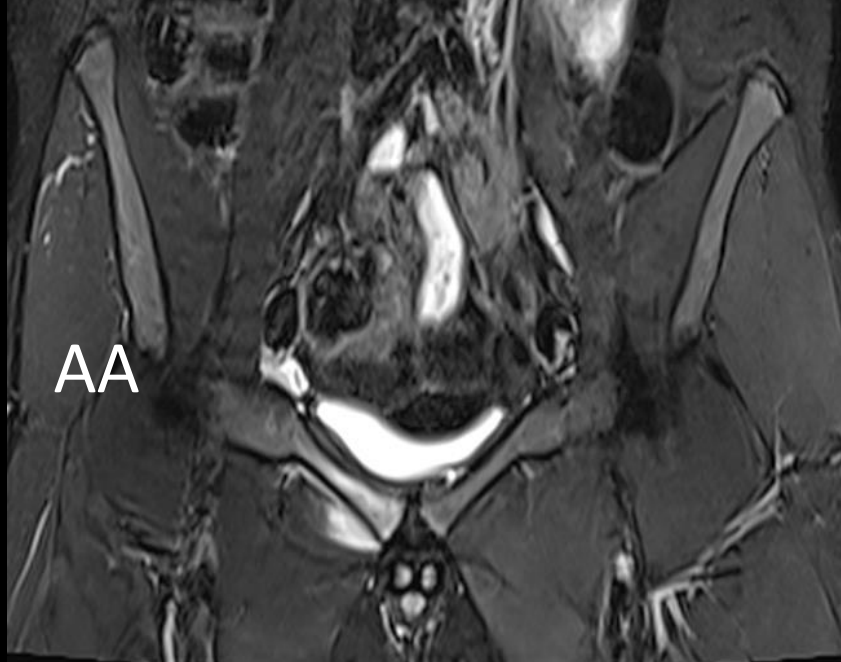
MICOD -23/08/2023
Case contributor –Dr. Ankita Ahuja



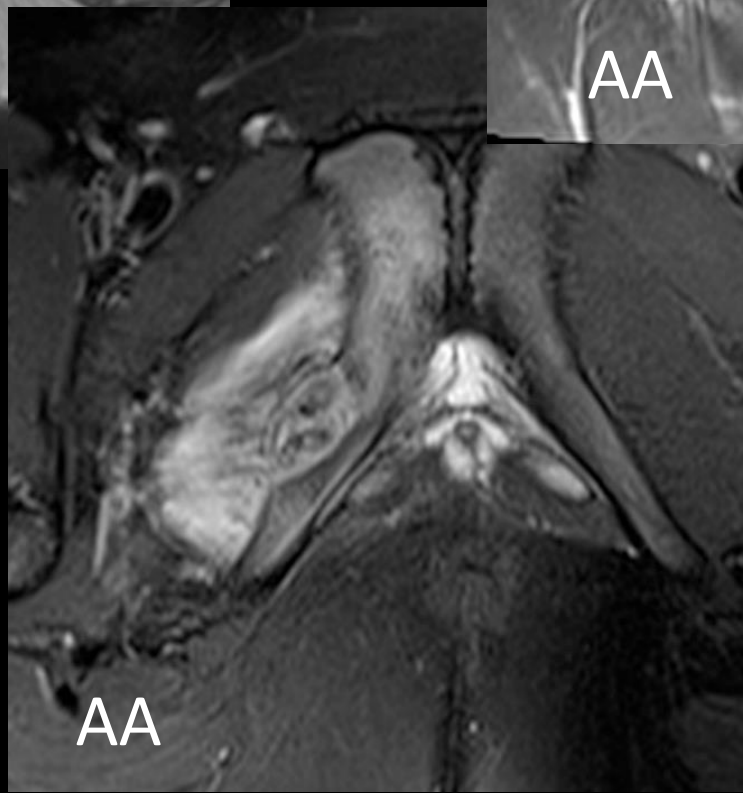
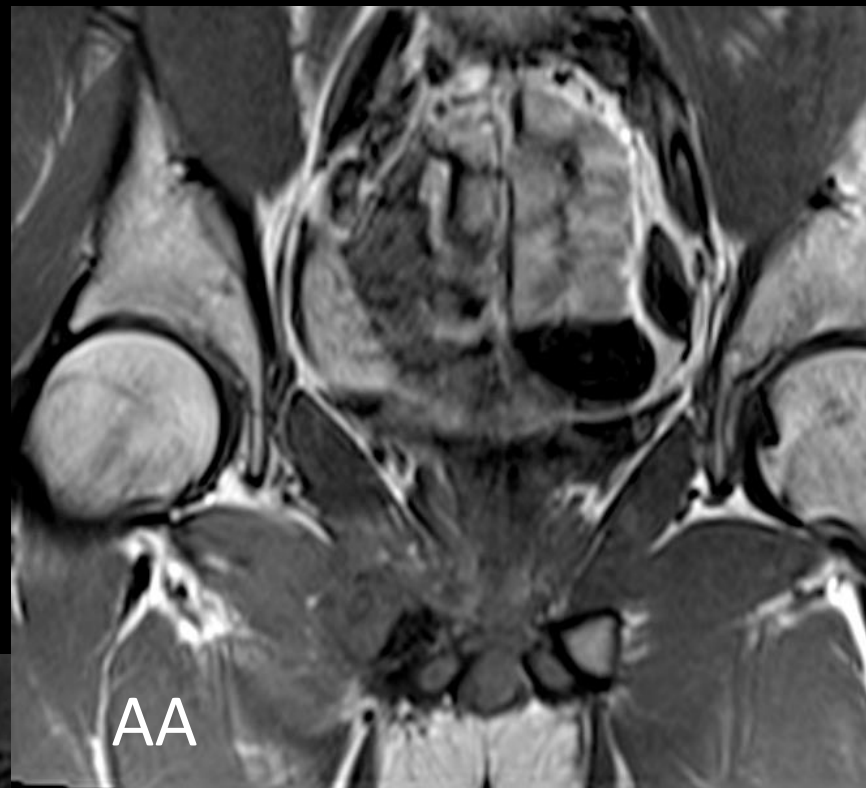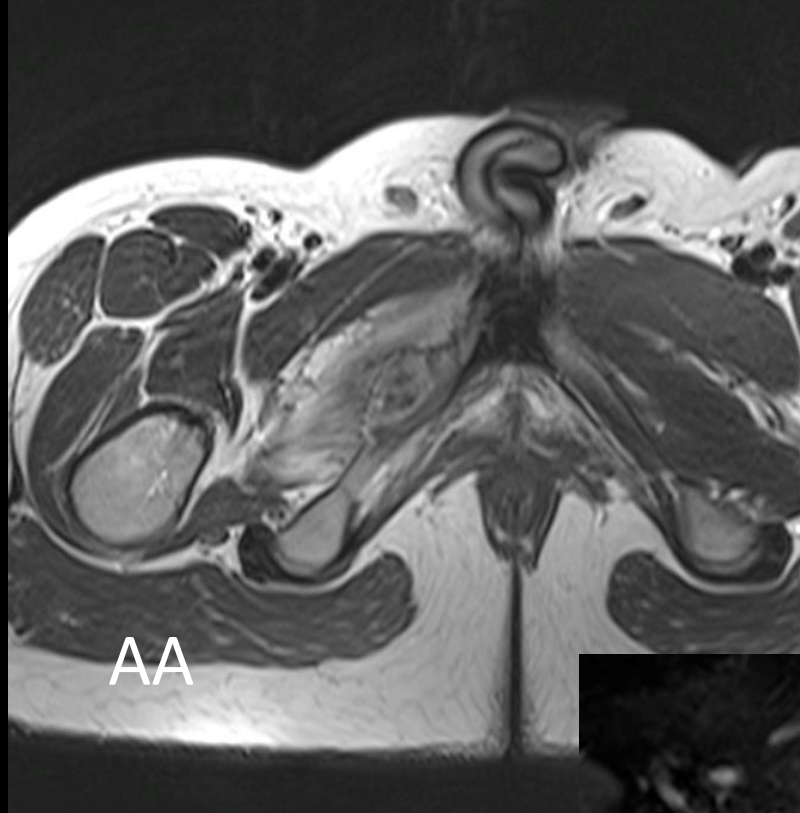- 18 year old with right hip pain.

SIZE 1





STIR



QUESTIONS:

1) What do you think is the etiology?

A. Non-aggressive

B. Locally aggressive

C. Aggressive

2) What are your differentials?

3) Any other modality to further characterize the lesion?