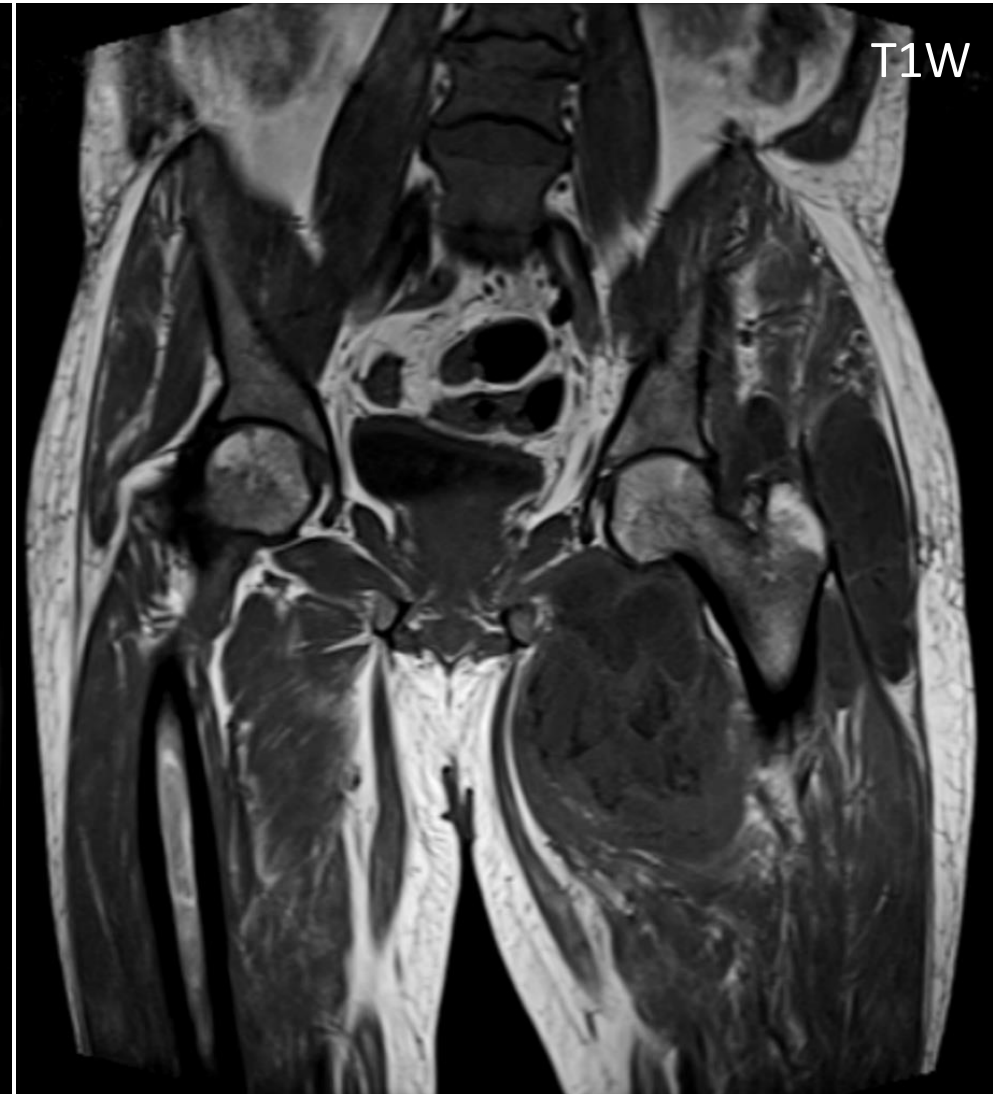
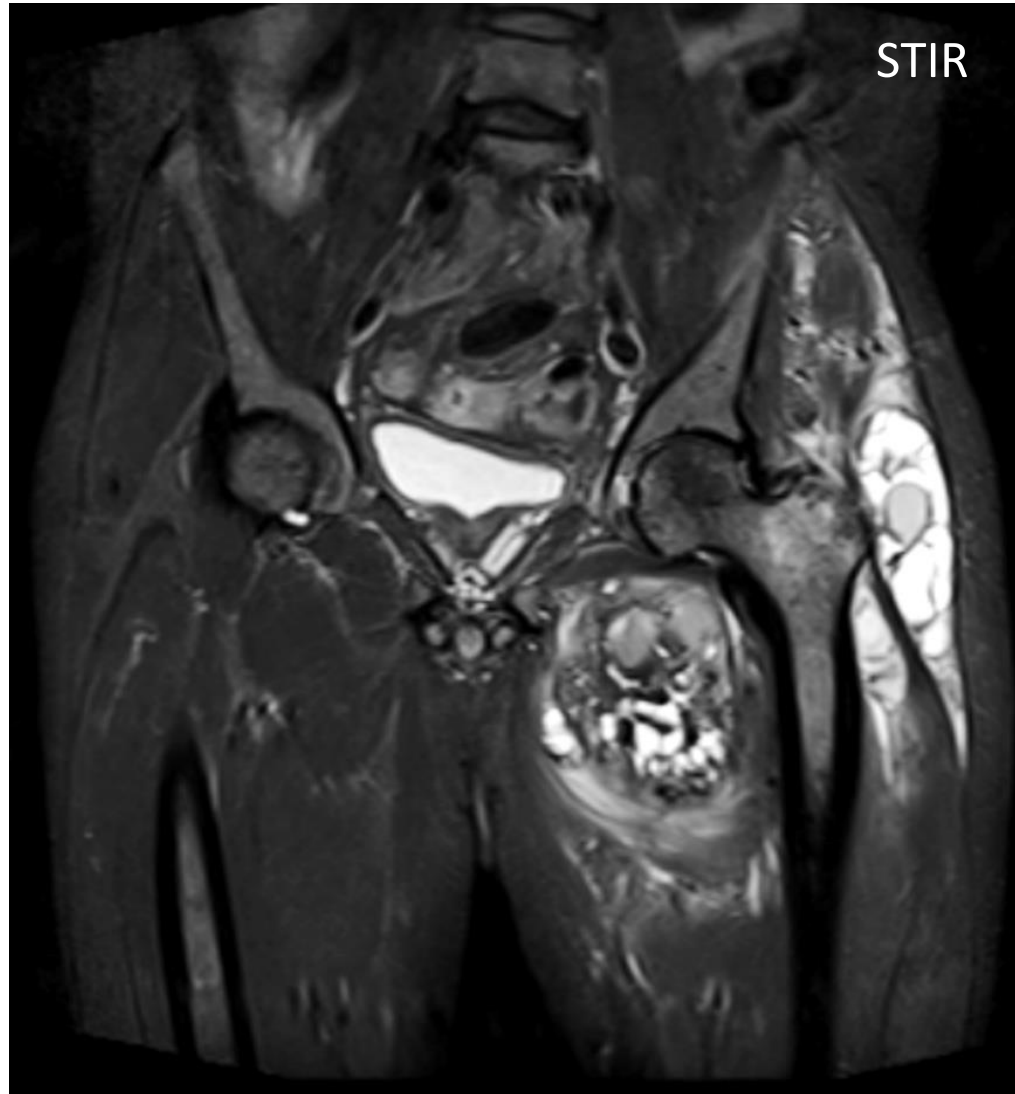

**MICOD 29/09/2023**

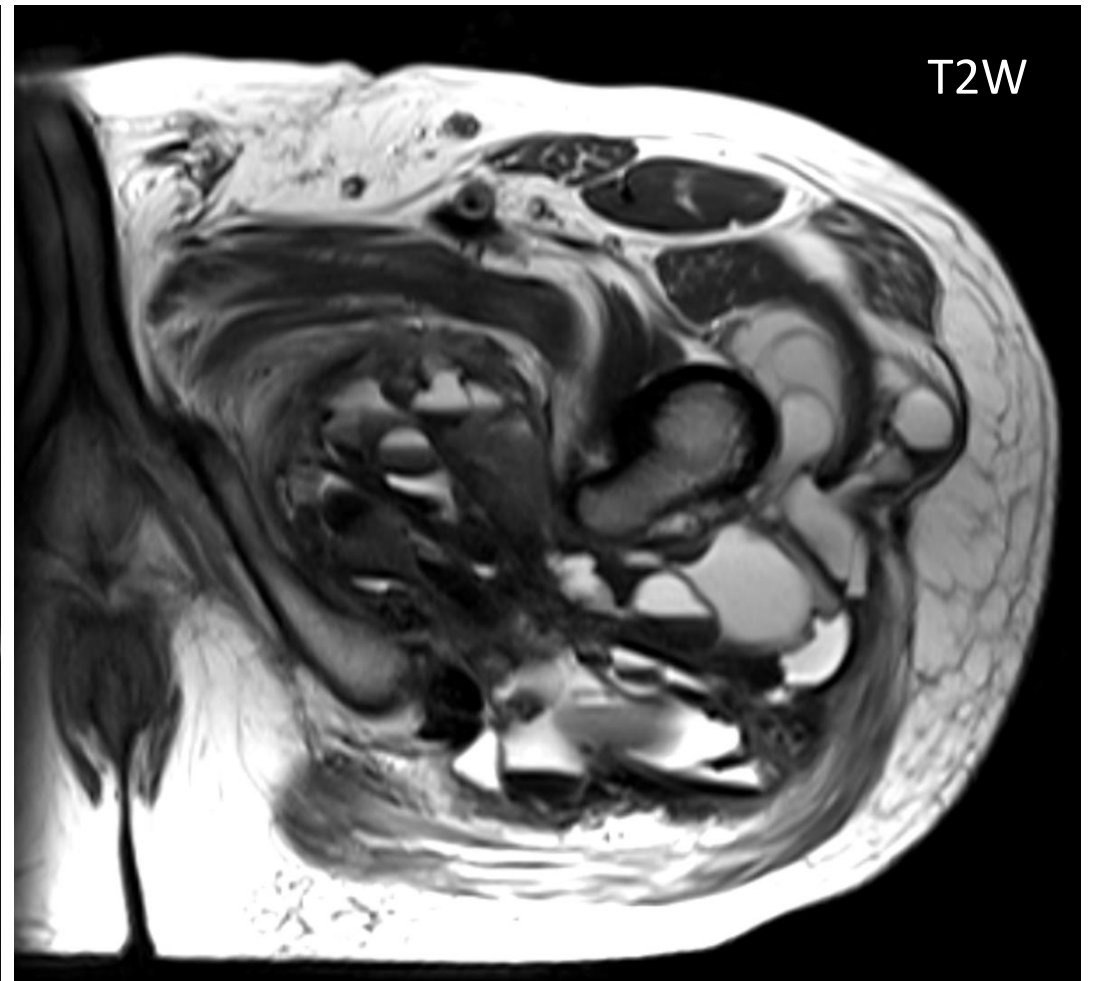
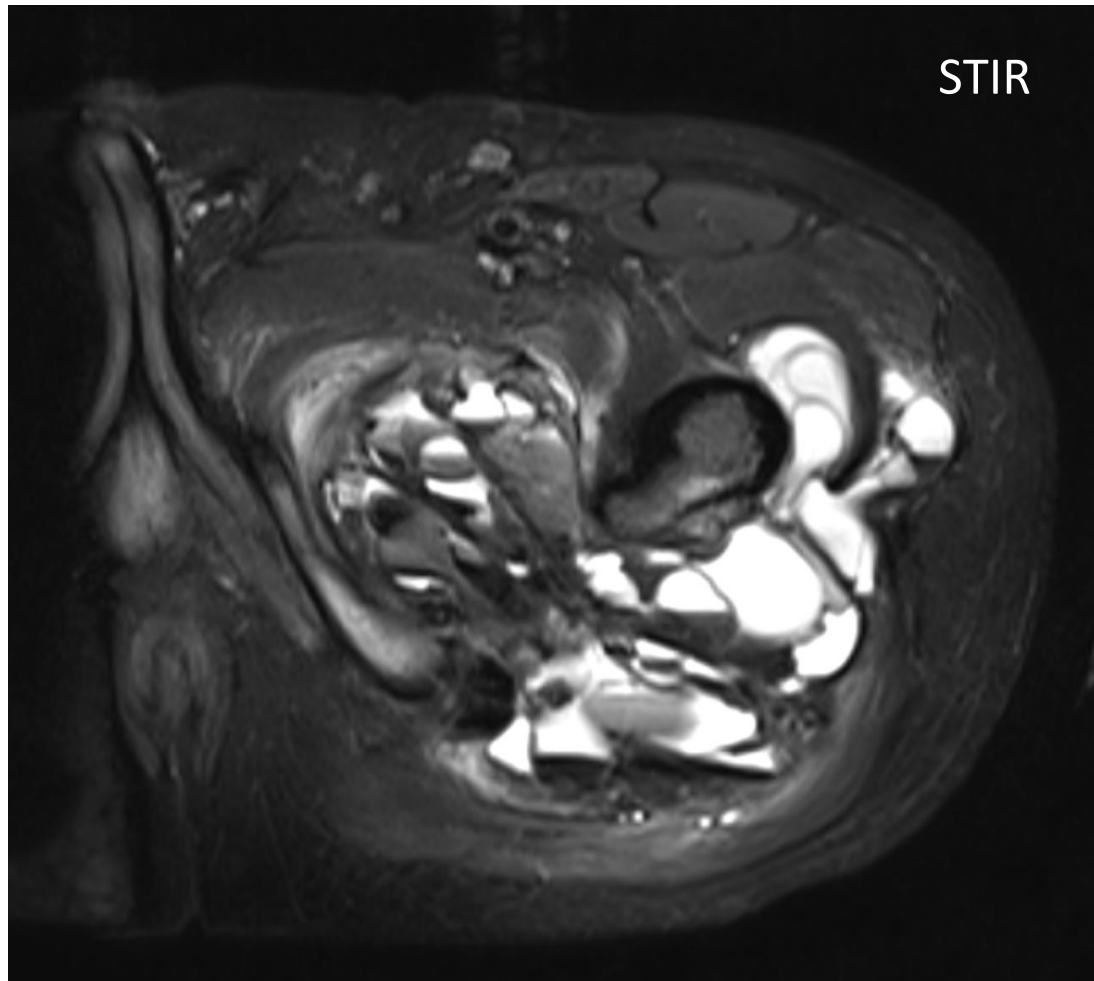
**Case Courtesy: Dr. Madhavi K (CMC Vellore)**



History - 28 year old with pain and swelling



History - 28 year old with pain and swelling



Possible diagnosis ?