

MICOD- 28.09.203

Case Courtesy: Dr. Uma Maheshwara Reddy V, Professor, Narayana Medical College, Nellore

# MI-COD

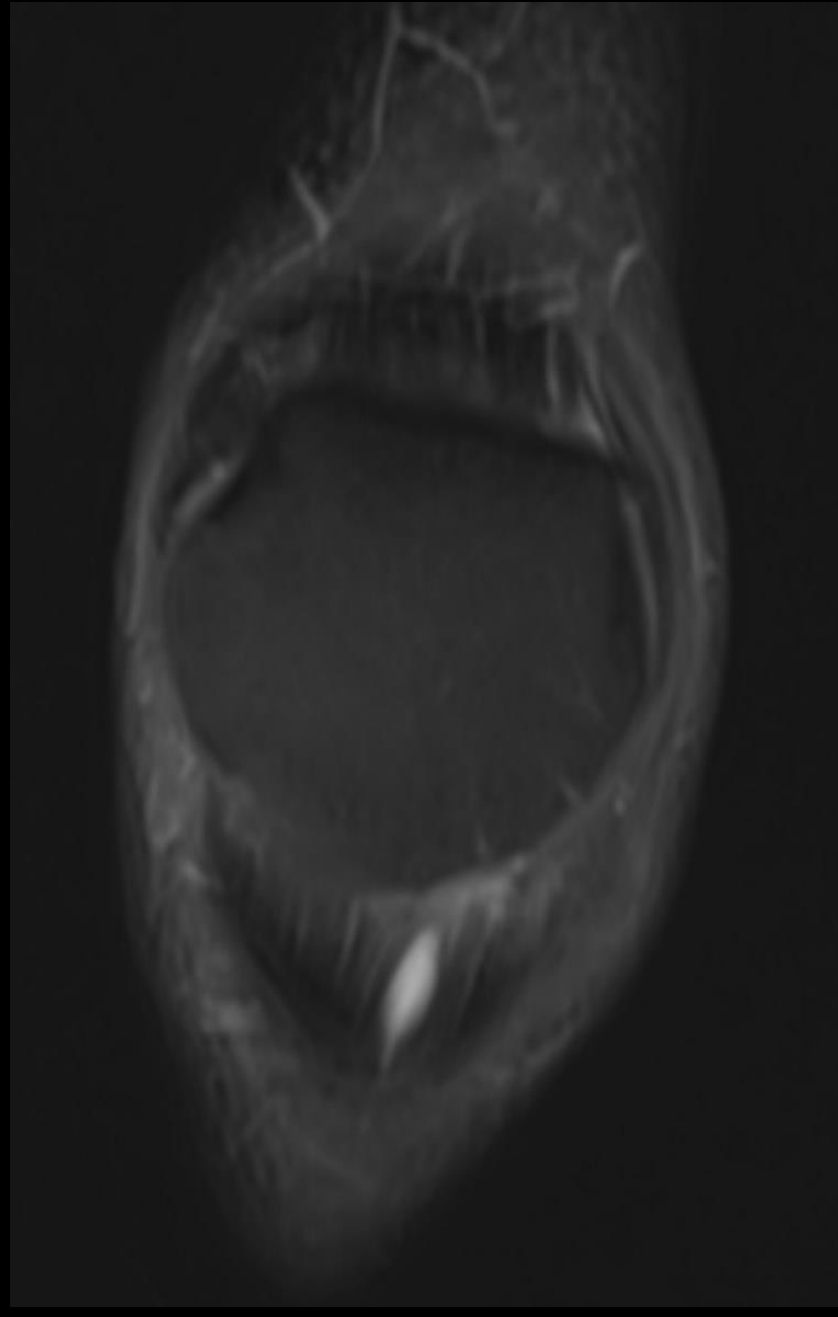
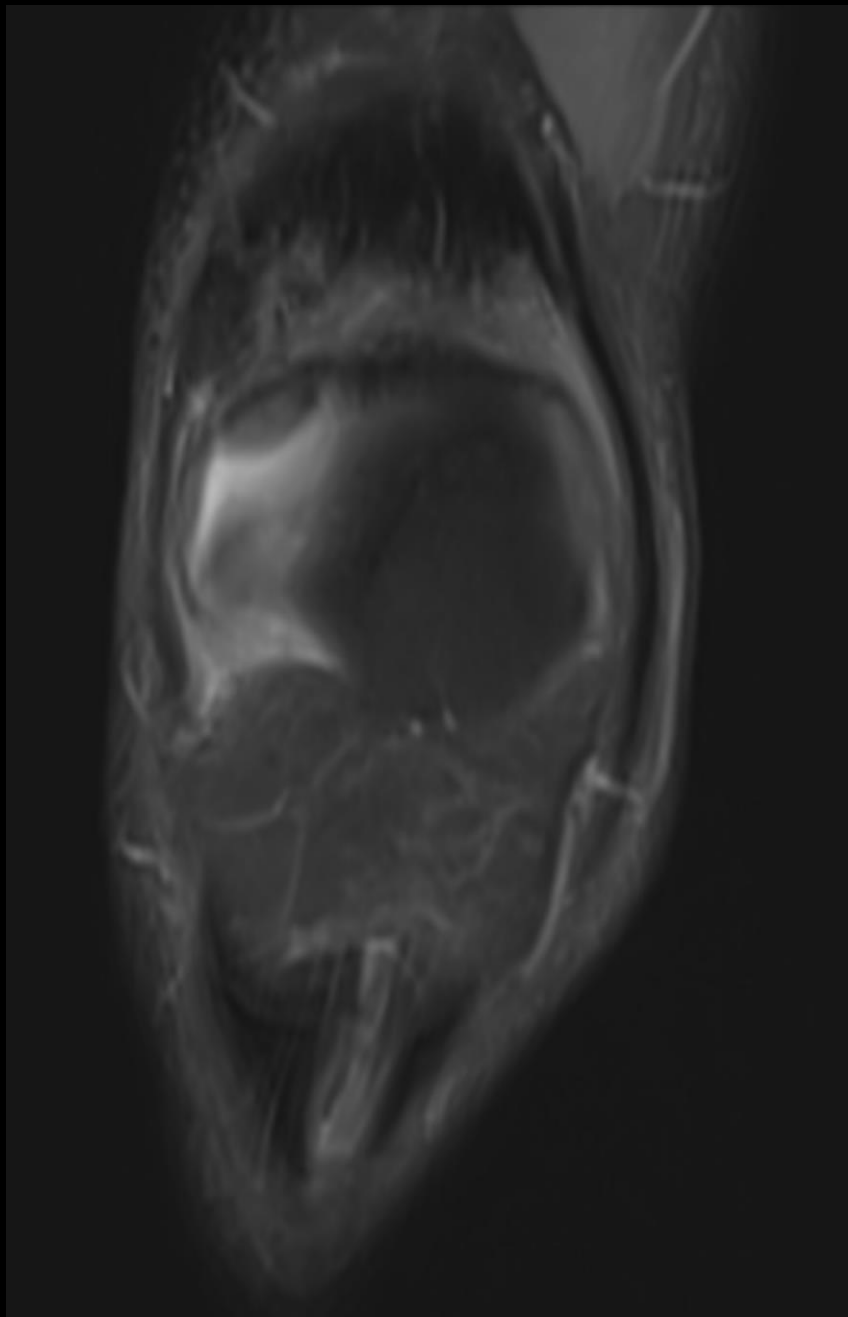
MSS INDIA- Case Of the Day

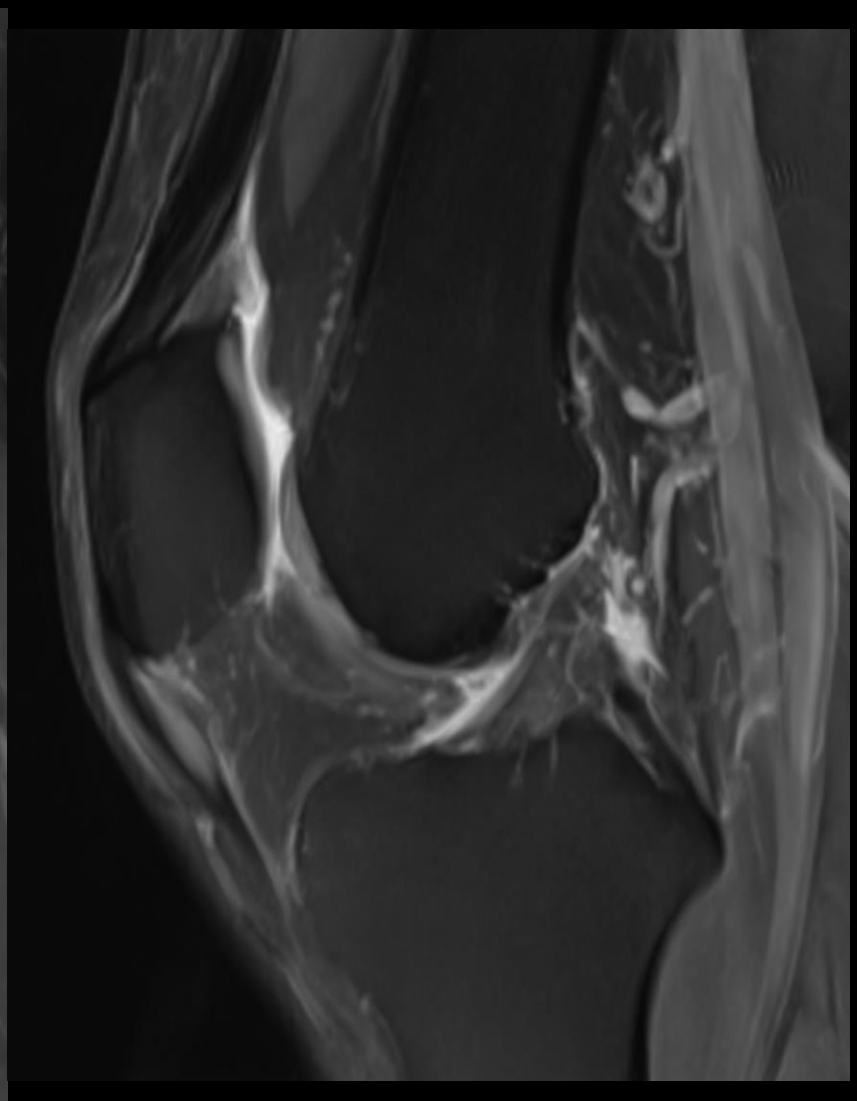
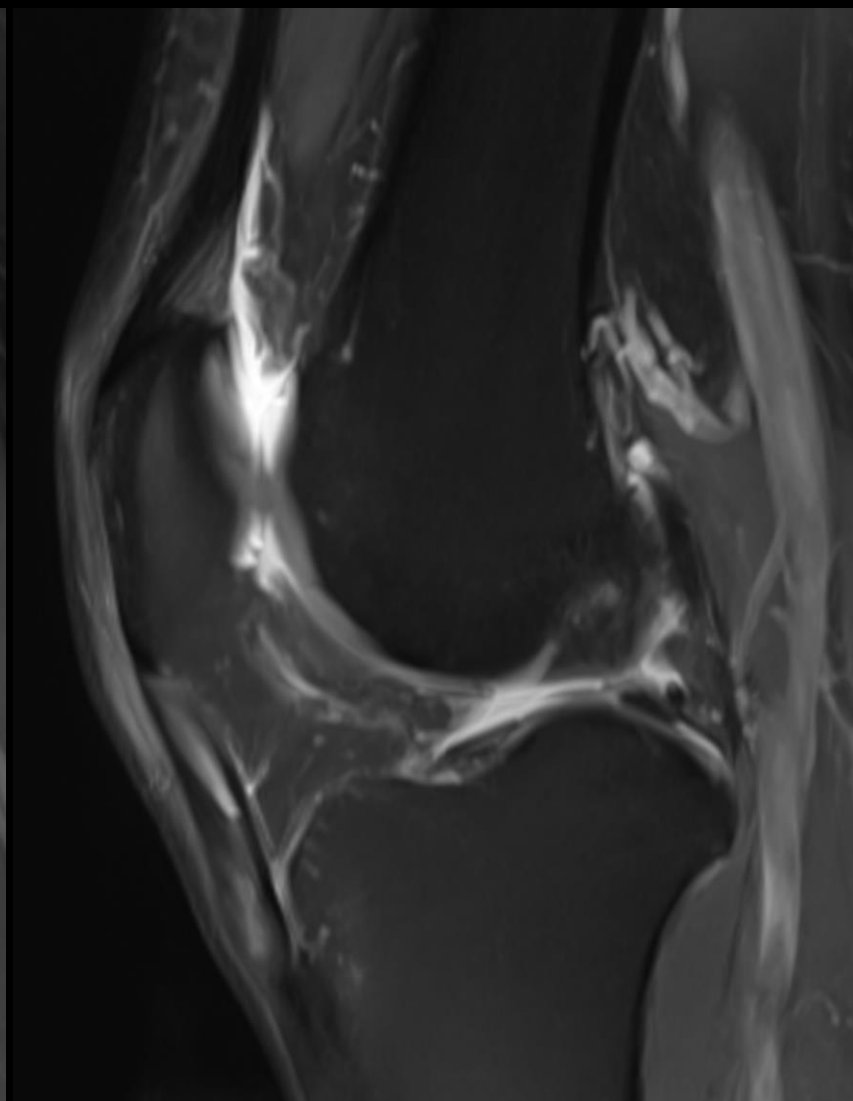
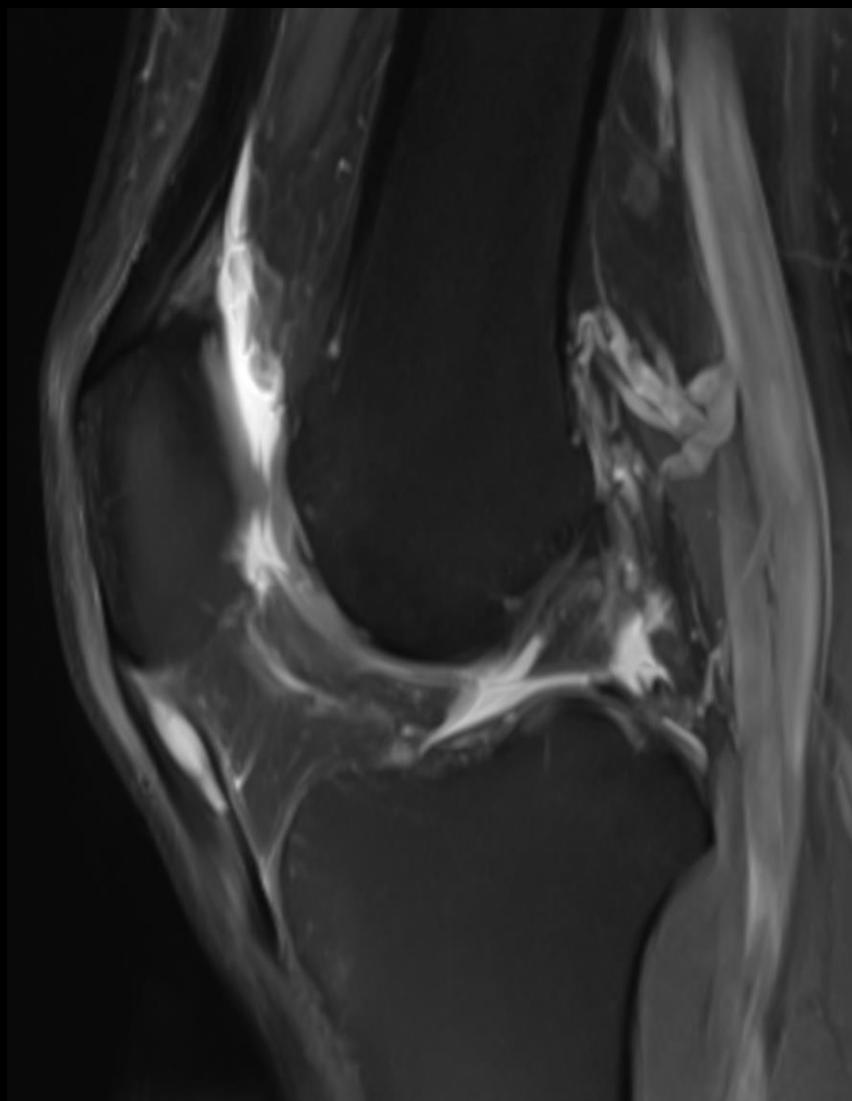


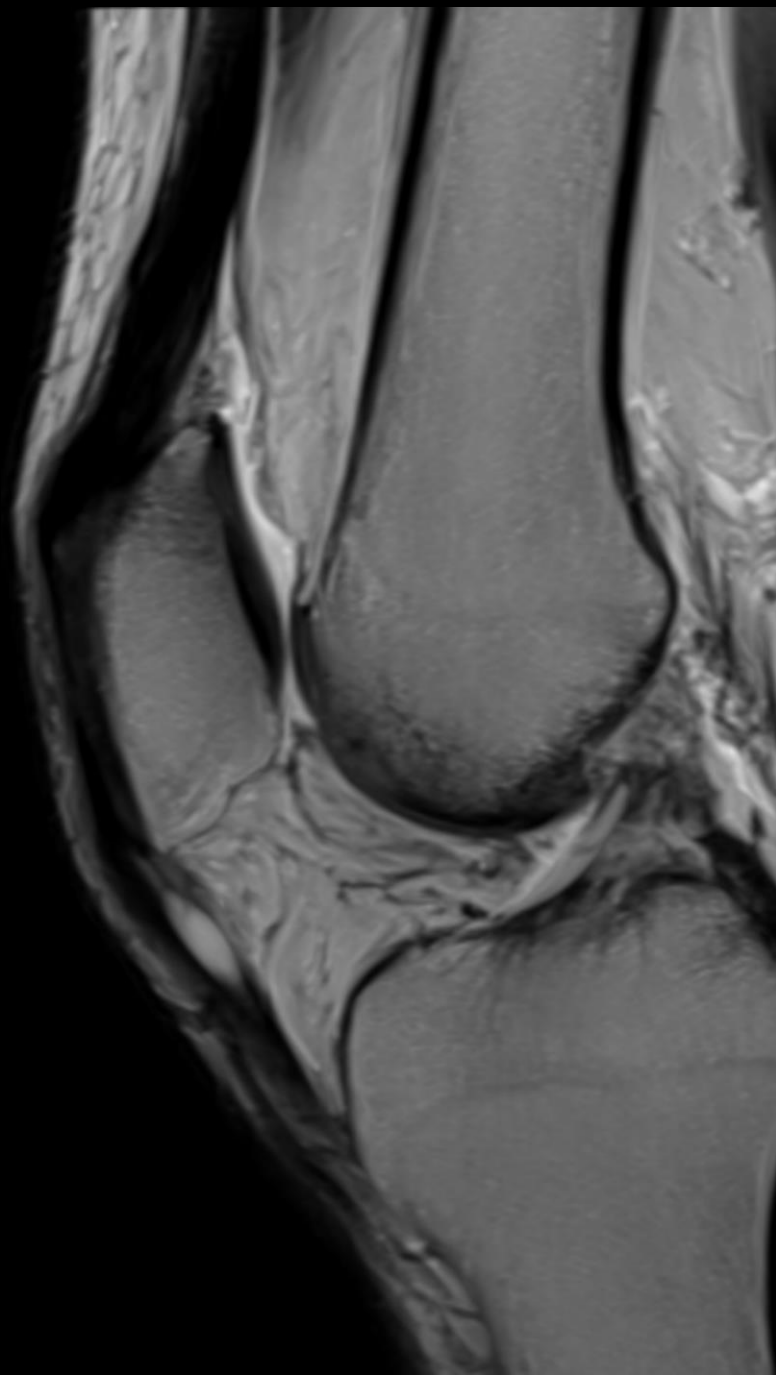
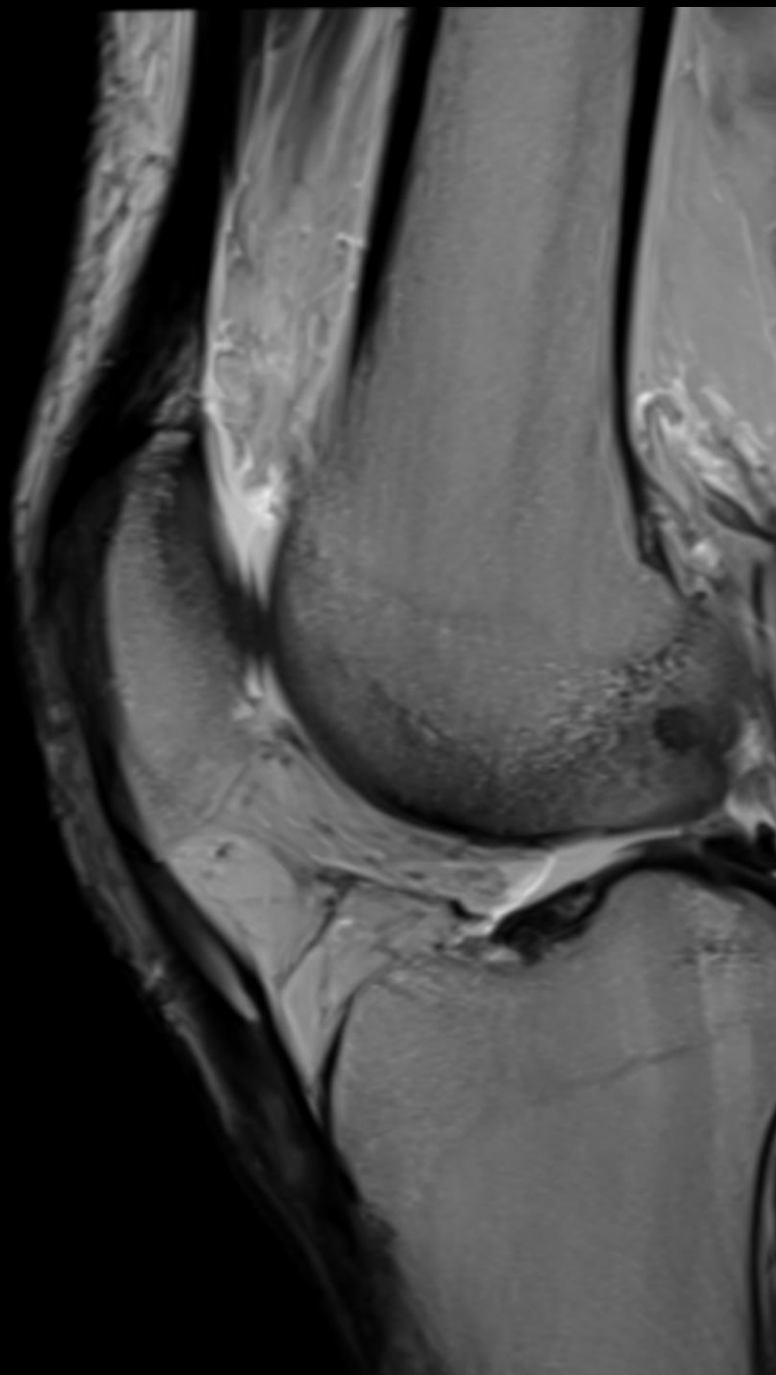
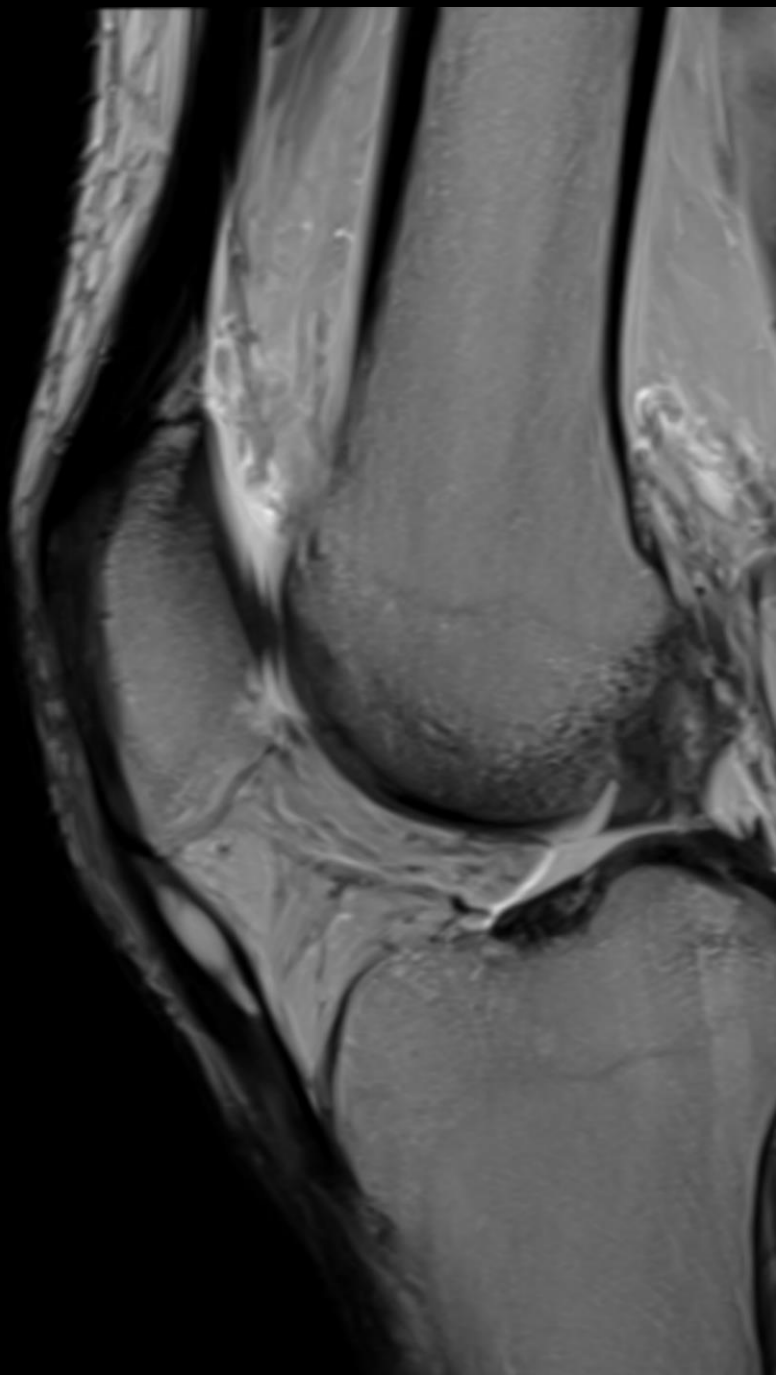
# Clinical History

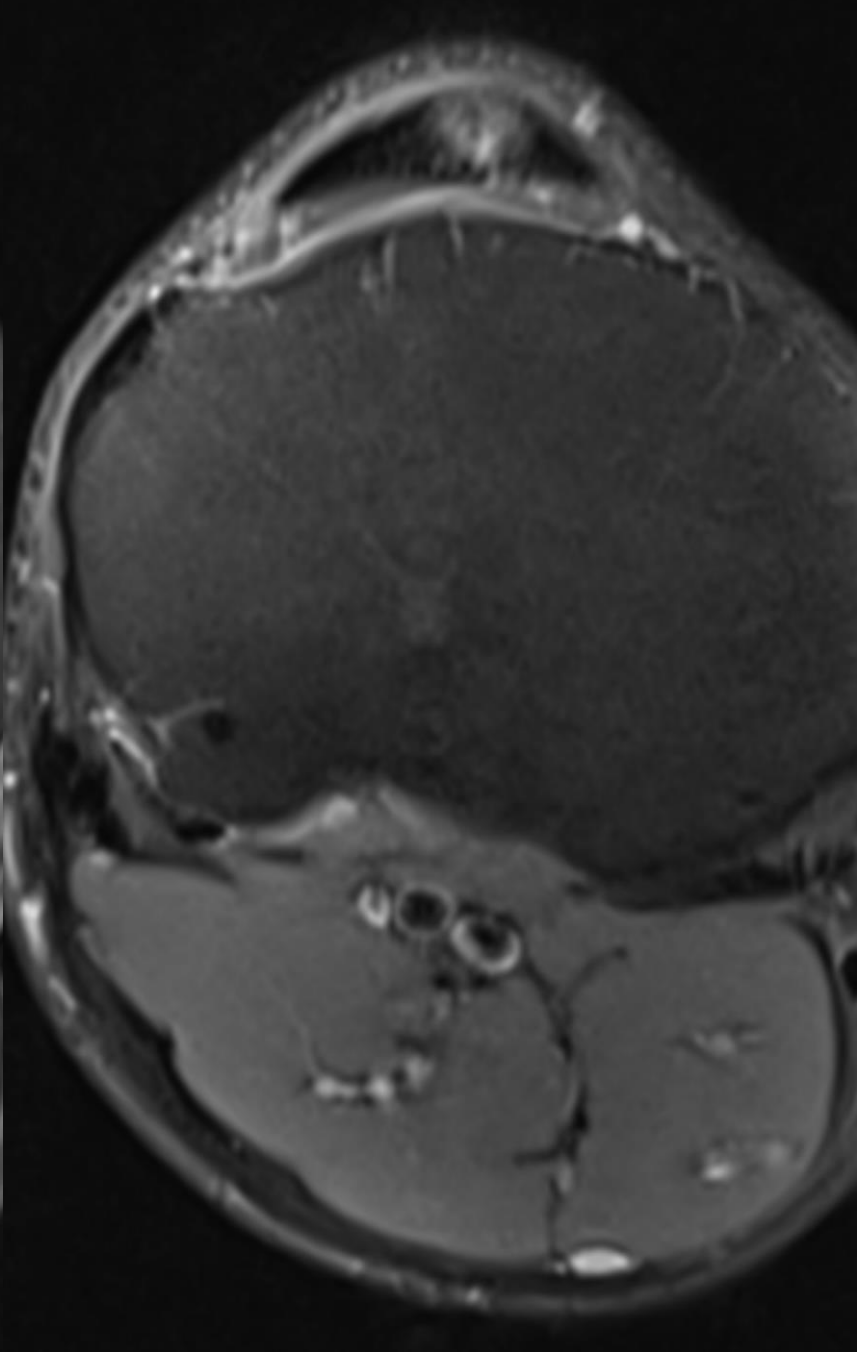
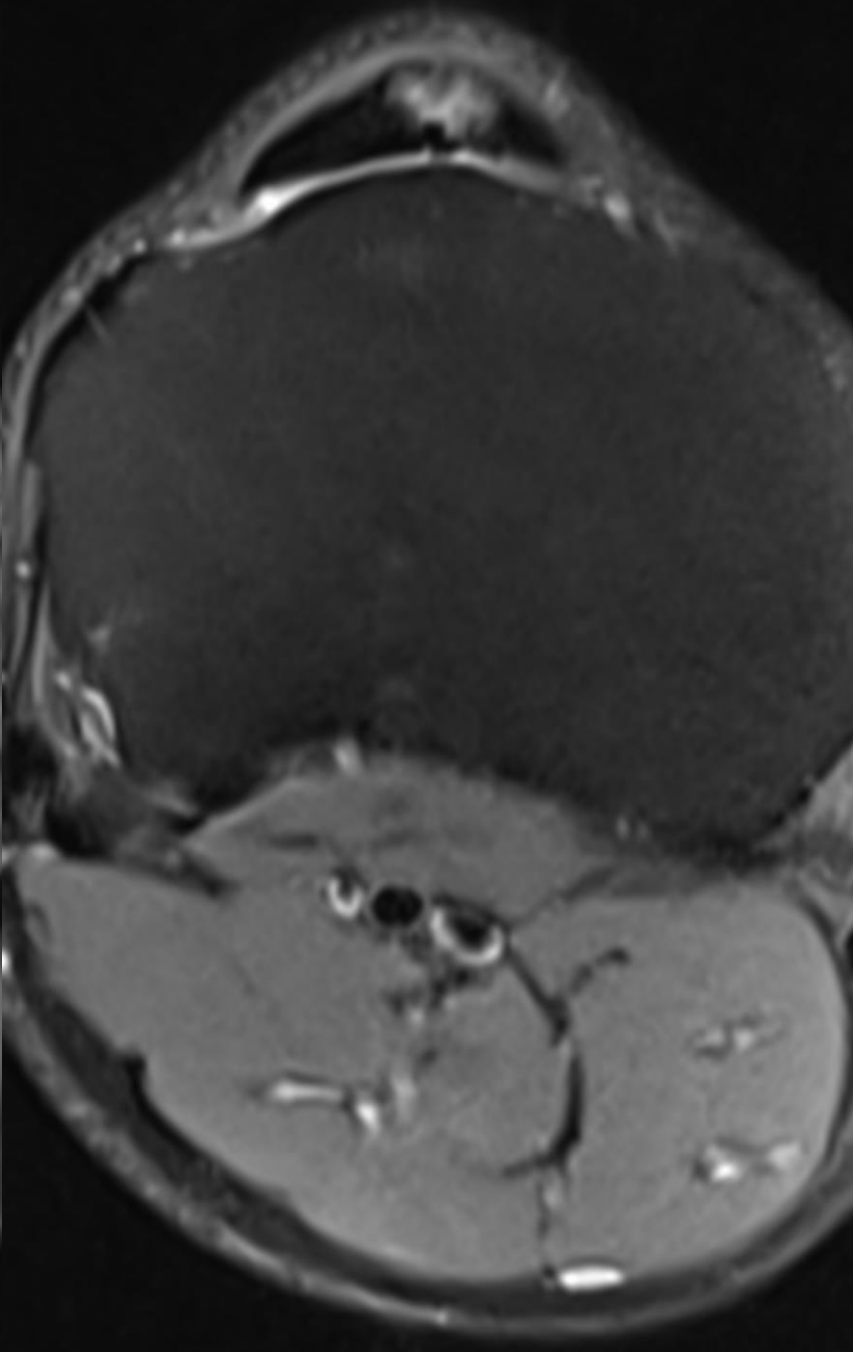
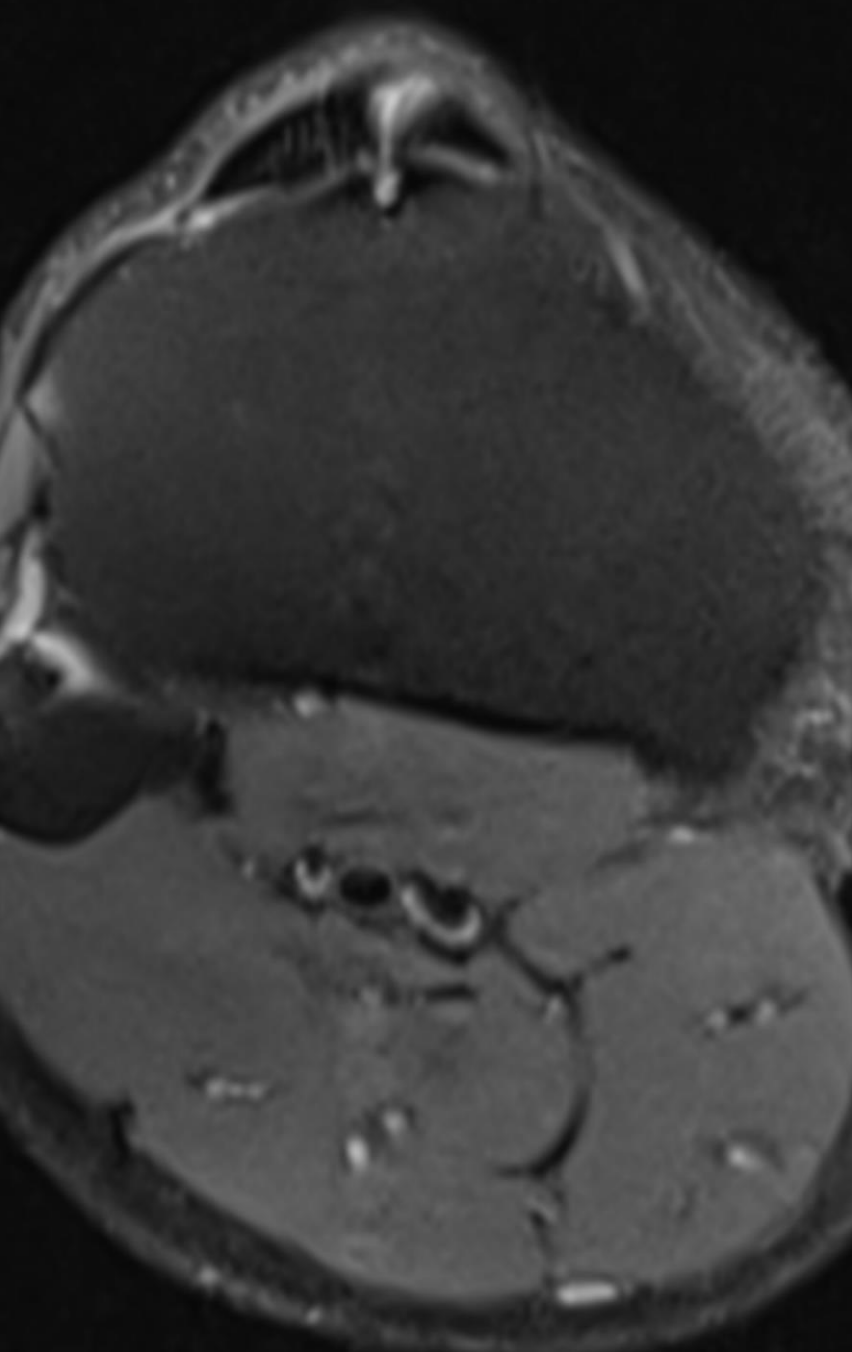
- A young adult athlete who has been consistently engaging in strenuous gym workouts has recently presented with persistent anterior knee pain.

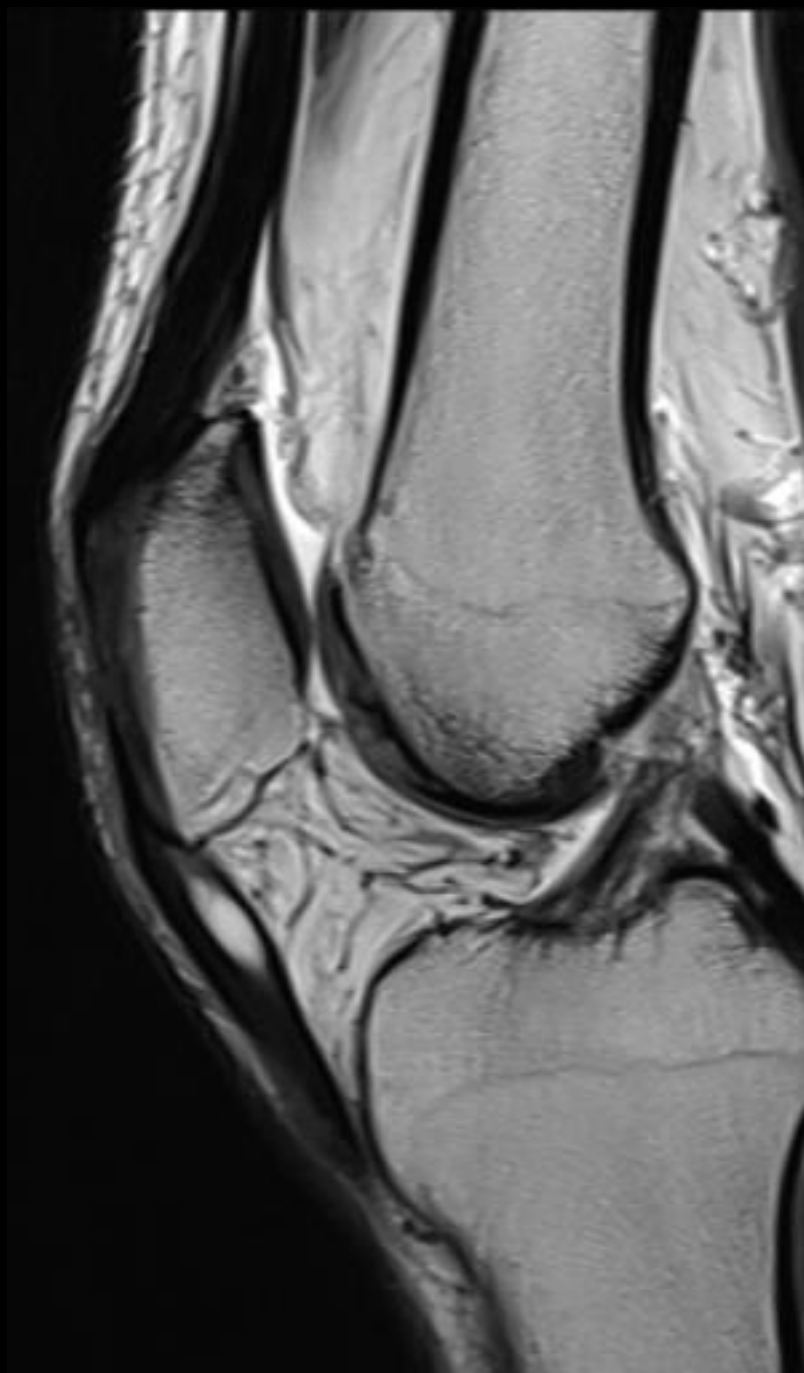
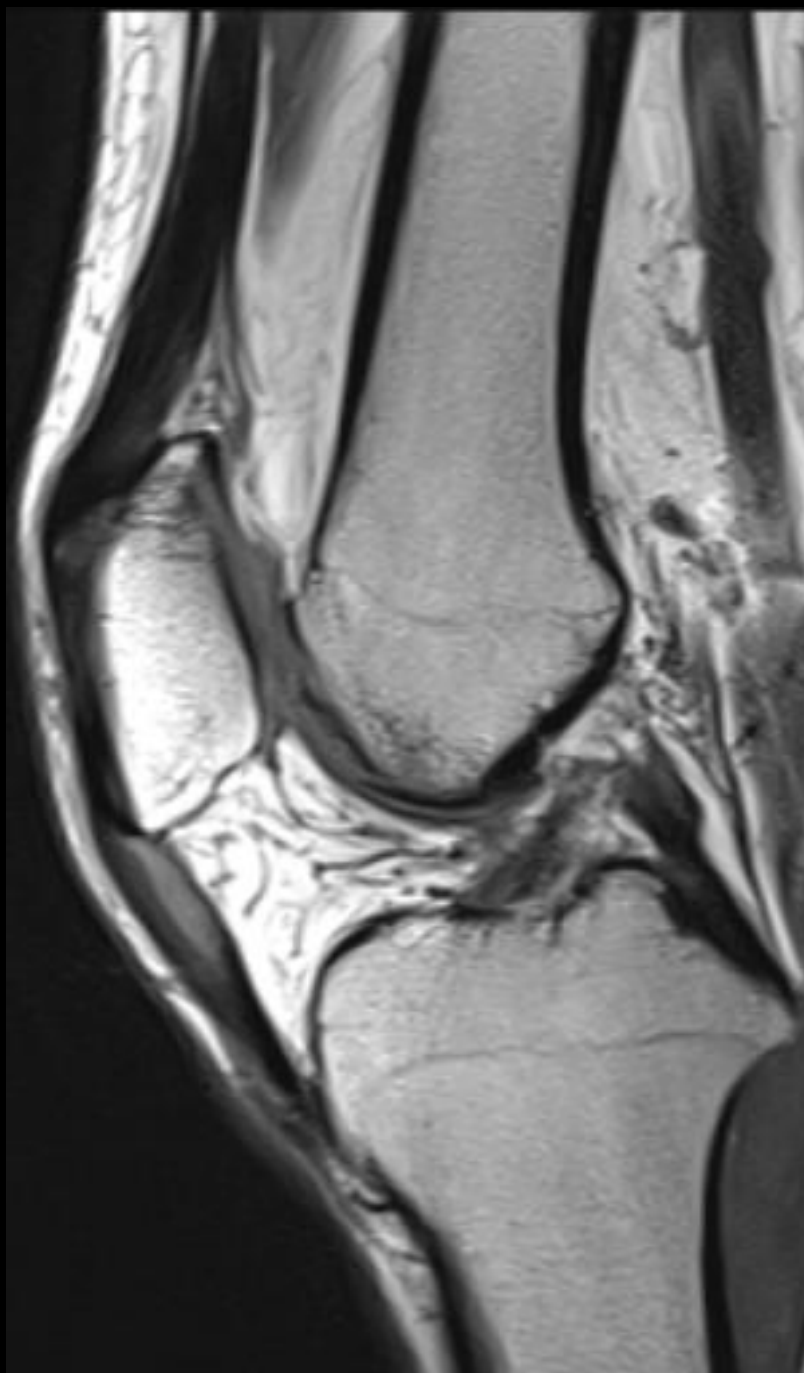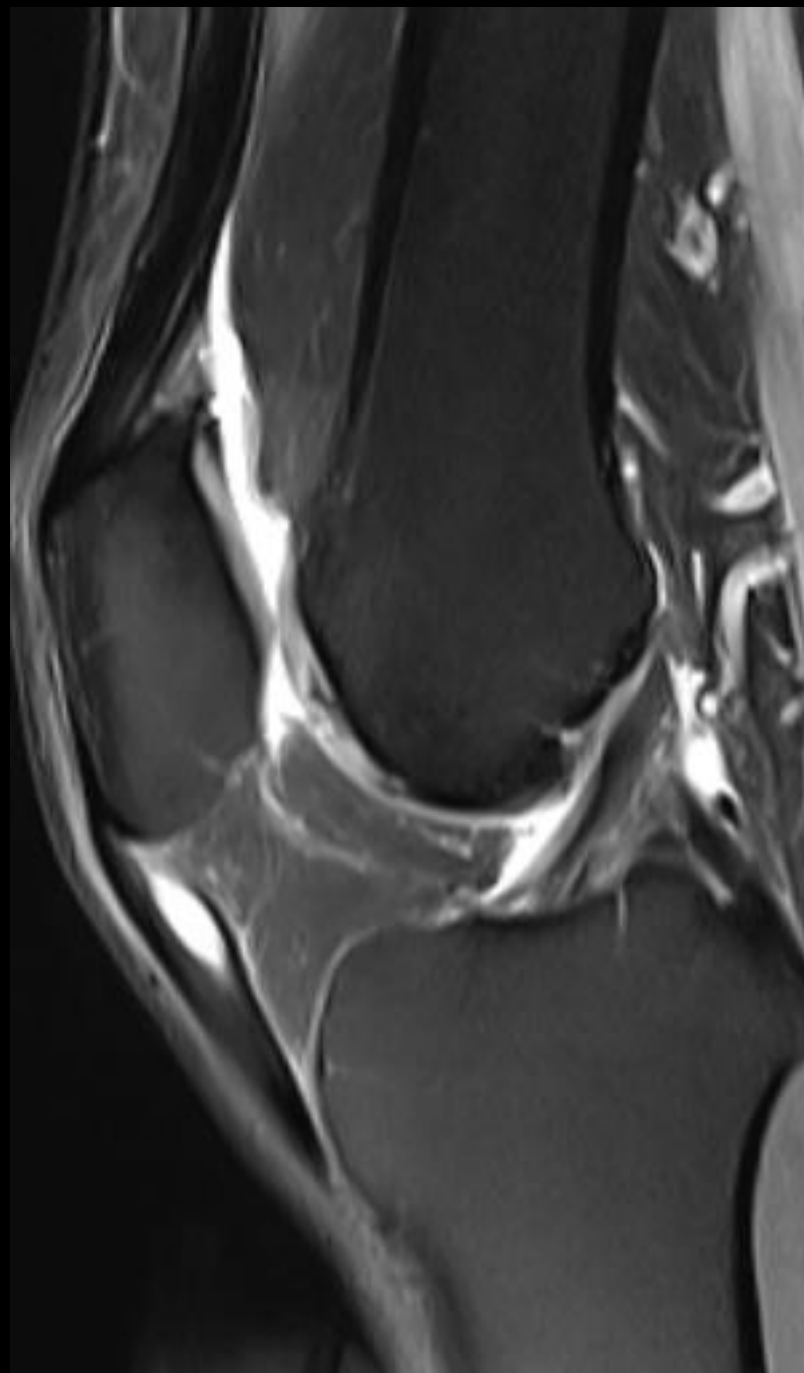
- In view of the above clinical findings, the patient was subjected to MRI Knee













1. What are the MRI findings?
2. What is the Diagnosis?
3. What is the treatment option?
4. Can these recur after treatment?