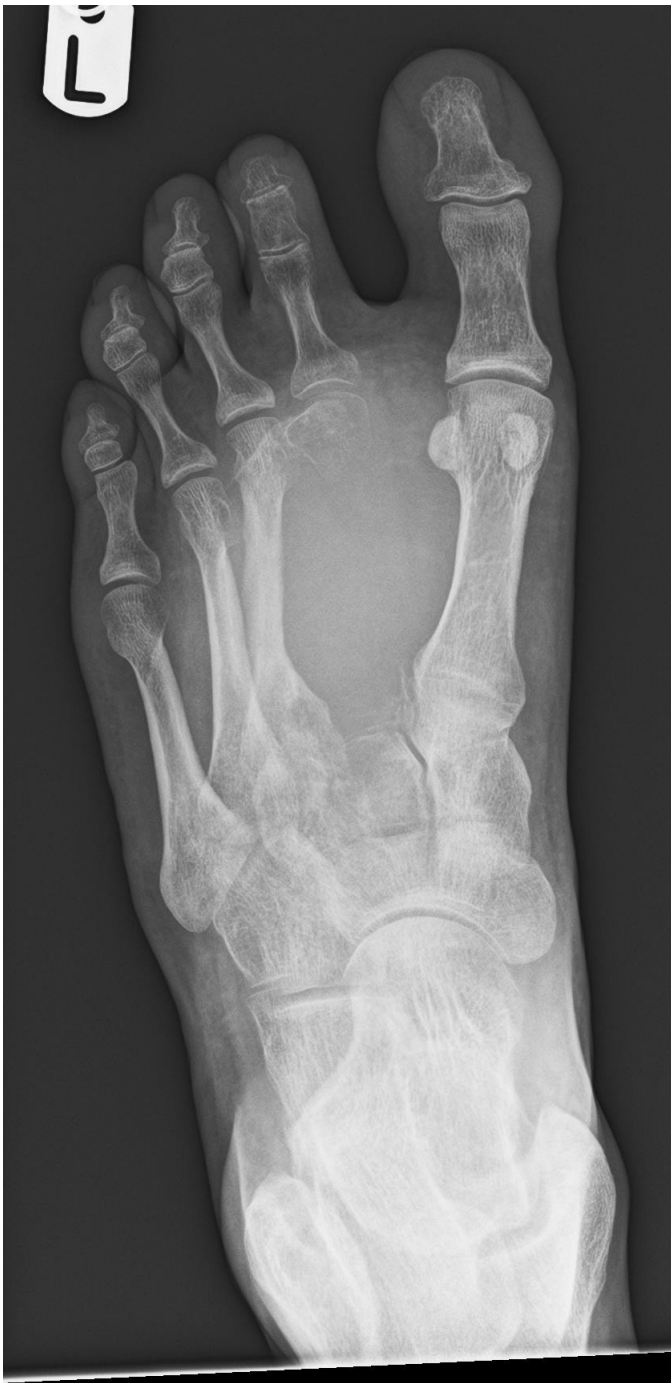


MICOD 27/09/2023

Case Courtesy: Dr. Harun Gupta (@mskteachingroom)





History: 52-year-old gentleman presented with swelling of fore-foot



