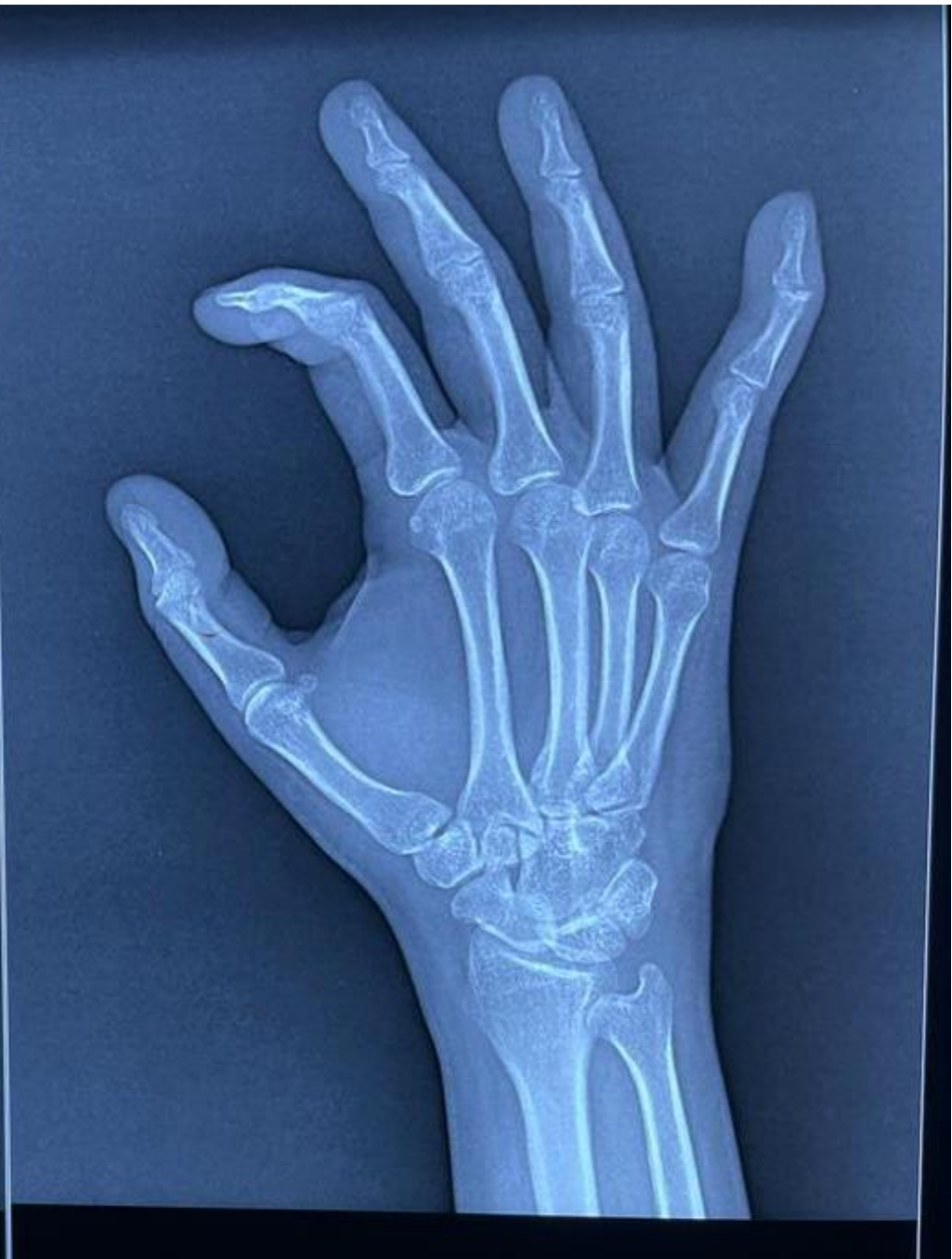
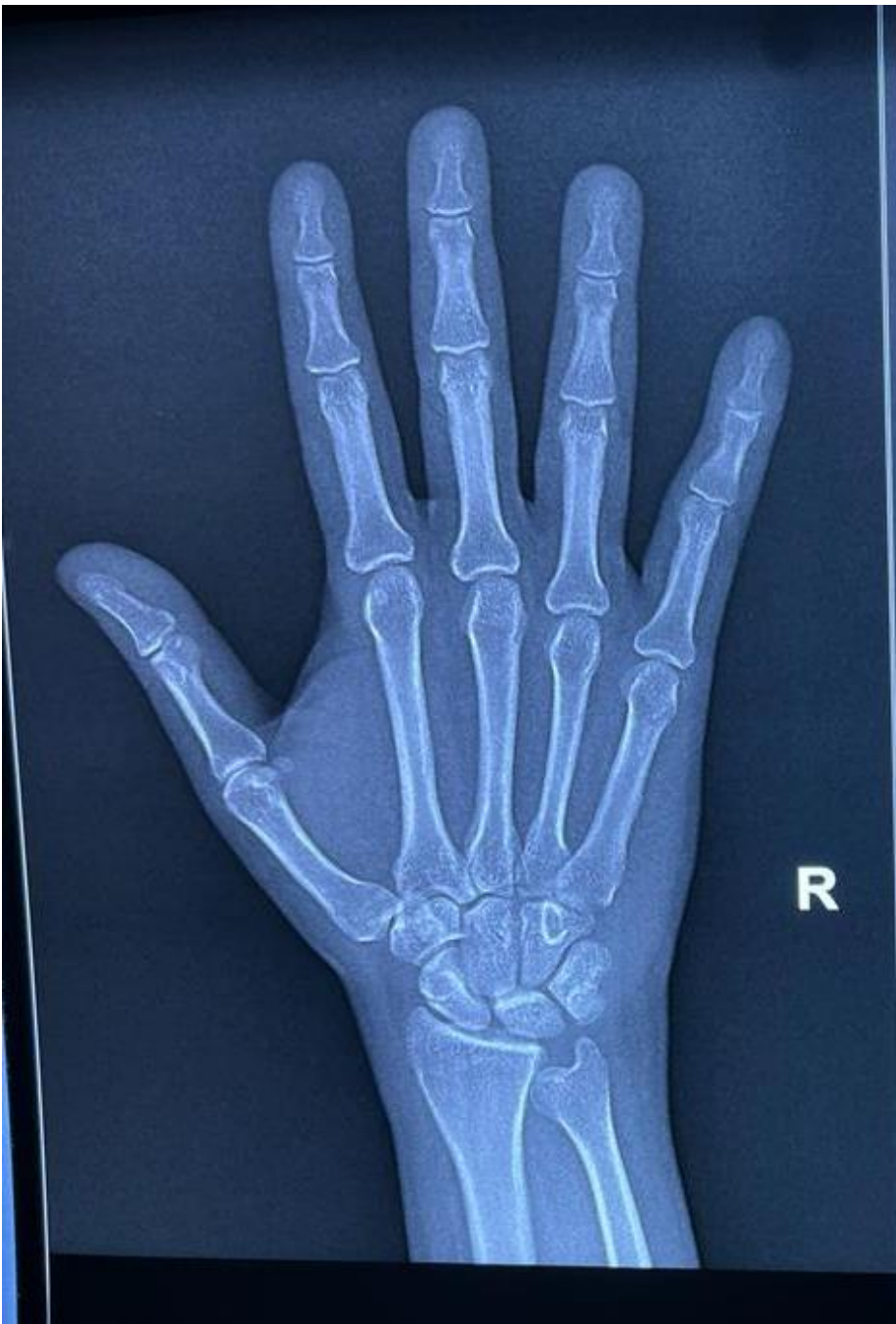

MICOD 25/09/2023

Case Courtesy: Dr. Nishith Kumar (Safdarjung Hospital)



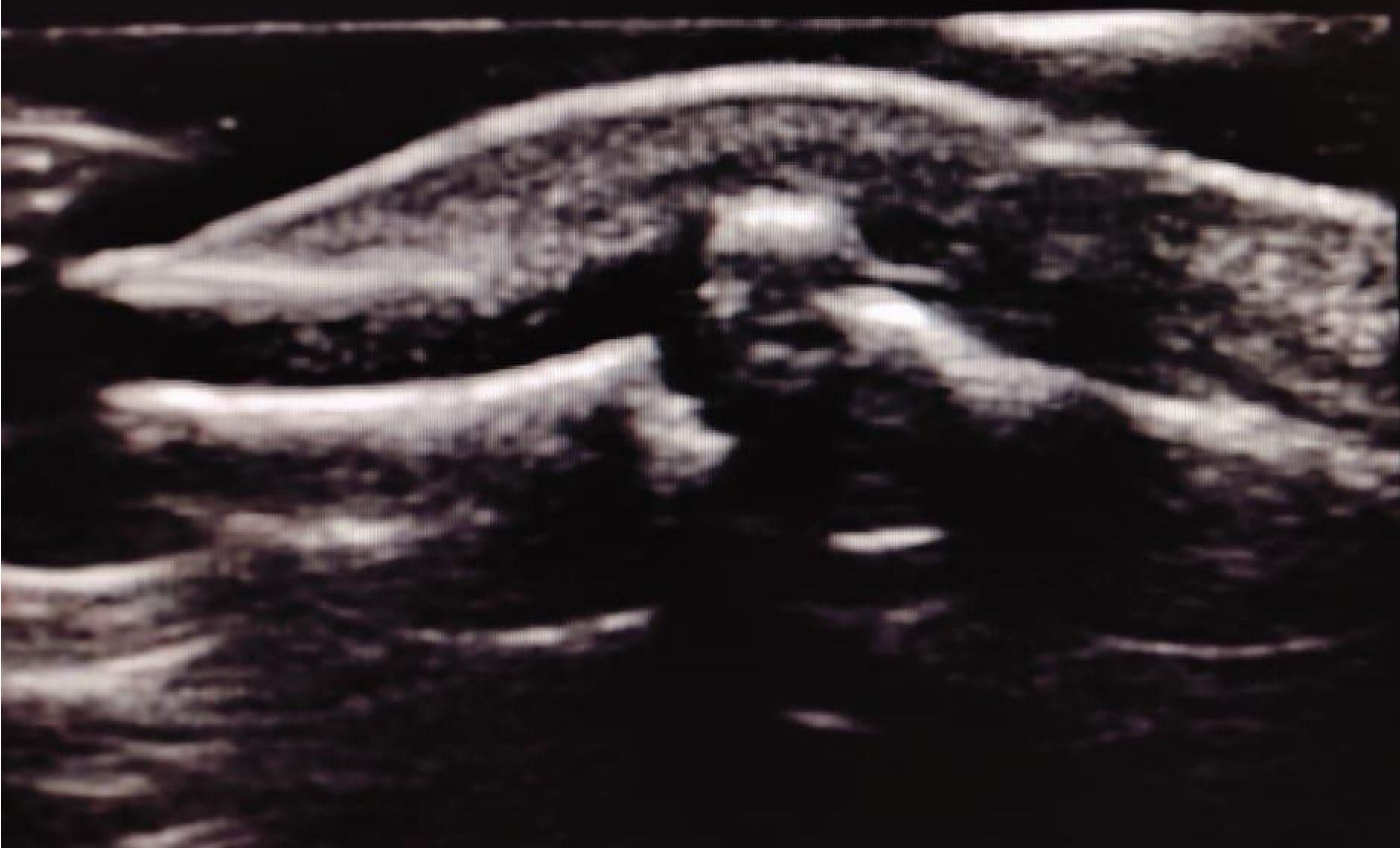

ER

SJHOSP


2023 Sep 25

11:04



Msk

HSL




93%

MI

0.7

TIS

0.2



100

What is your diagnosis?

- a) Sagittal band tear
- b) Mallet finger
- c) Calcified Hemangioma
- d) Foreign body