

MICOD – 23/09/2023

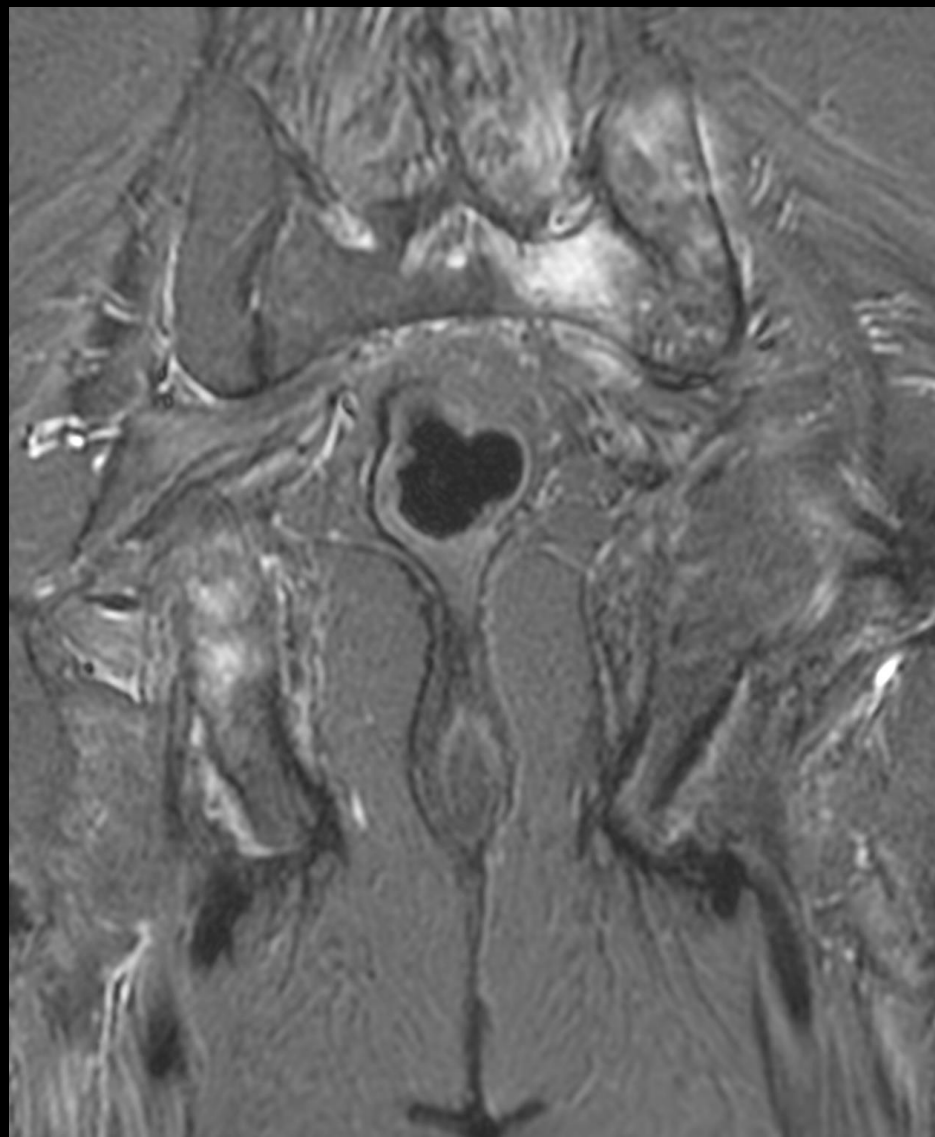
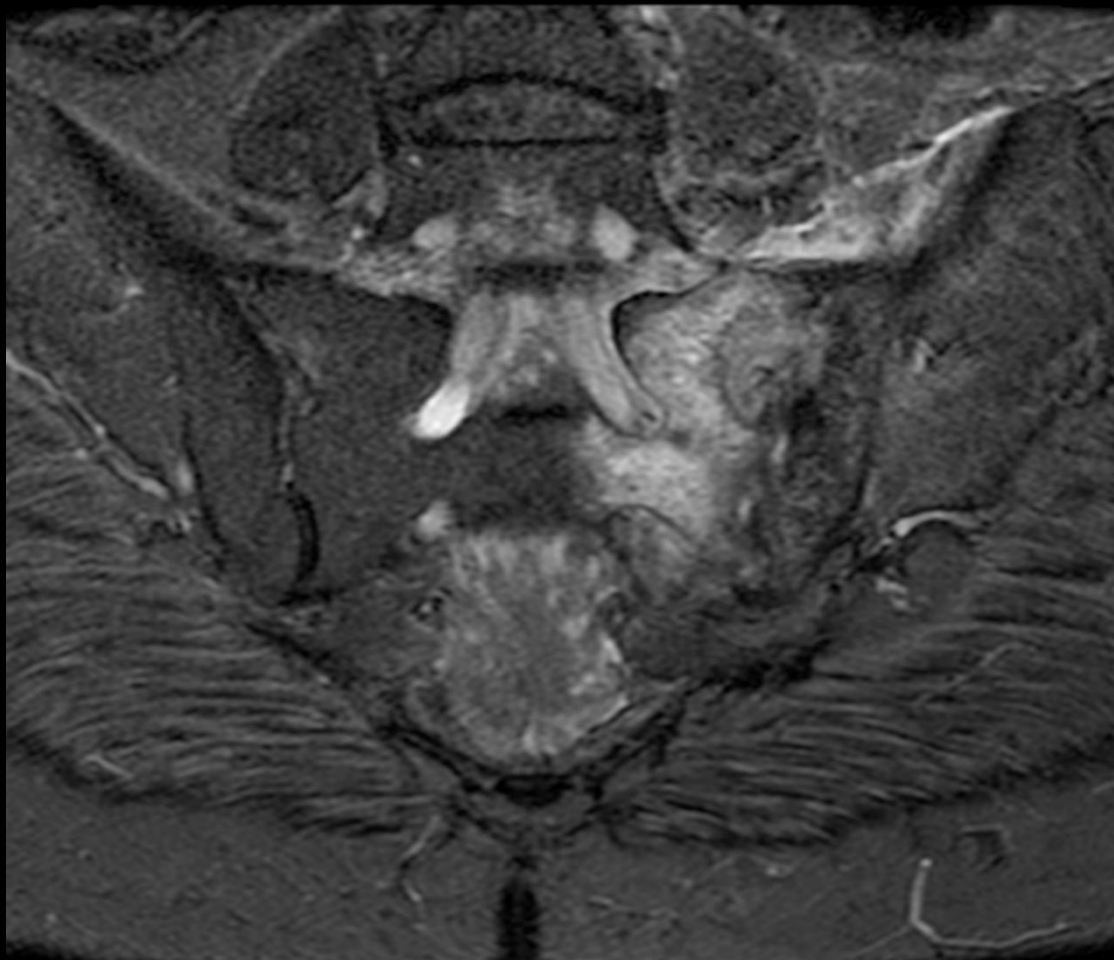
Case contributor – Dr. Chinmay P. Mehta

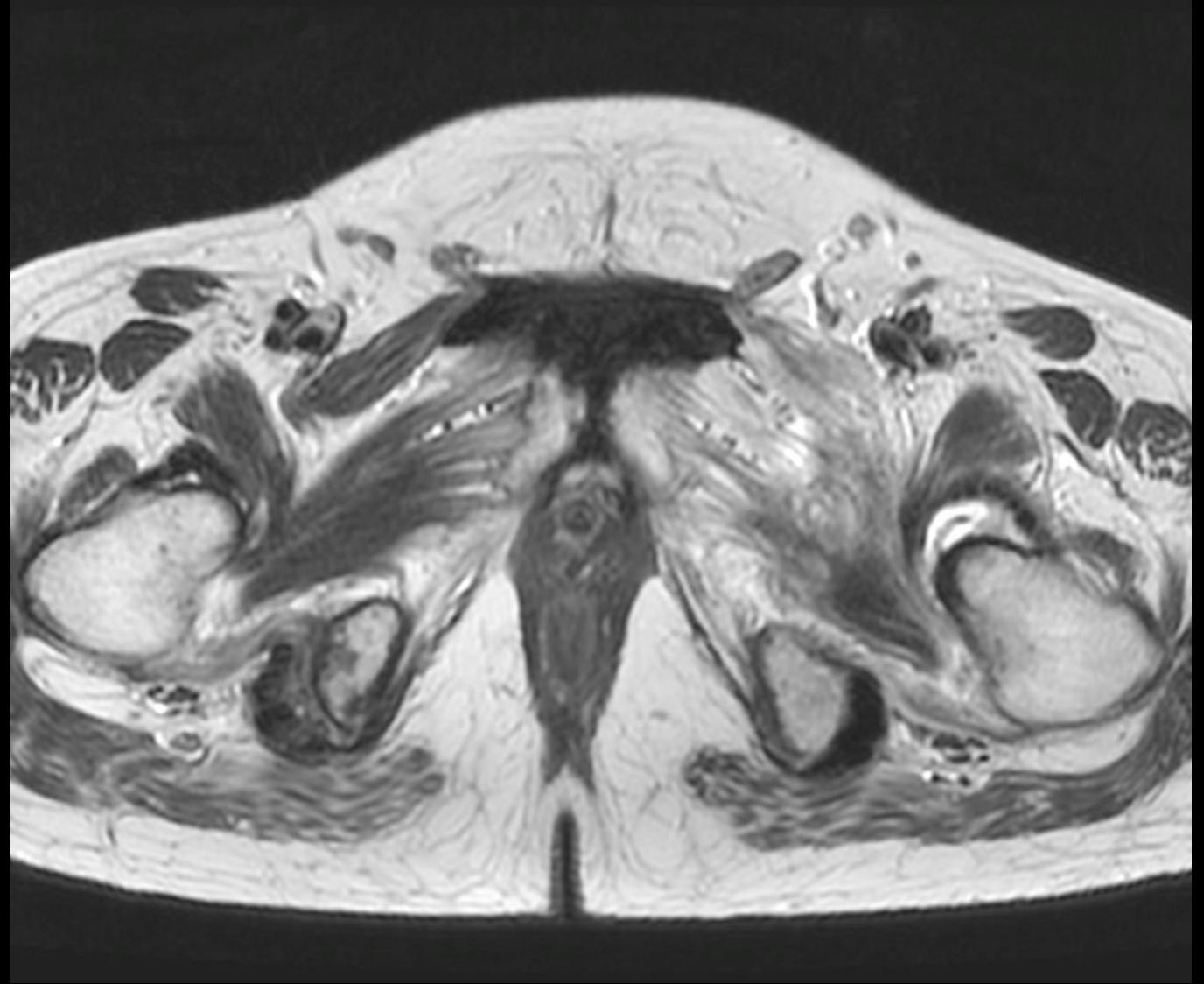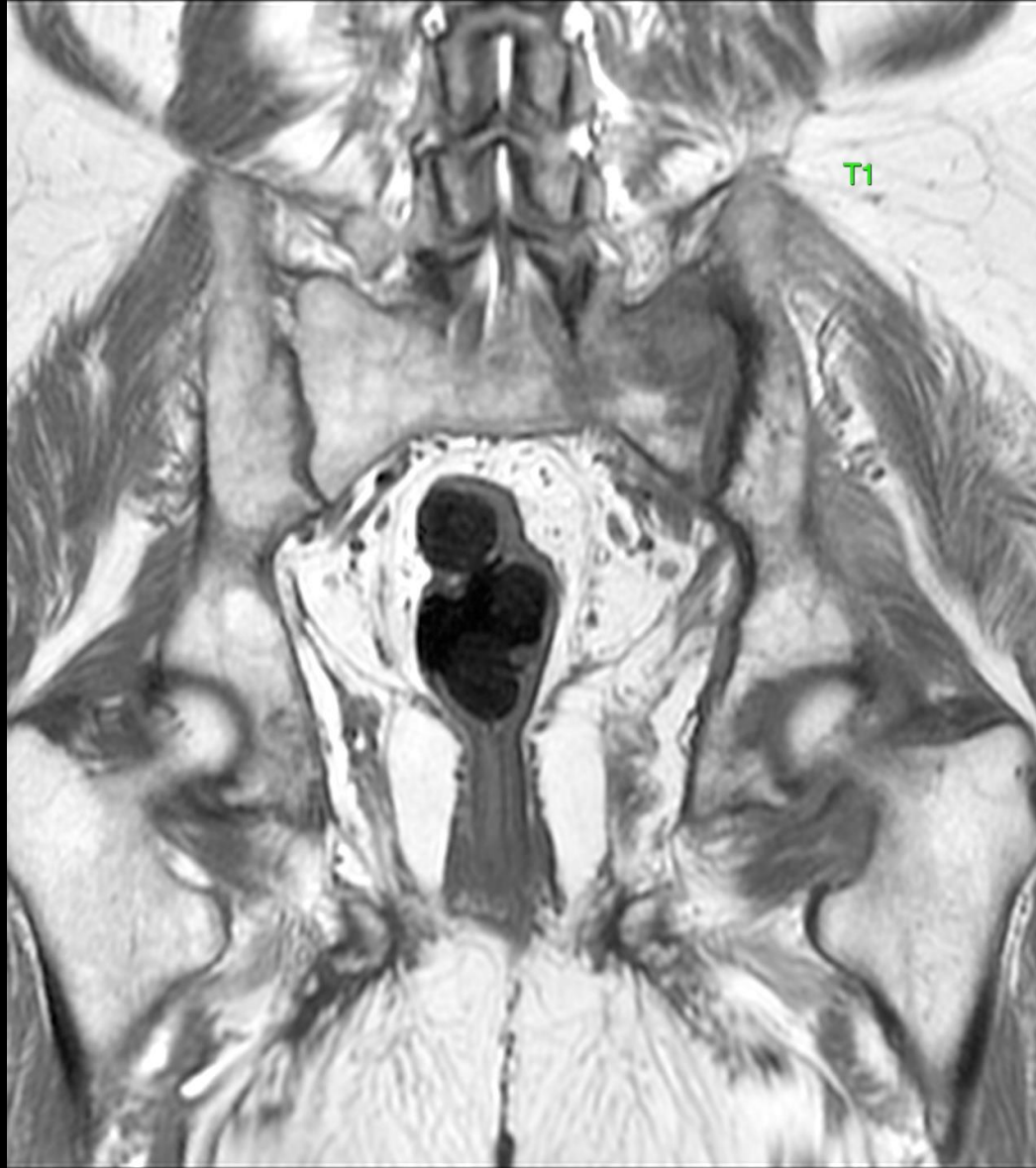# MI-COD

MSS INDIA- Case Of the Day

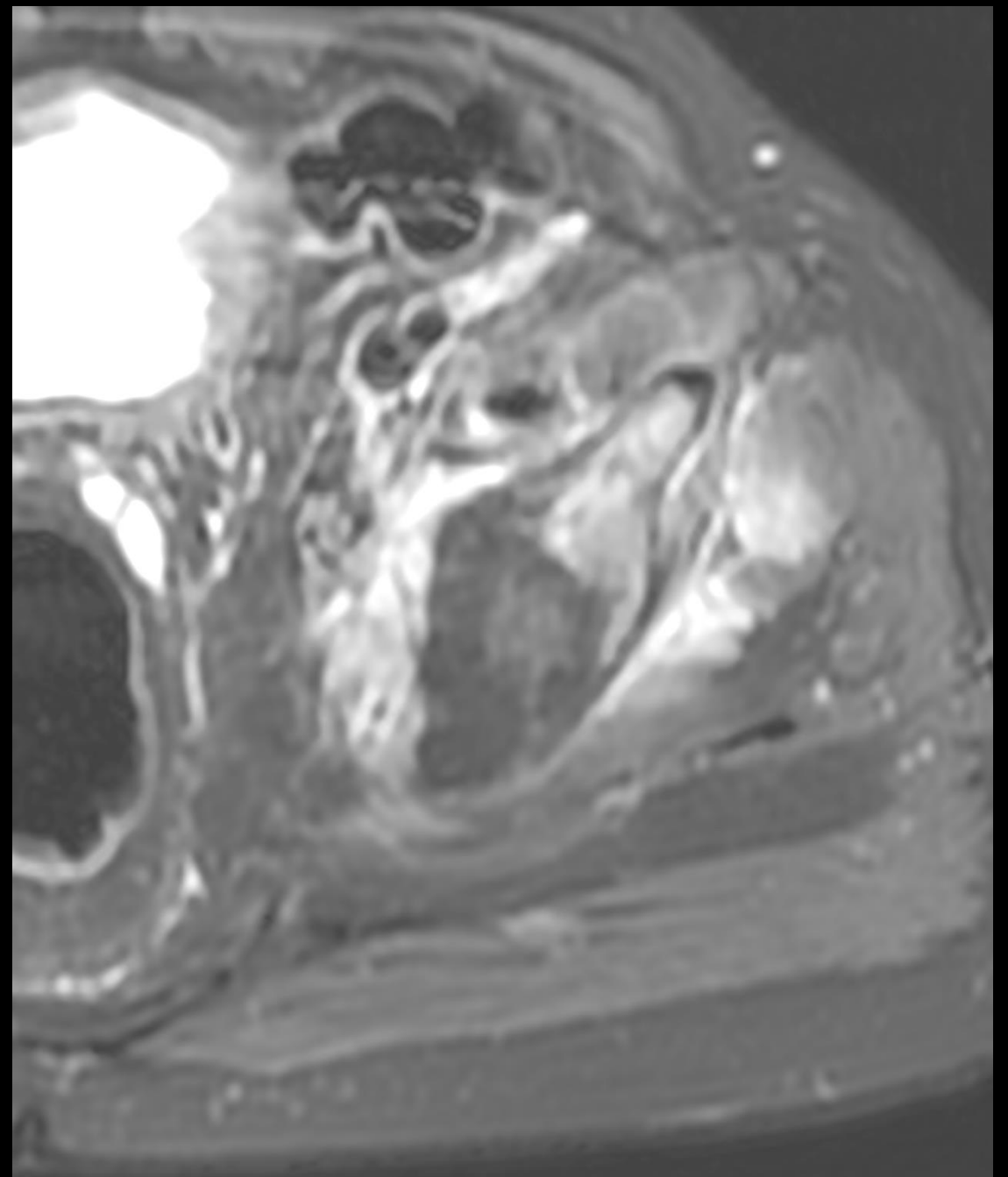
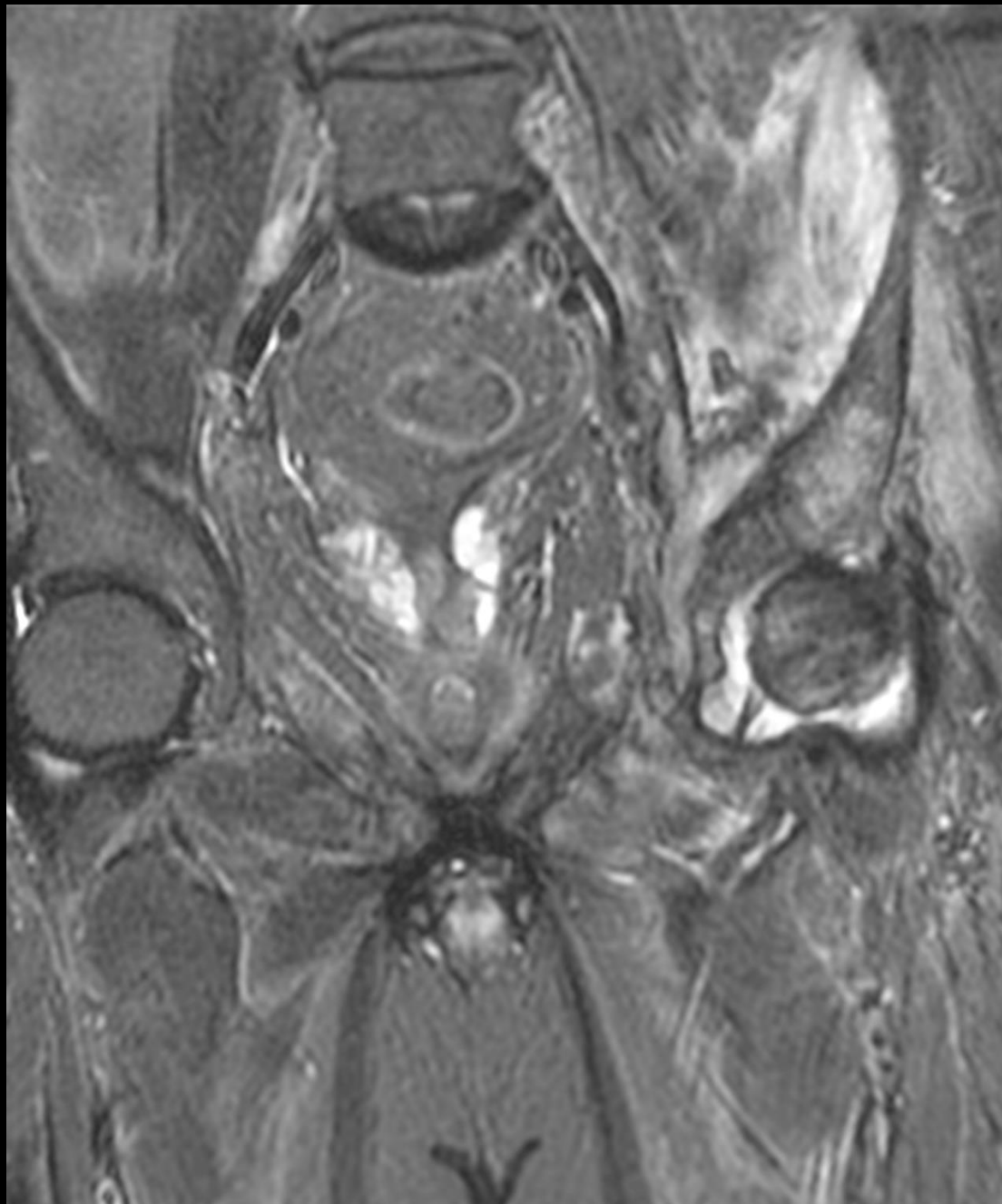


63 yr. old hypertensive and diabetic patient  
with left hip pain.









1. What is the likely etiology ?
  - a. Inflammatory
  - b. Infective
  - c. Neoplastic
  - d. Loser's zones.
2. Next step ?
  - a. Look up the infective and tumor markers
  - b. Biopsy and microbiological and histopathology analysis
  - c. Both of the above.
  - d. Dexa for osteoporosis.
3. If biopsy was performed, what are tests one should order ?