
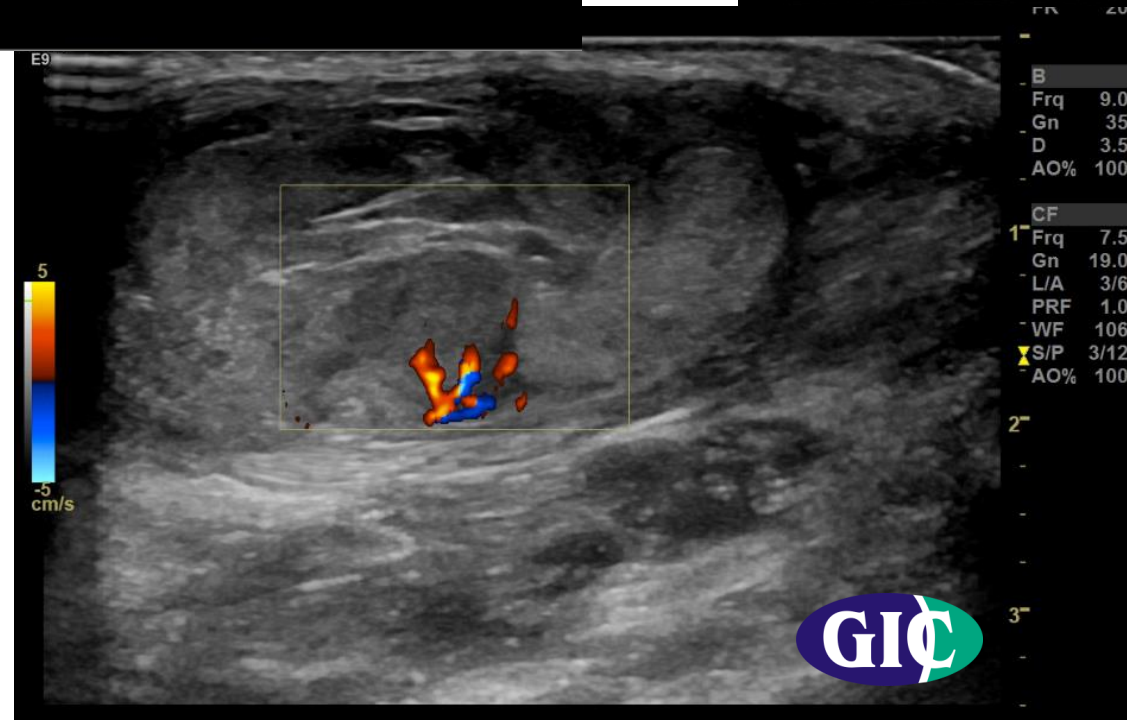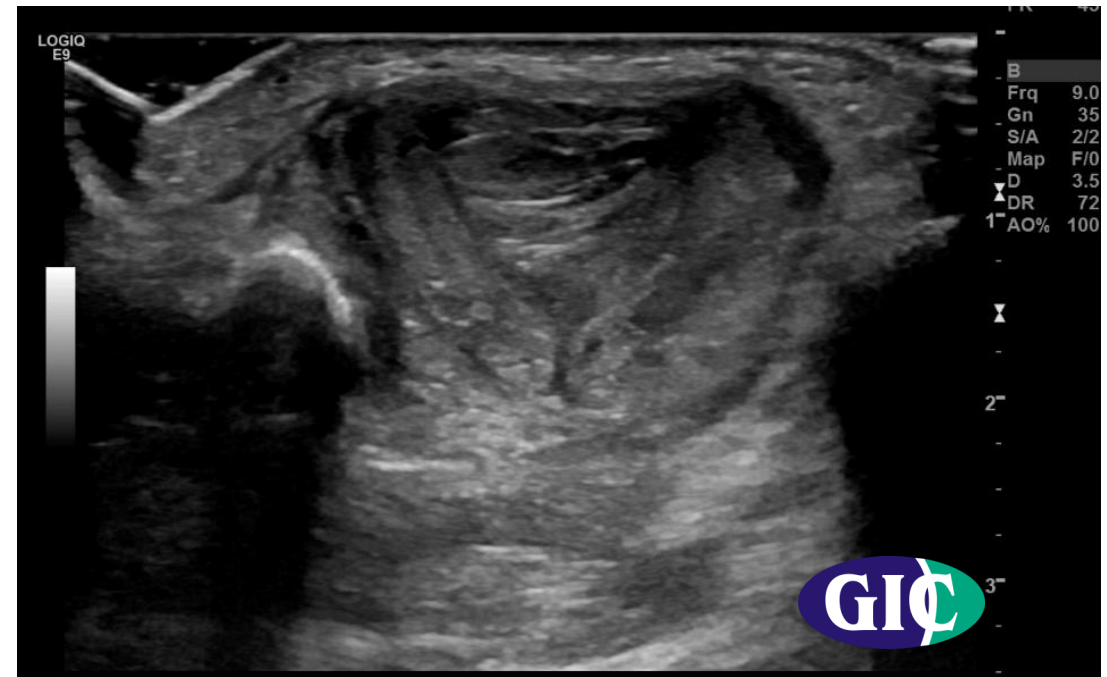
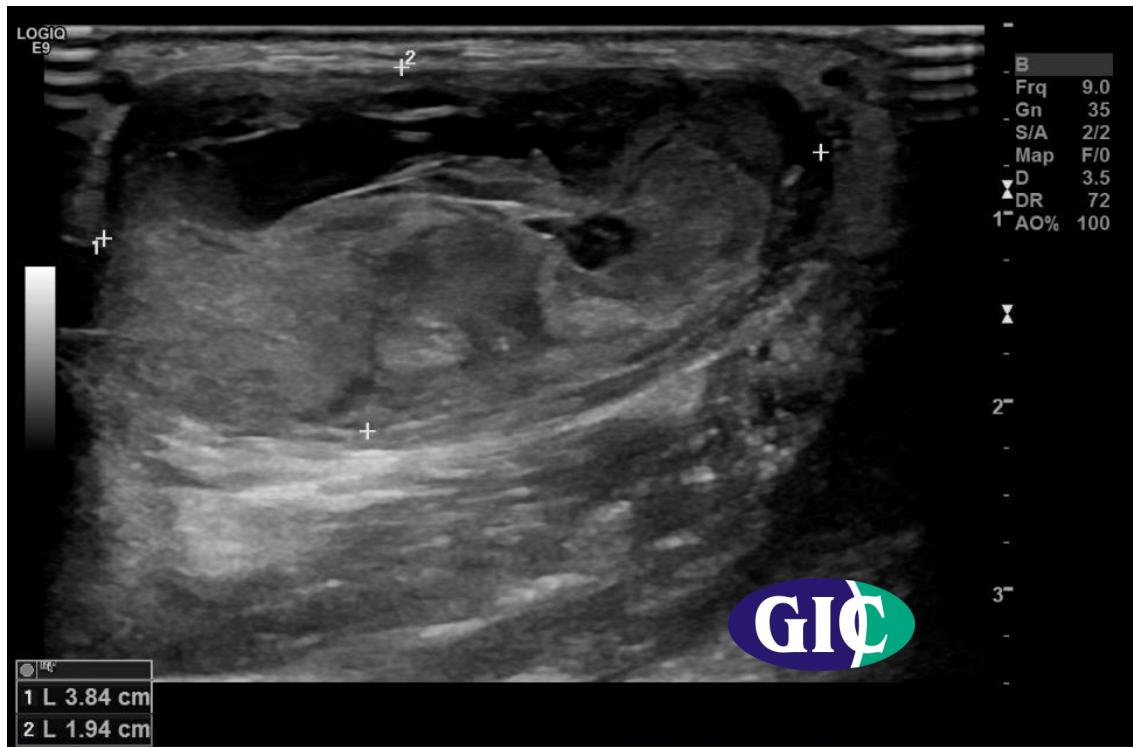


**MICOD 22/09/2023**  
**Case Courtesy: Dr. Drushi Patel**

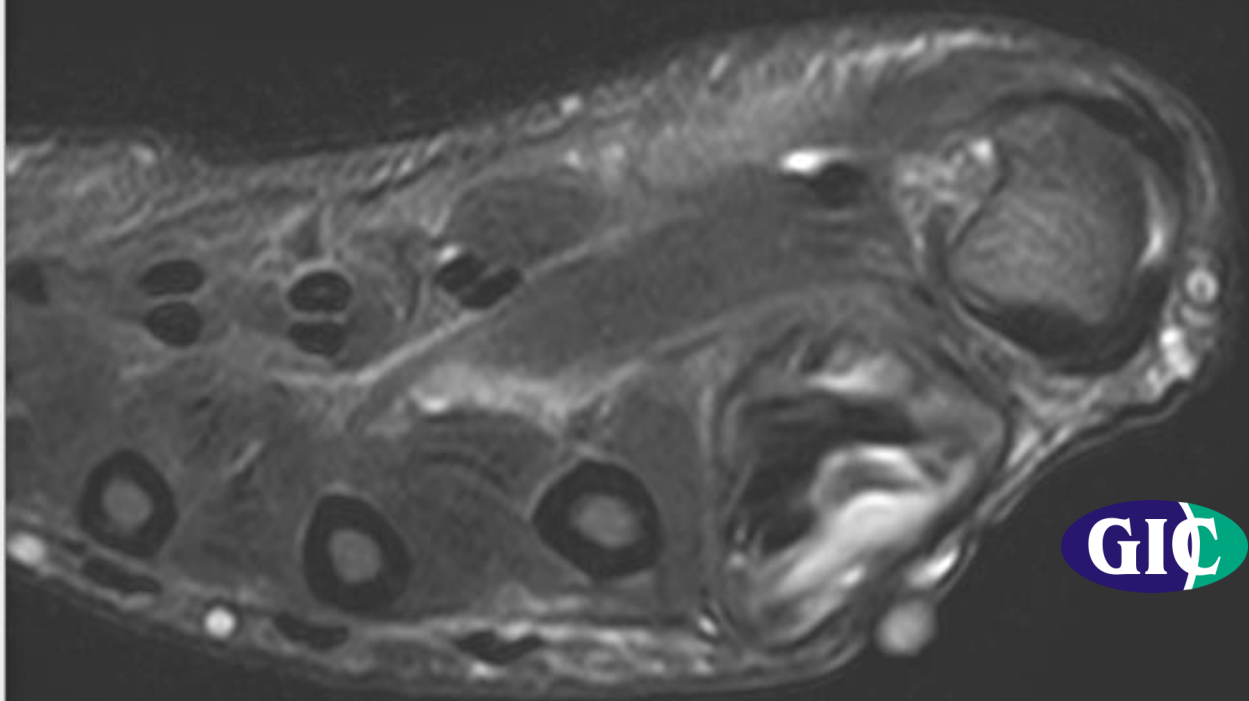


# Clinical presentation

- 62 year old male presented with firm swelling in 1<sup>st</sup> web space and associated mild pain.
- No H/o Trauma, Major illness, Tb , weigh loss or surgery

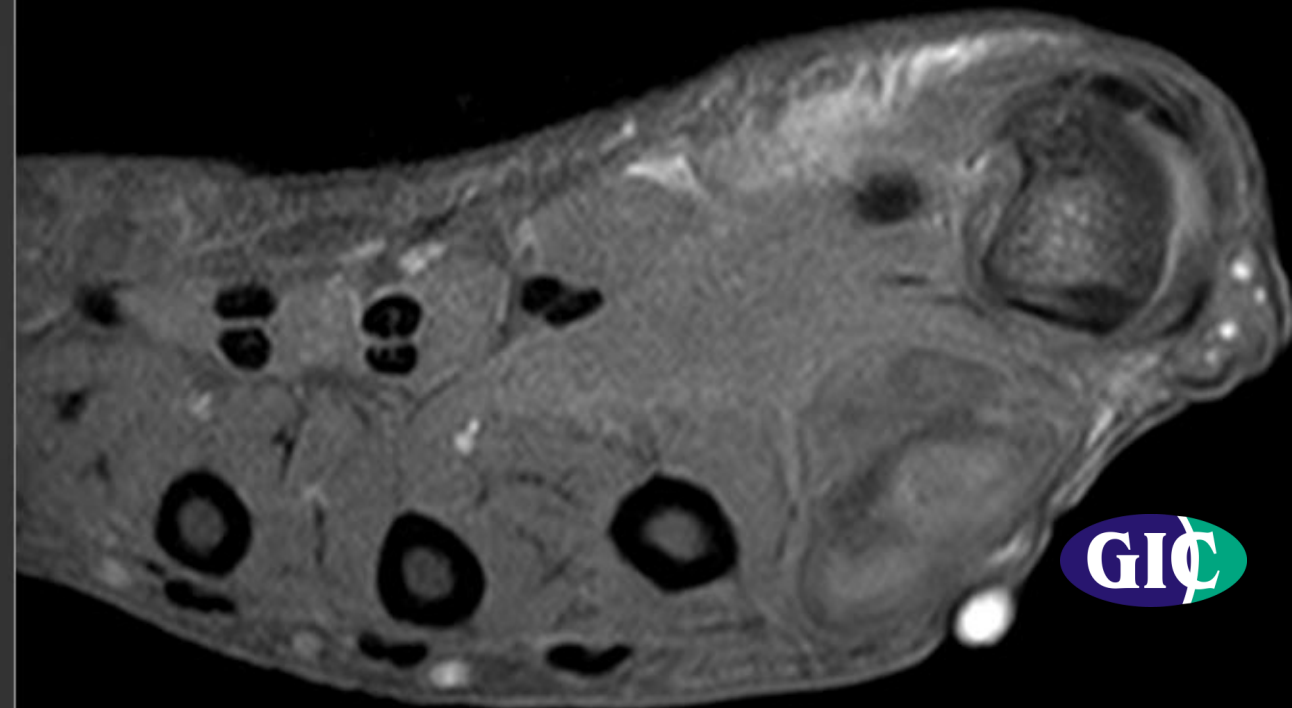


T2W

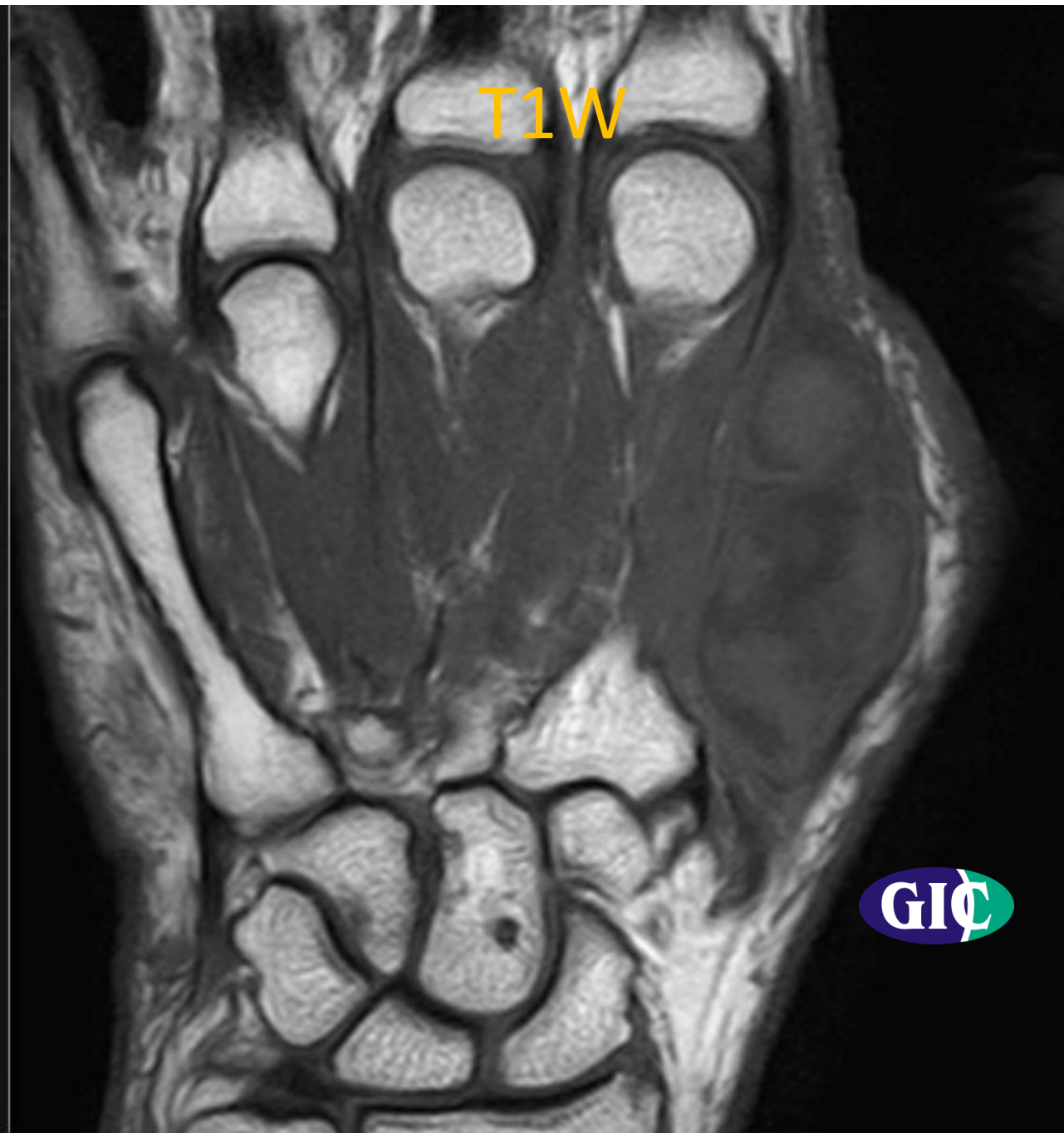
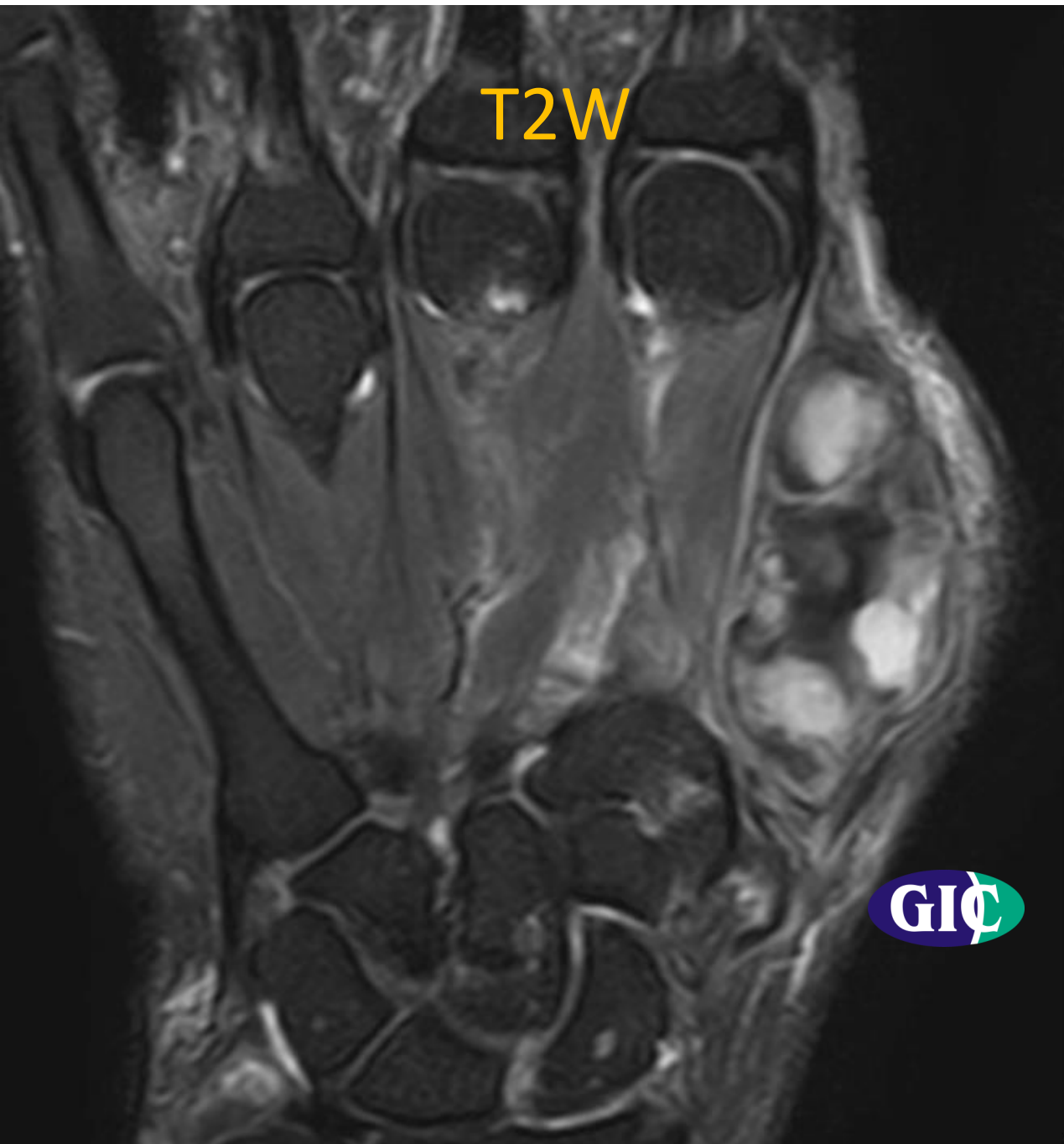

GIÇ

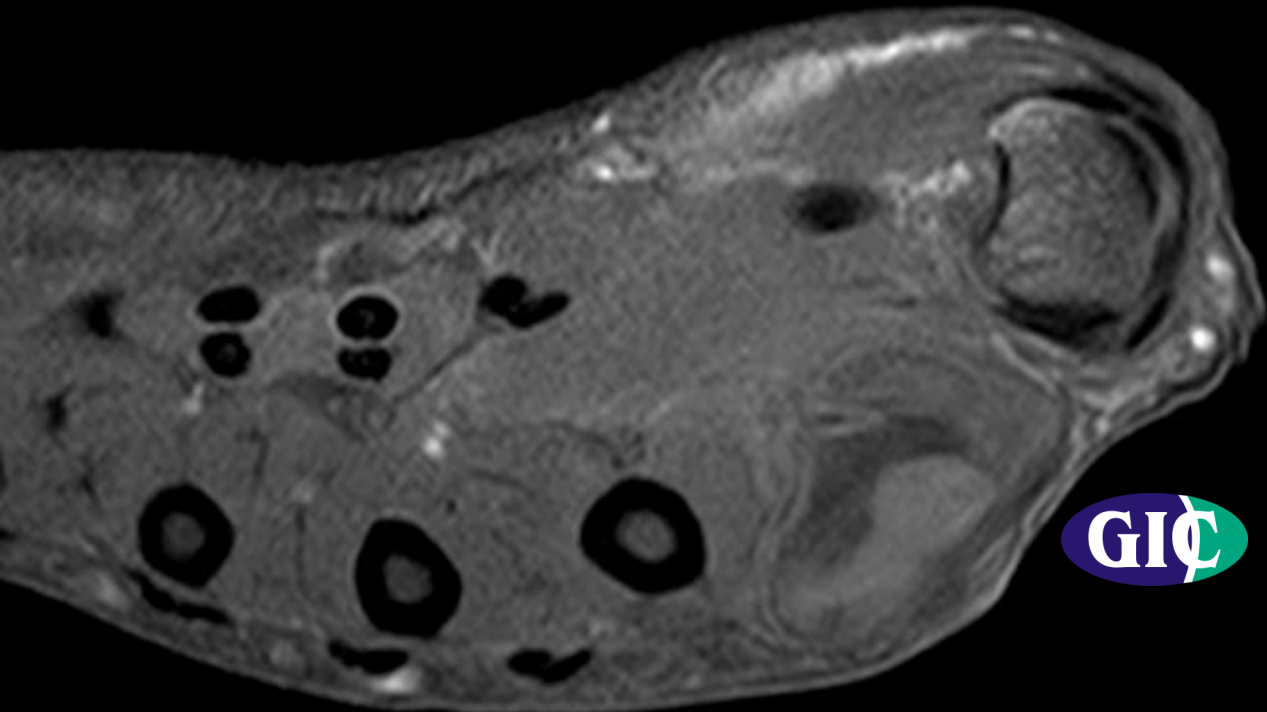
T1W



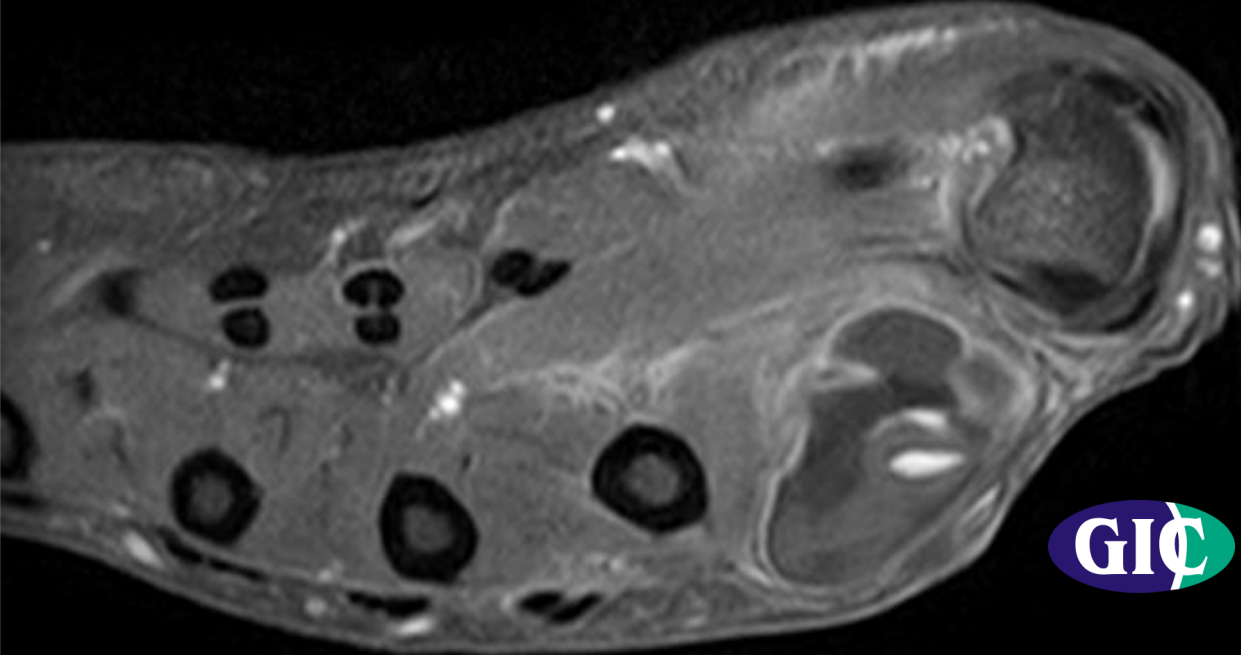
GIÇ



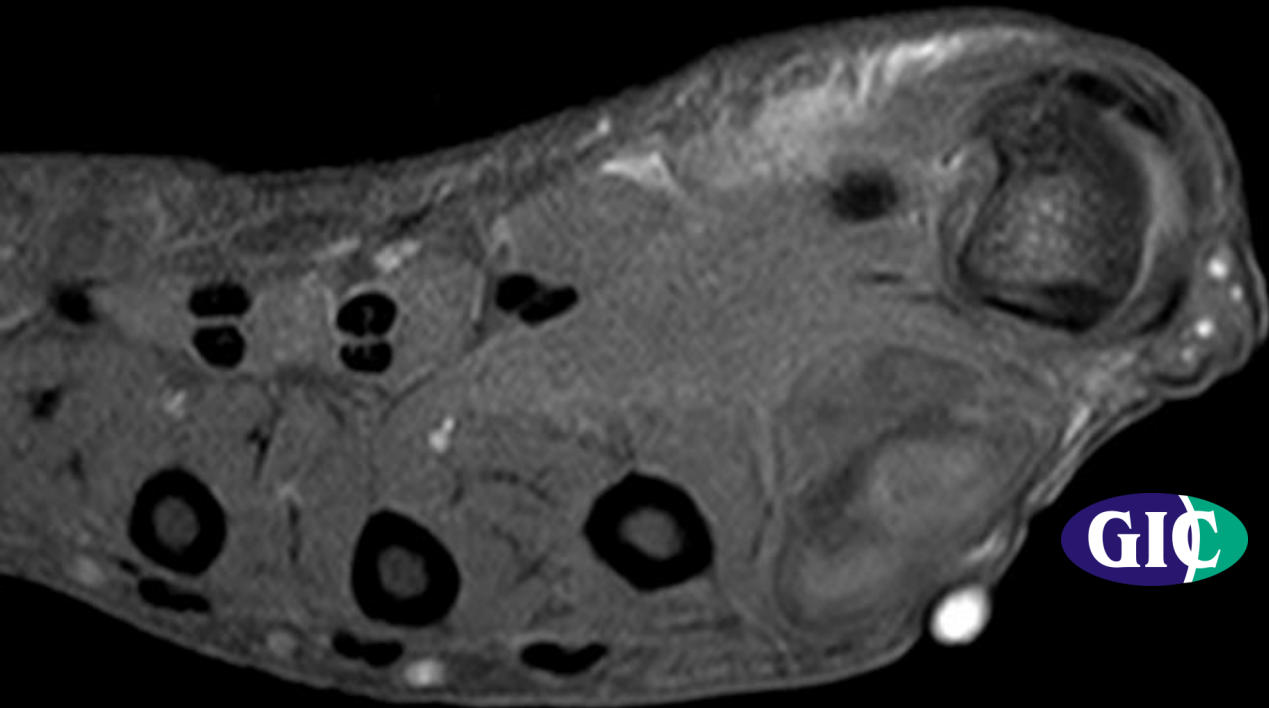
Pre contrast



Post contrast

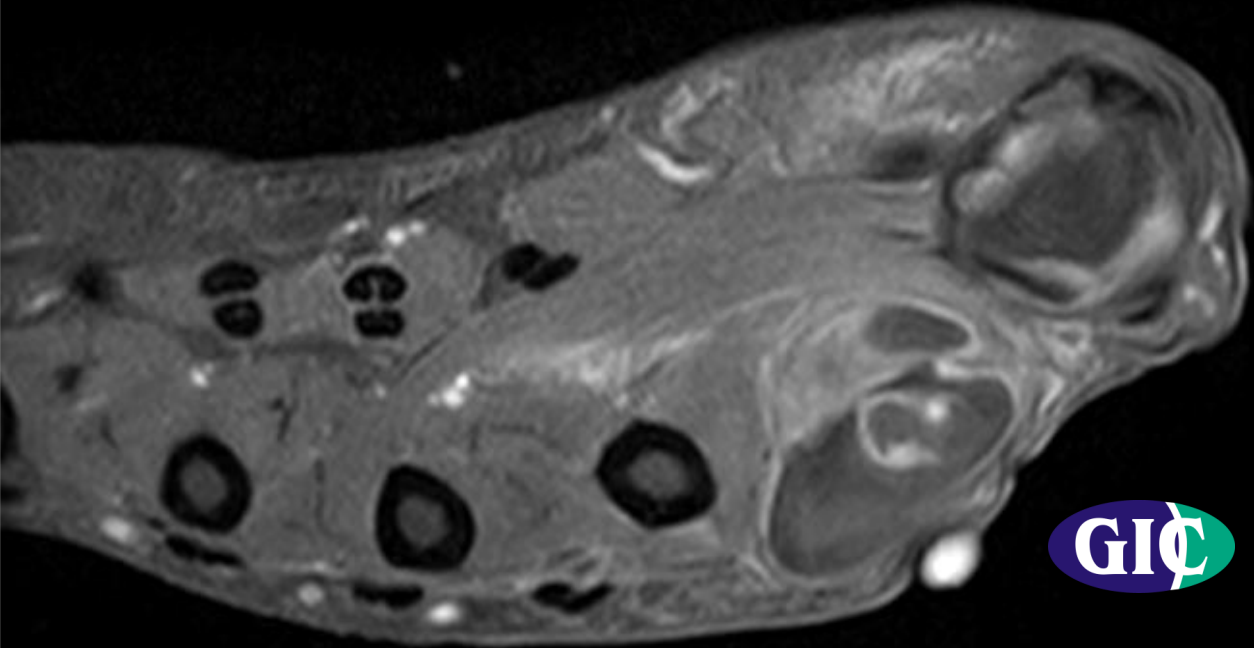


Pre contrast



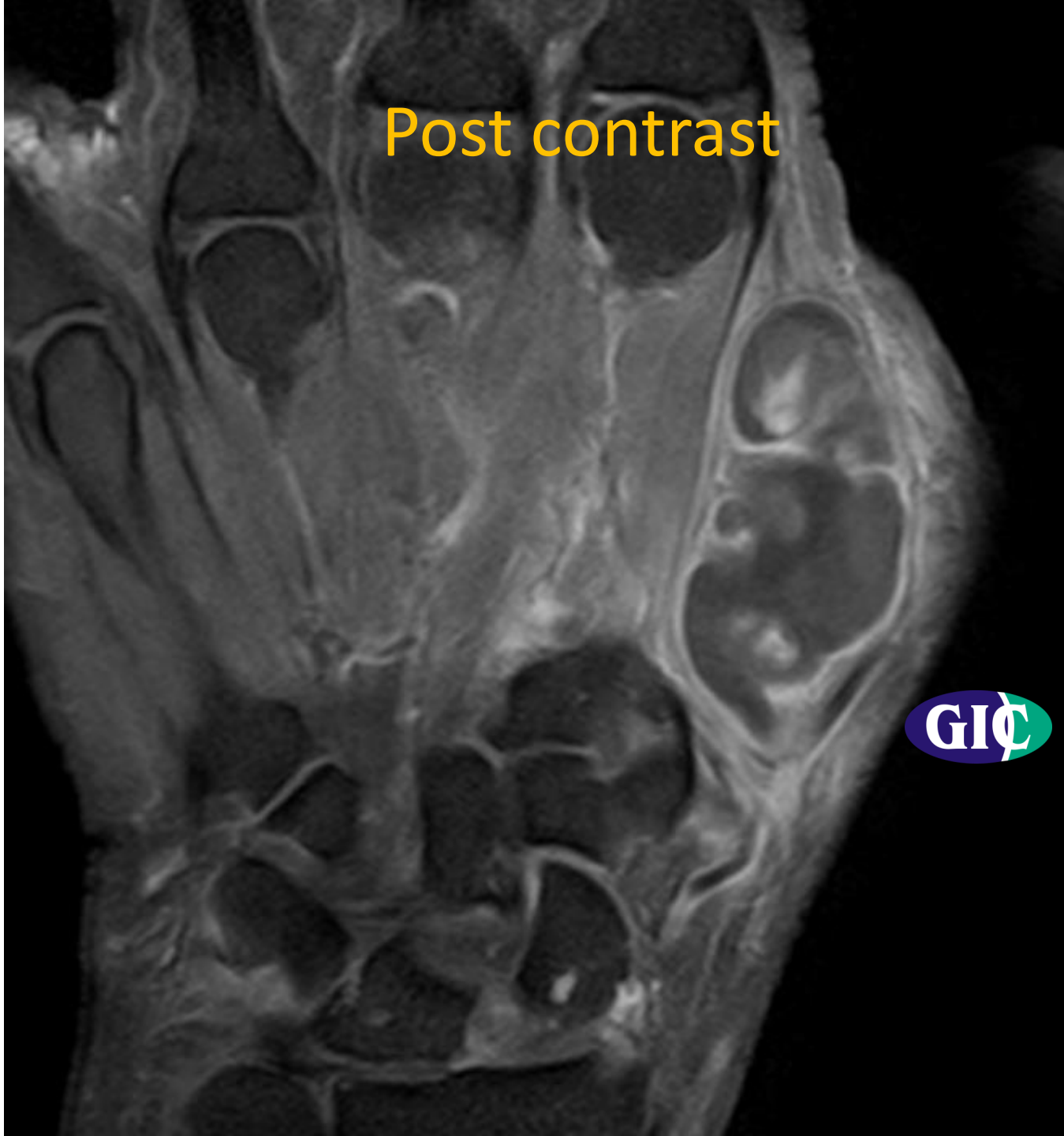GIÇ

Post contrast



GIÇ

Post contrast



Post contrast

