

Date: 20.09.2023

Case Courtesy: Dr. Drushi Patel



MI-COD

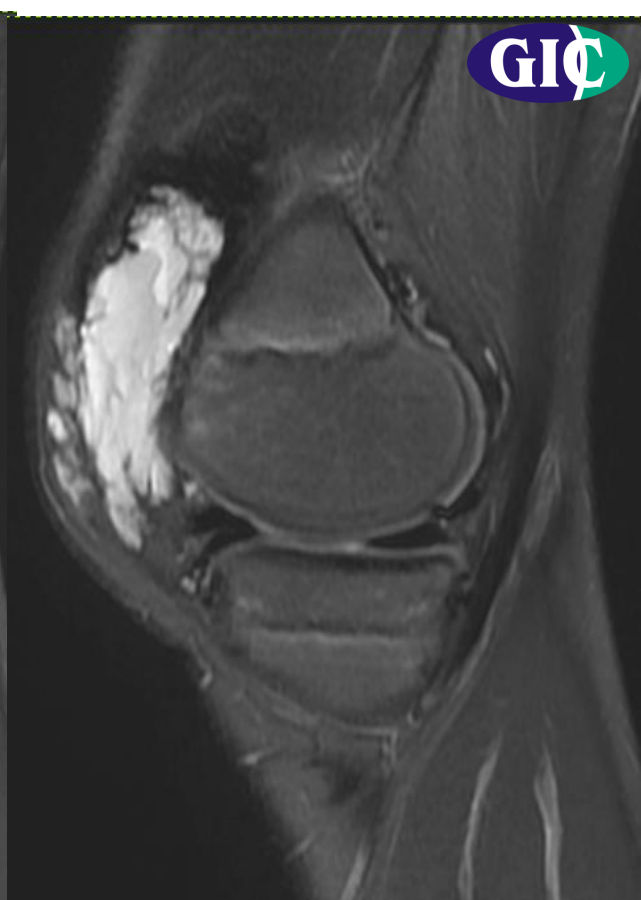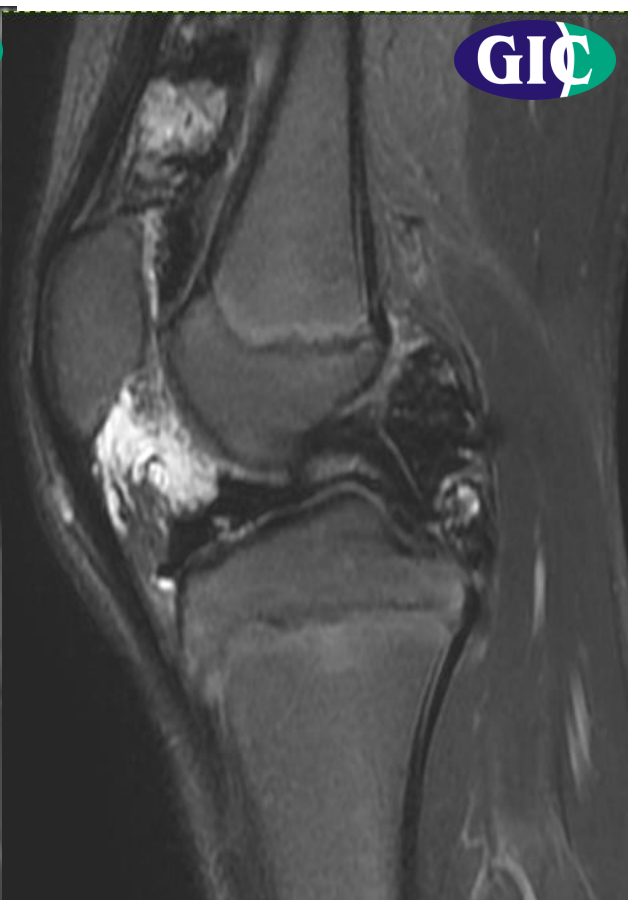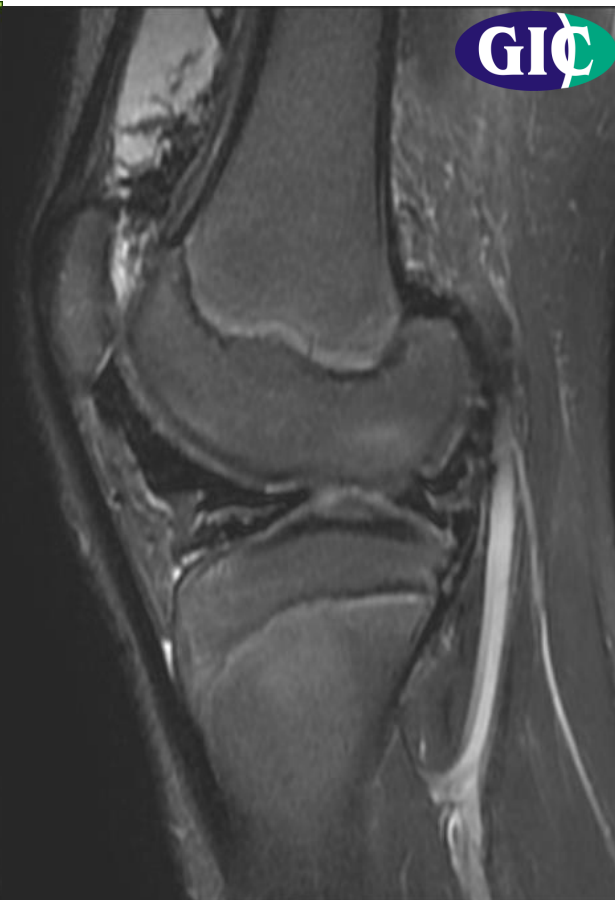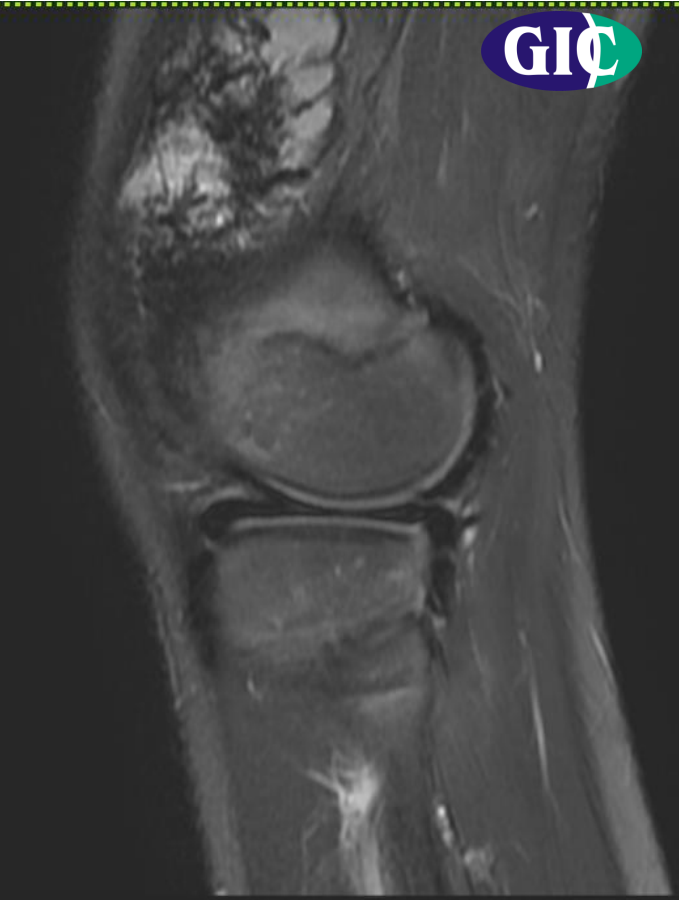MSS INDIA- Case Of the Day

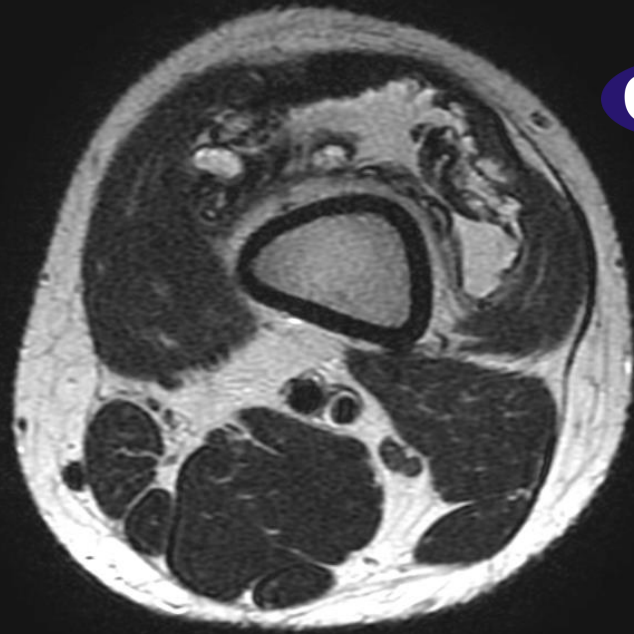


Clinical presentation

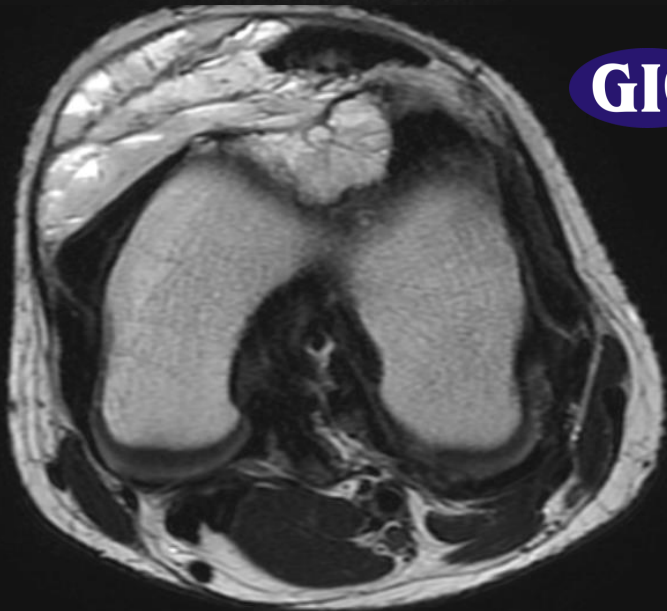
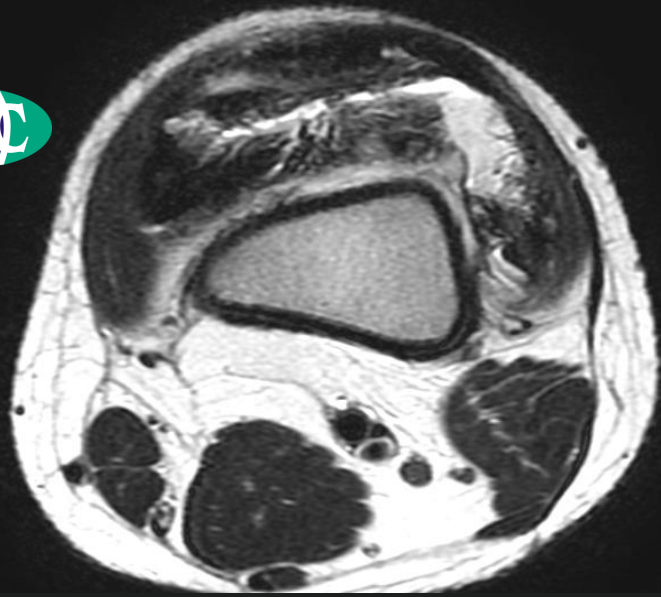
12 year old football player noticed knee pain and swelling
since a week







GIC



GIC

