

Date: 18.09.2023

Case Courtesy: Dr. Joban Babhulkar

MI-COD

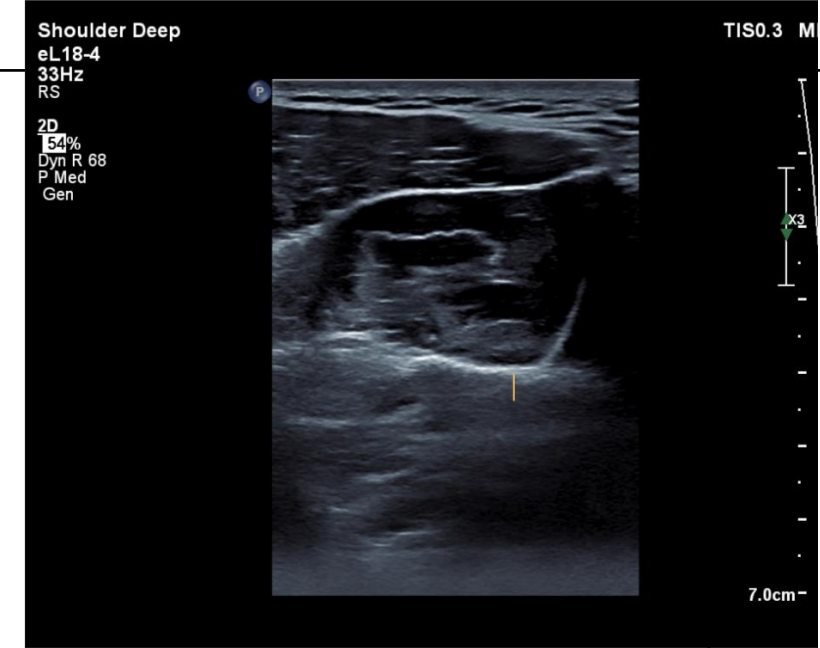
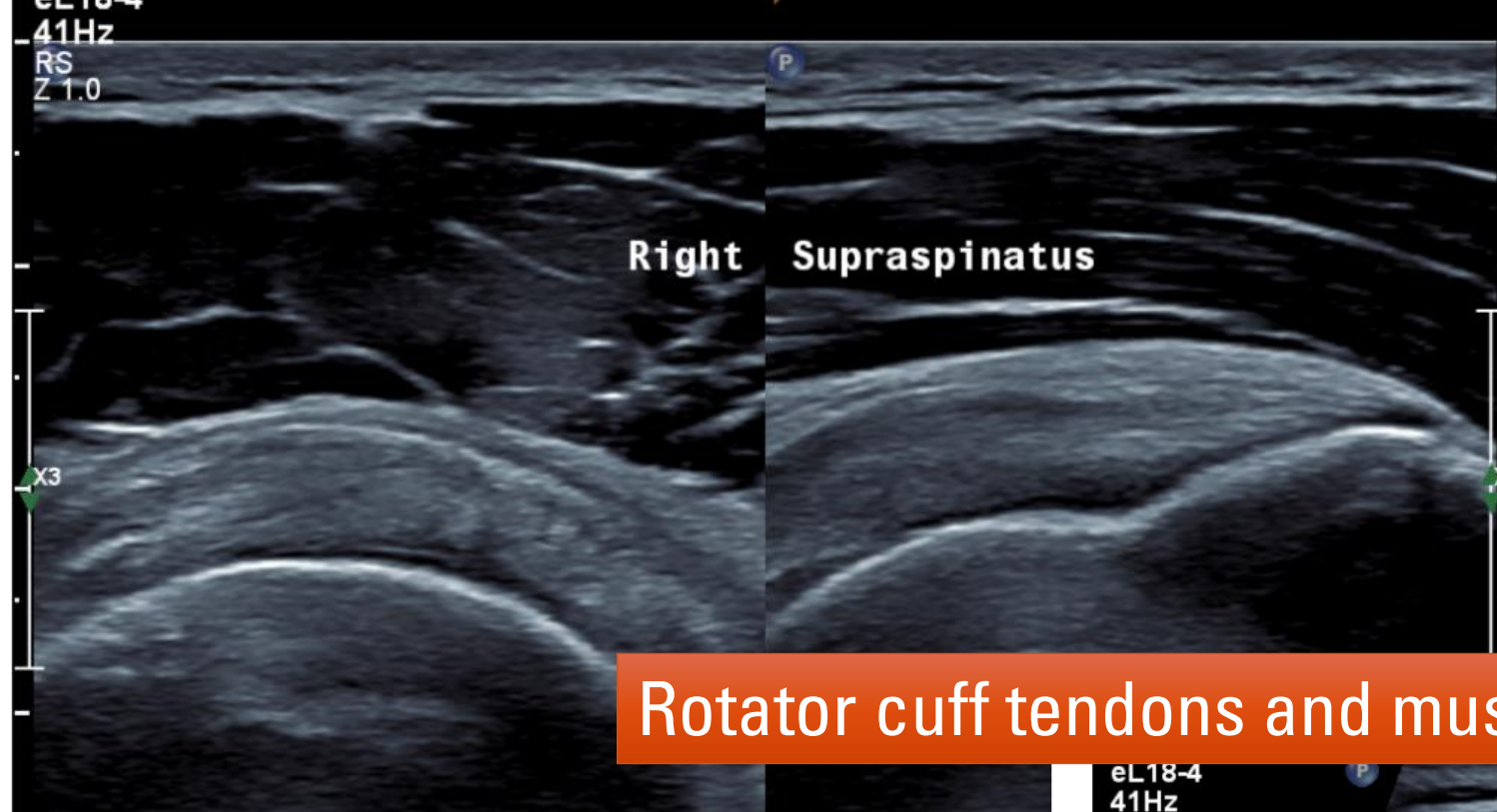
MSS INDIA- Case Of the Day



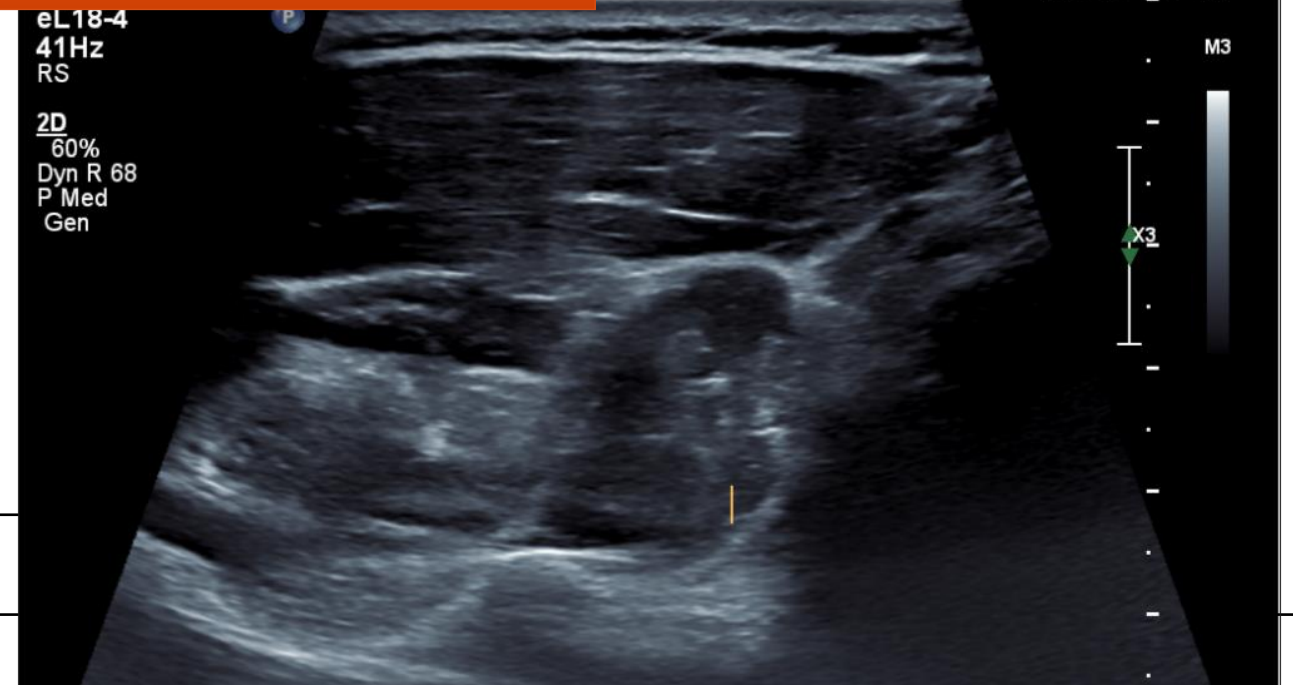
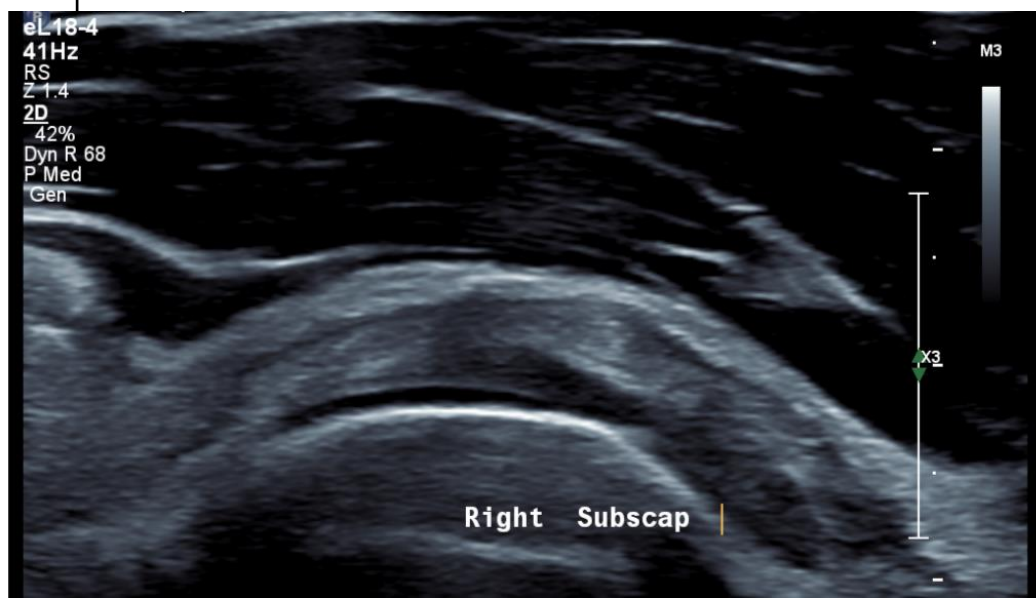
**25 y/o male cricketer felt
snap in axilla while bowling**

**No obvious ecchymosis /
haemorrhage**

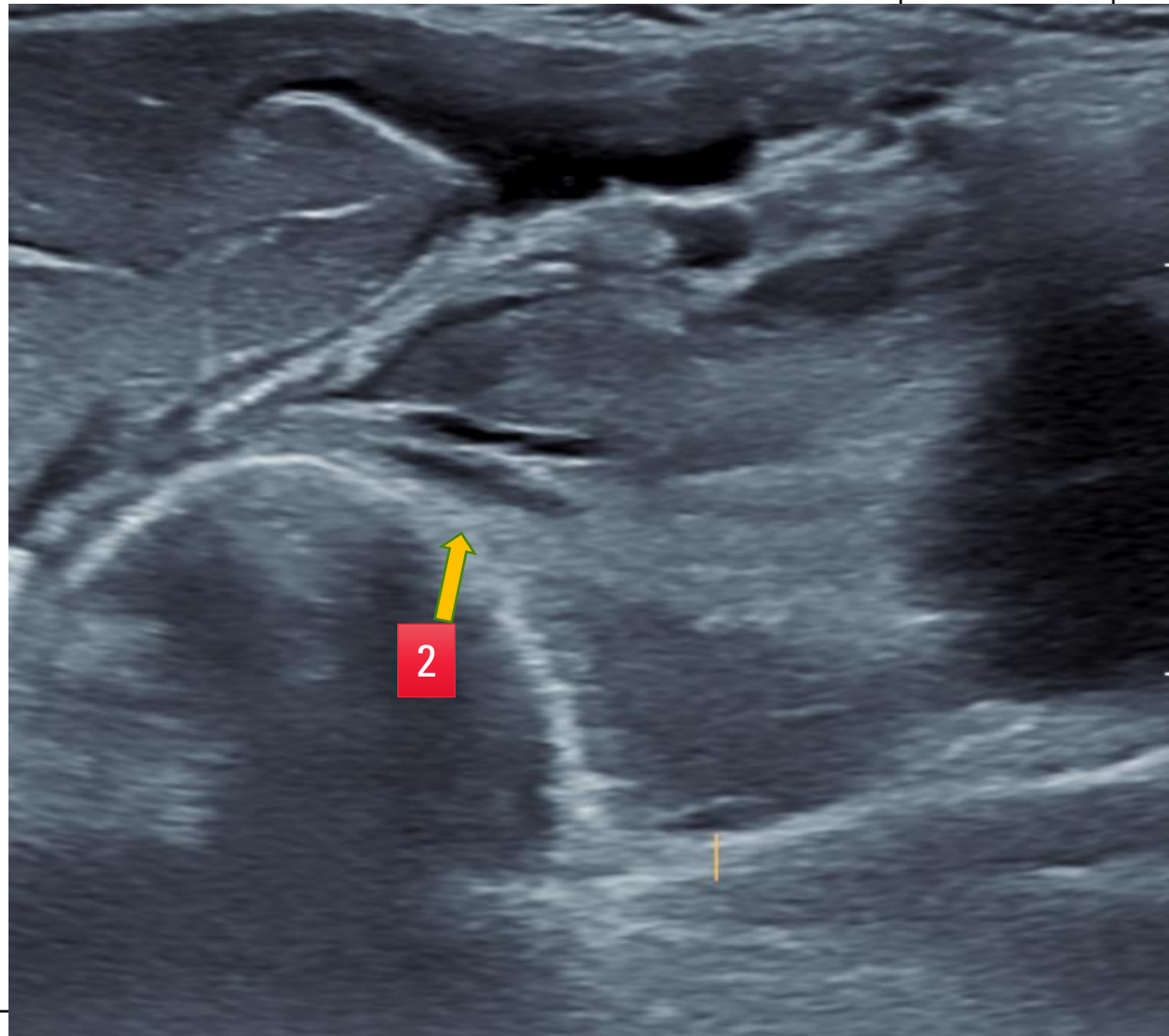
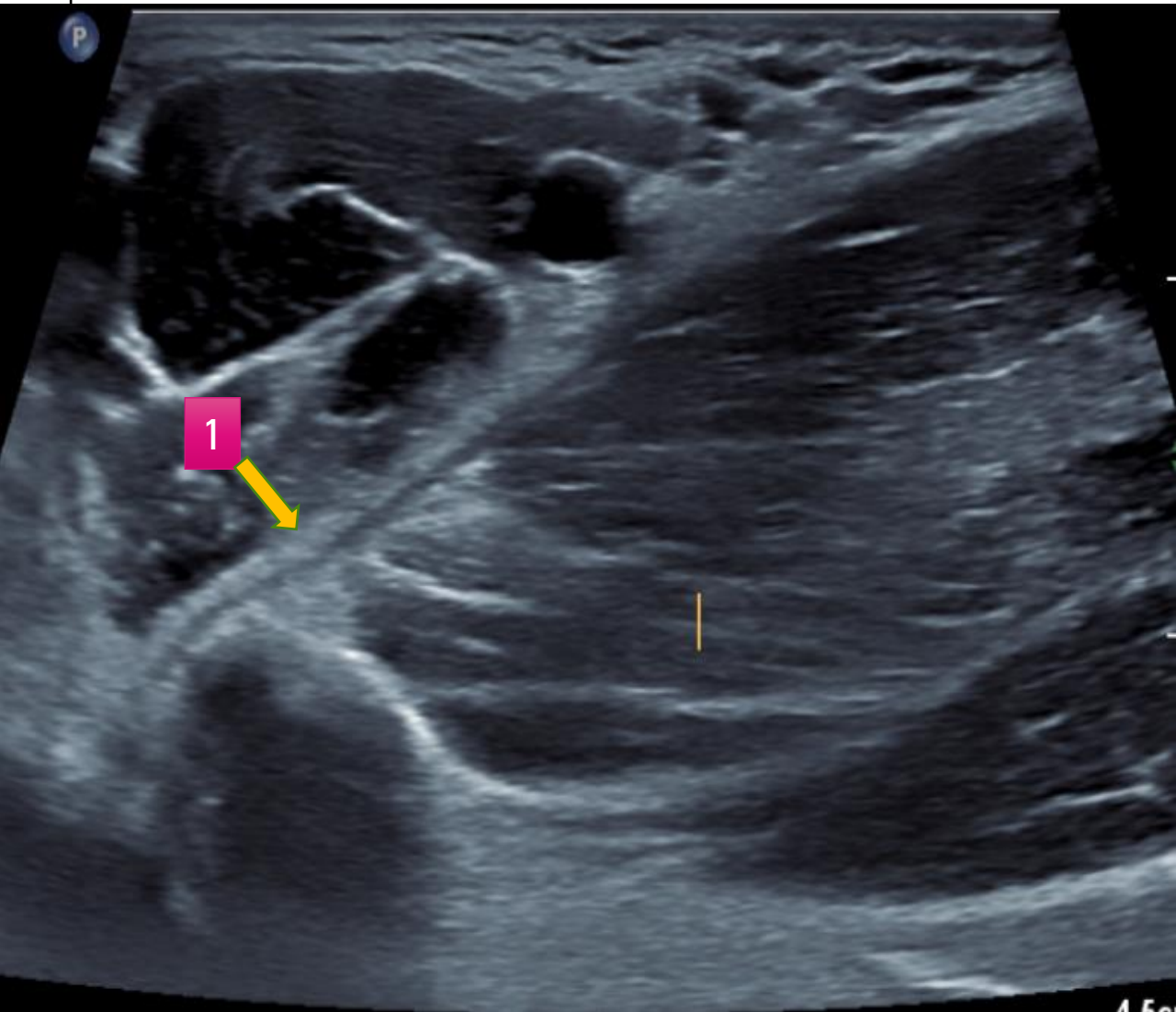
**Continued to have mild
pain in axilla when he was
sent for HRUS**



Rotator cuff tendons and muscles



Short axis thru anterior upper arm



Questions

- 1) What is " 1 " and " 2 "
- 2) What is likely diagnosis