


MICOD 16/09/2023
Contributor: Dr. D. K. Singh

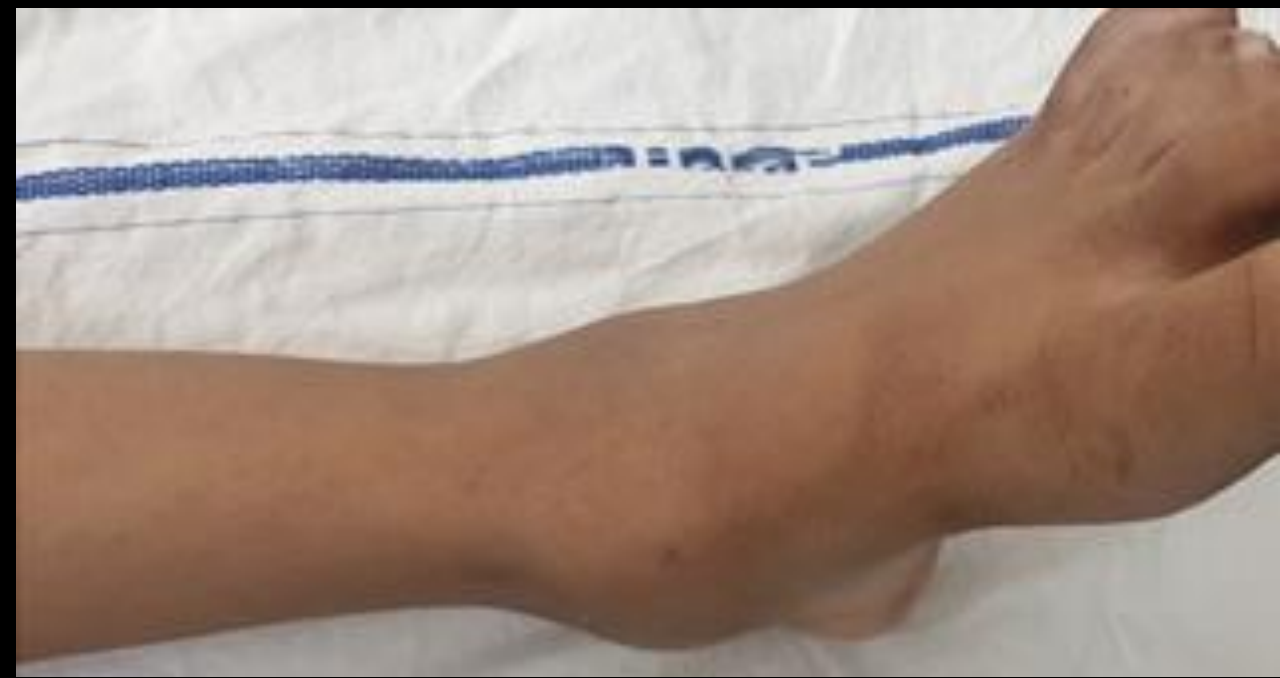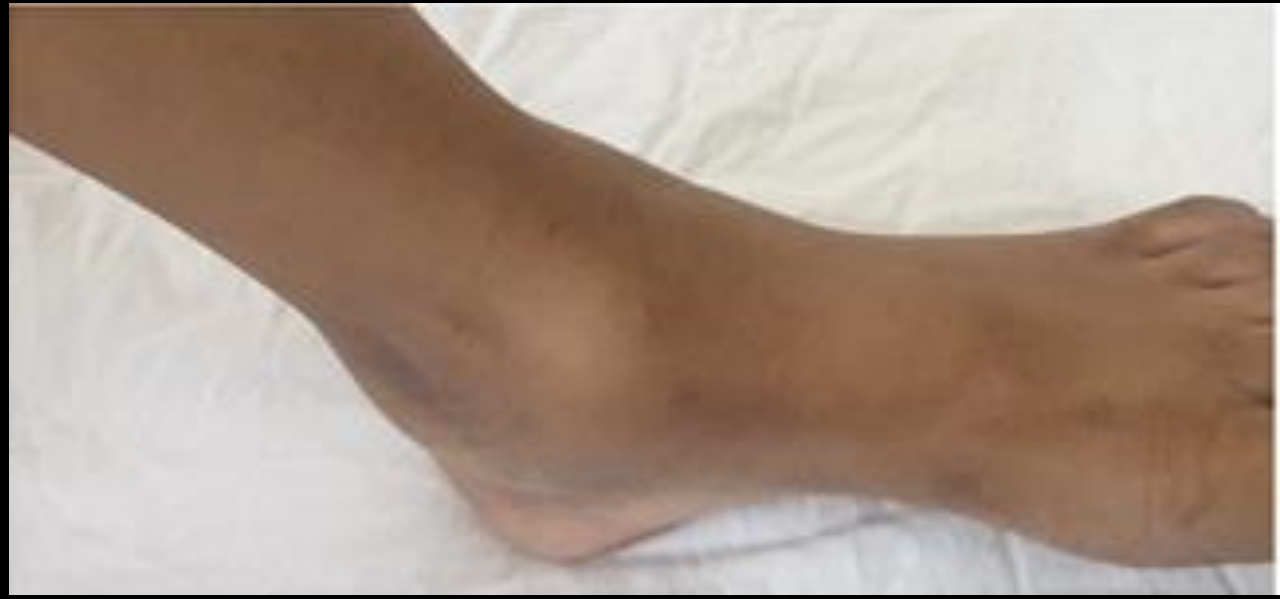MI-COD

MSS INDIA- Case Of the Day

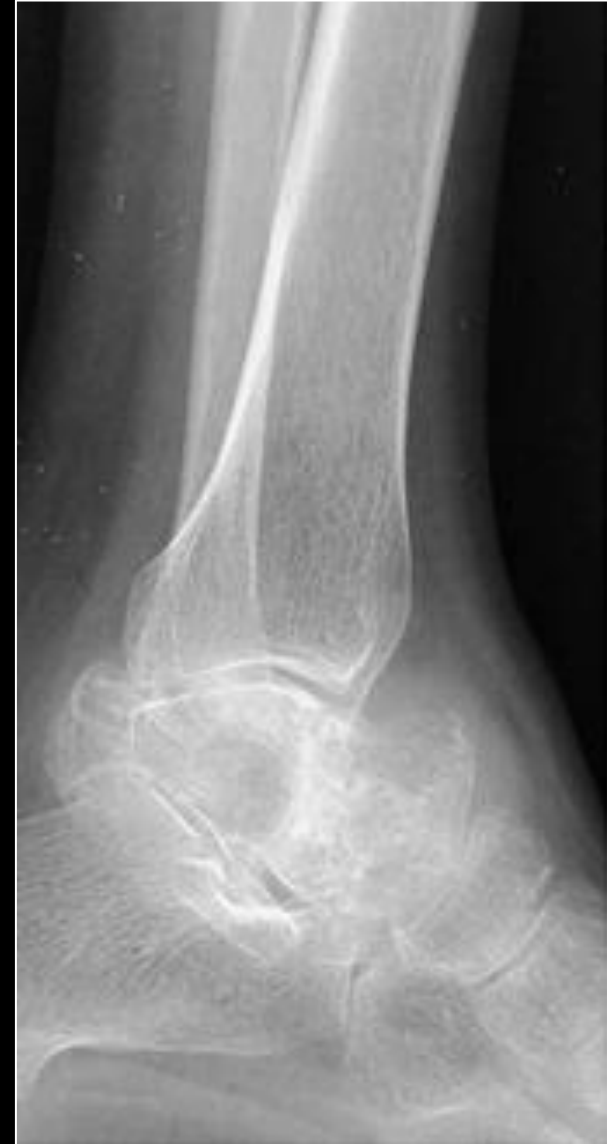
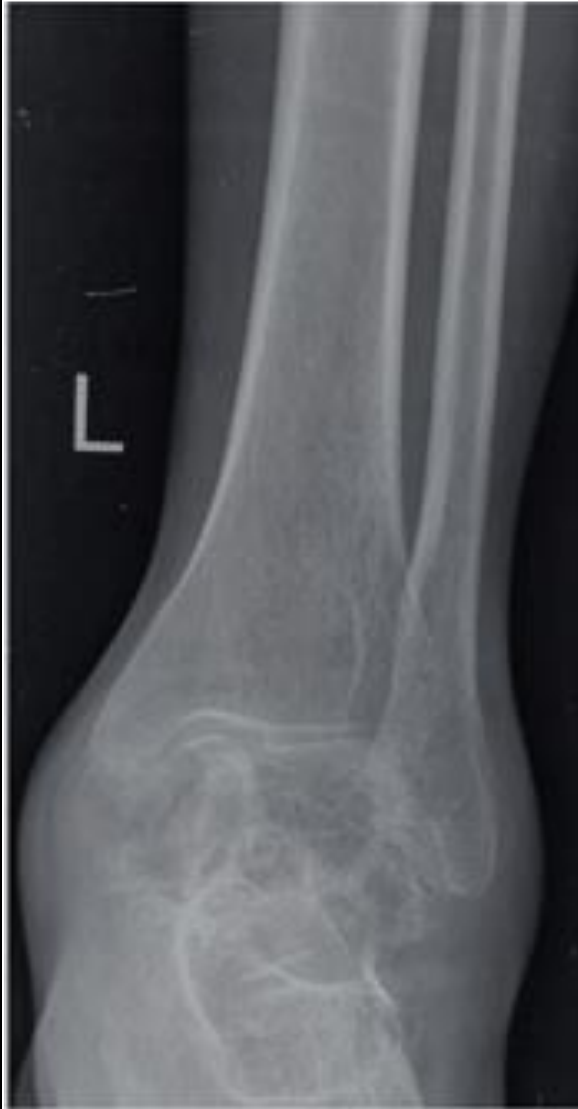
14 year young female with pain and swelling in ankle since 18 months

Clinical Photograph



Plain Radiograph



MRI

