

MICOD 15/09/2023

Contributor: Dr. Joban Babhulkar

MI-COD

MSS INDIA- Case Of the Day

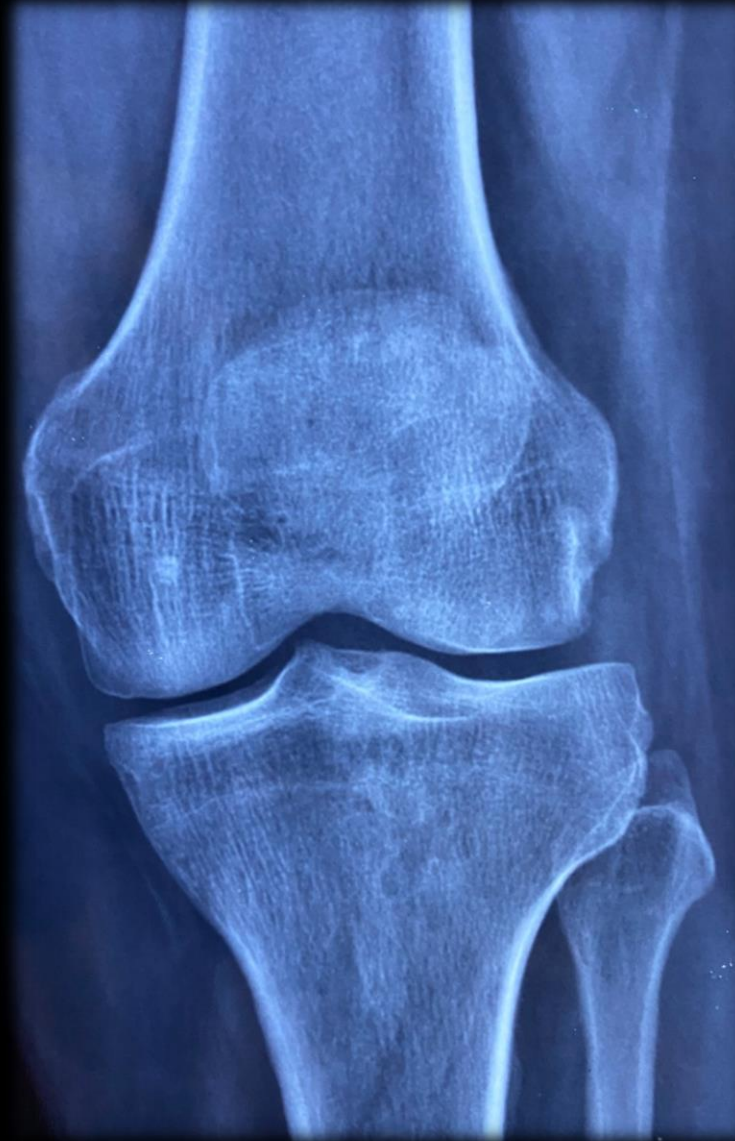
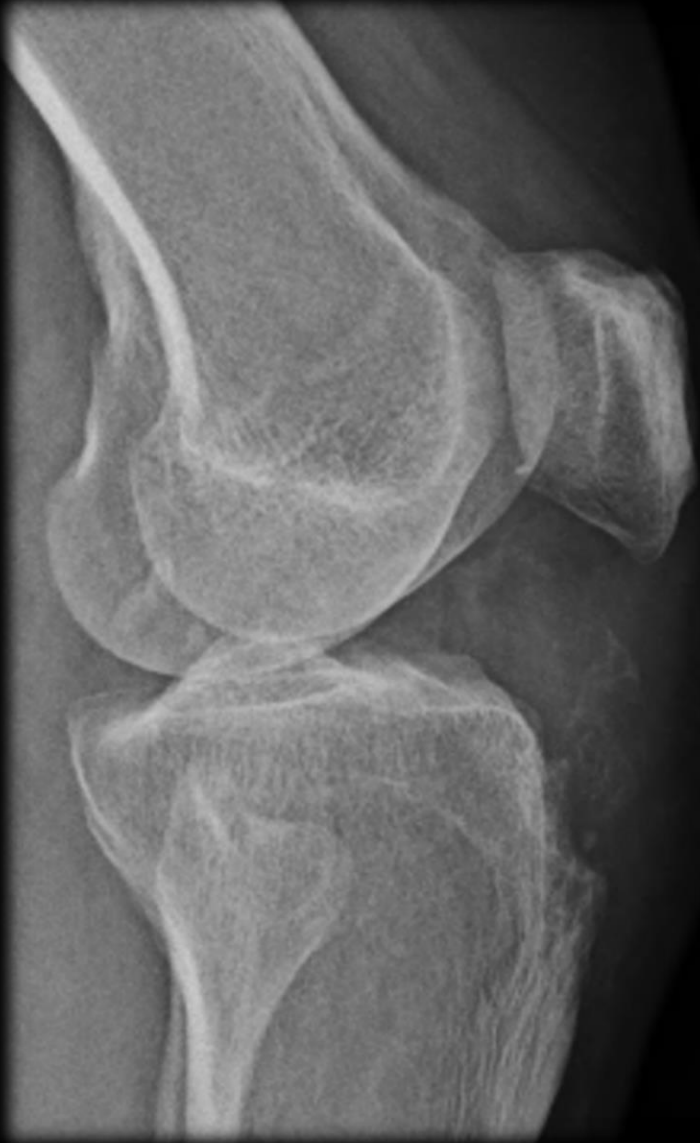
43 y/o techie came for HRUS with h/o painful swelling on anterior aspect of left knee

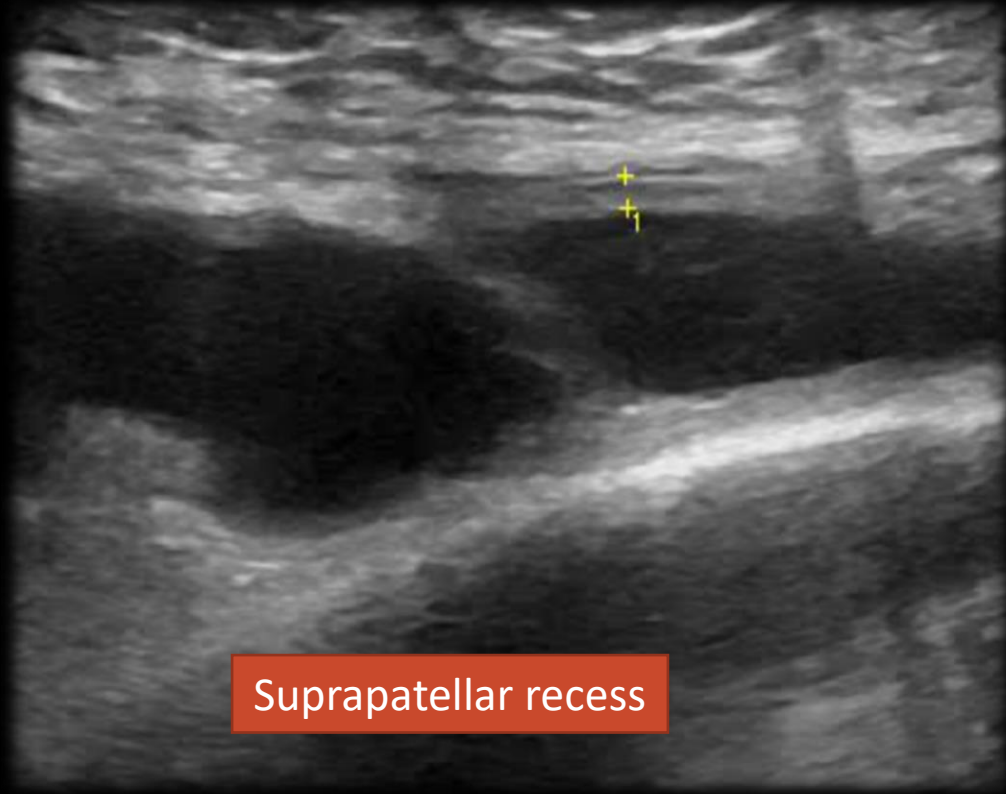
O/E : diffuse anterior knee swelling with severe tenderness.

All lab work was normal

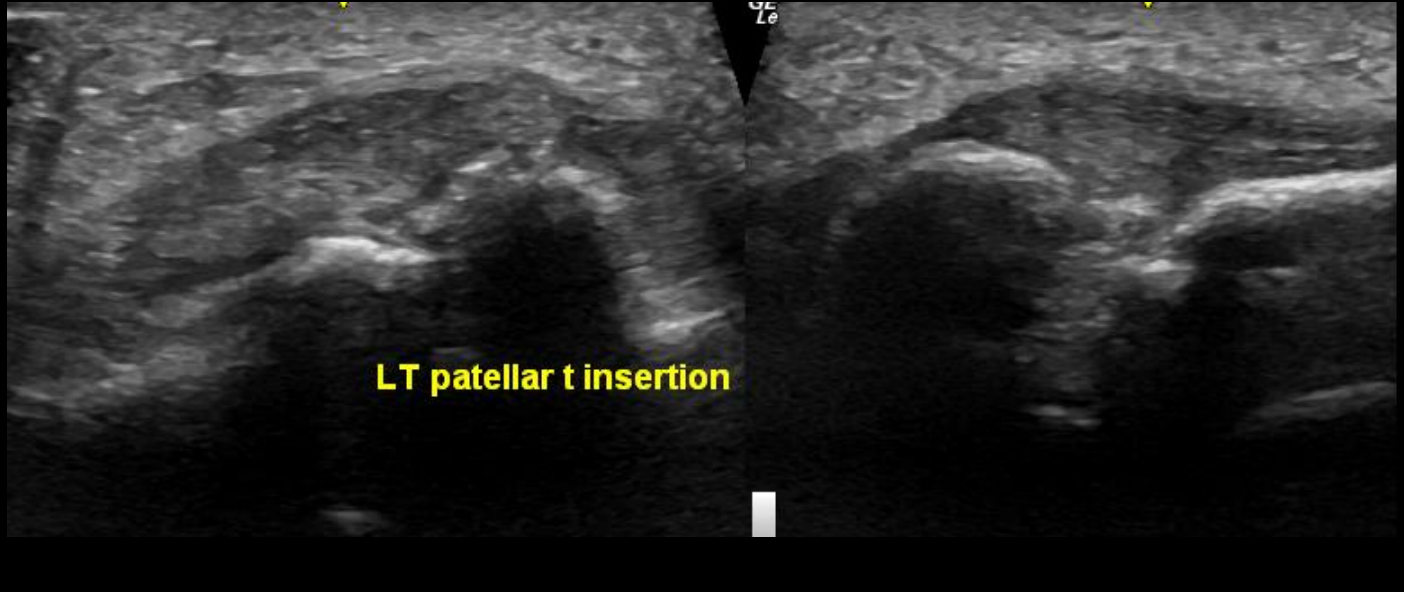
Plain radiographs



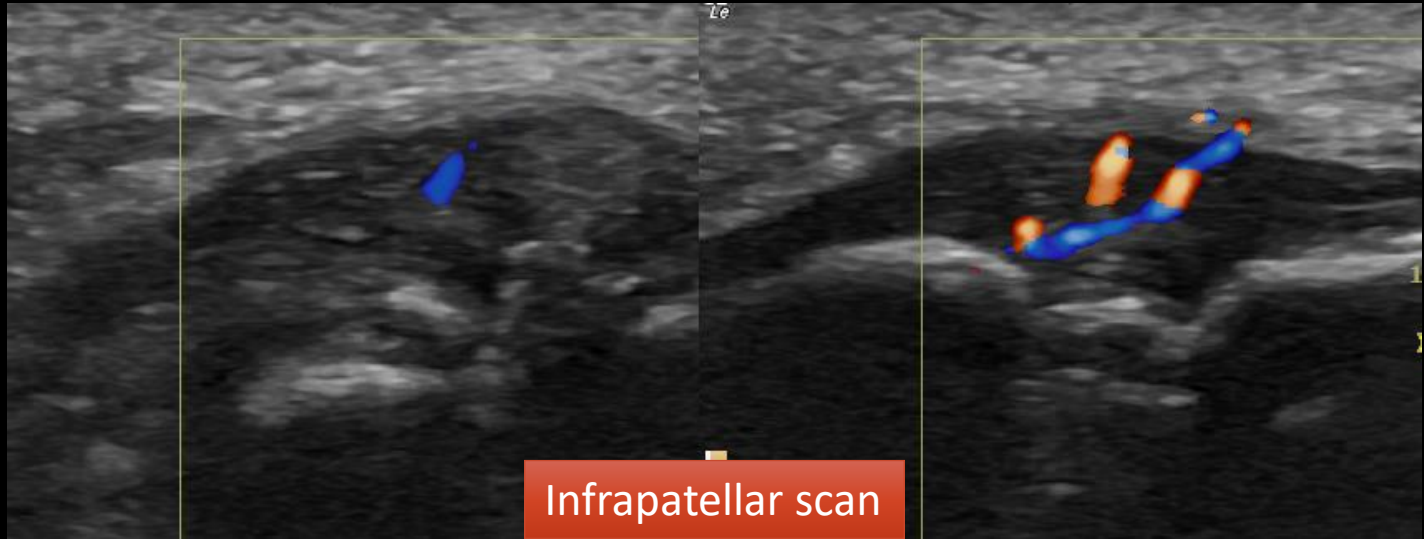
HRUS



Suprapatellar recess

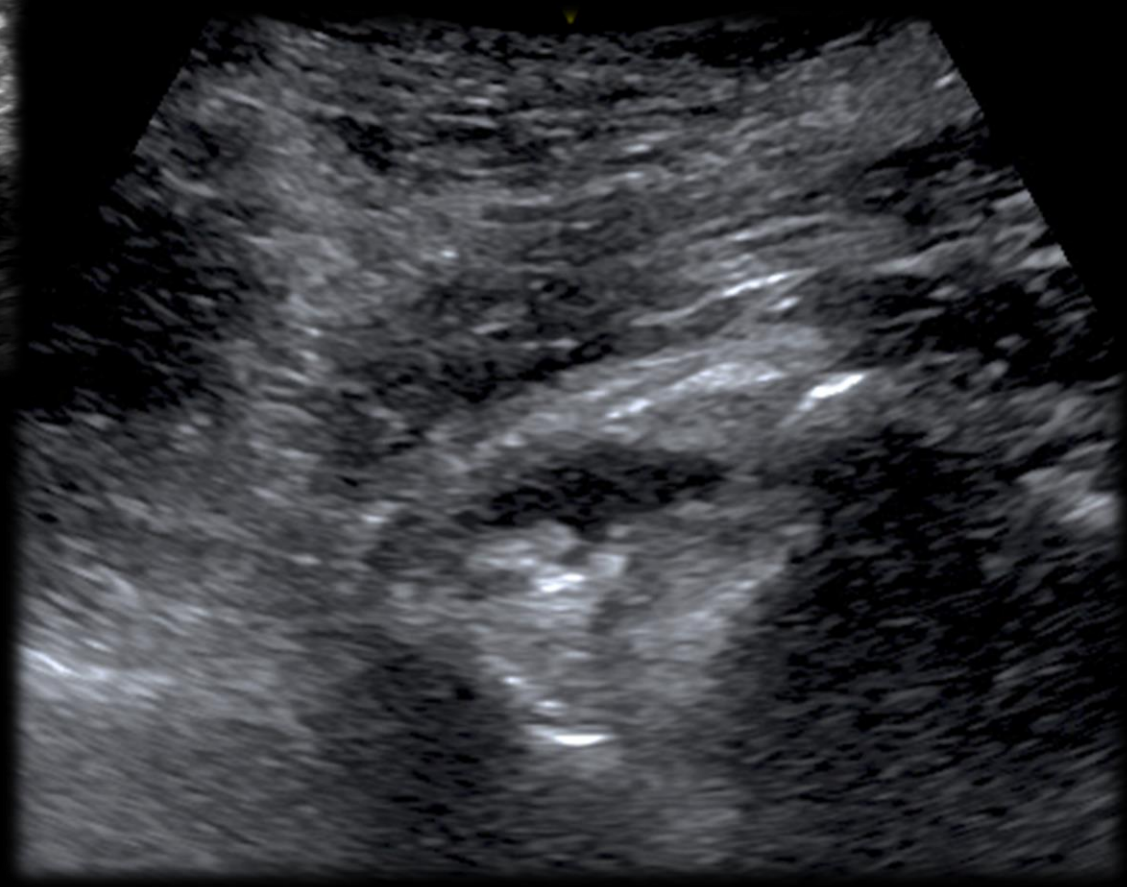
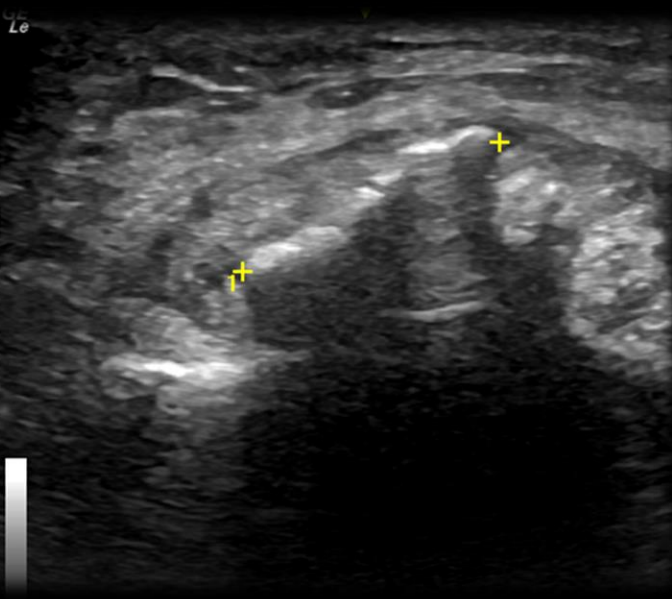
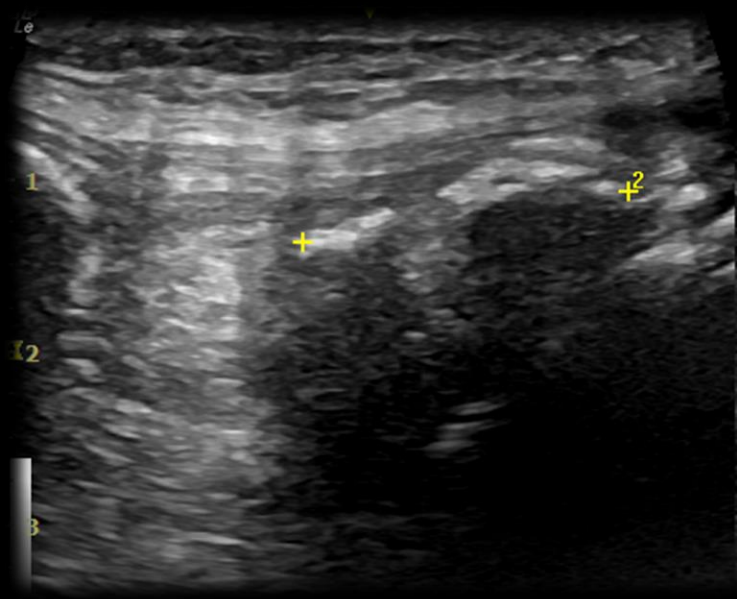


LT patellar t insertion



Infrapatellar scan

Hoffa's fat pad



What are the differentials ?
What should be done next ?

