


MICOD -12/09/2023
Case contributor –Dr. D K Singh

MI-COD

MSS INDIA- Case Of the Day



History:

- A 48 year old female presented to orthopaedic OPD with pain in right gluteal region and walking difficulty since 7 months.

- **On Clinical examination:**

Straight leg raise test: Negative ($>60^{\circ}$)

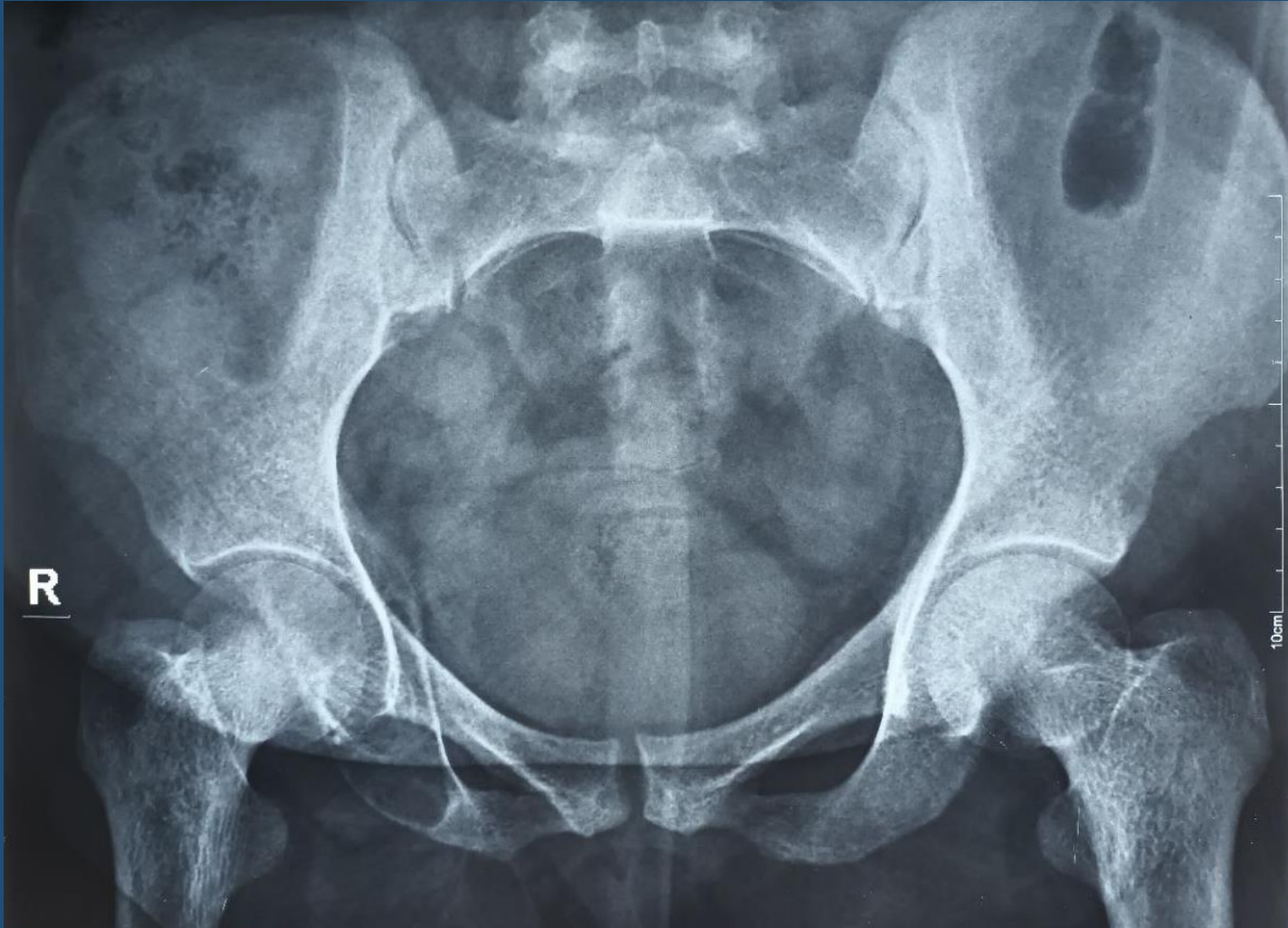Sensory (ASIA): Intact (Grade:2)

Motor (MRC): 4/5

Autonomic: No bladder/ bowel involvement

(No clinical signs of lumbar radiculopathy)

Radiograph



MRI

