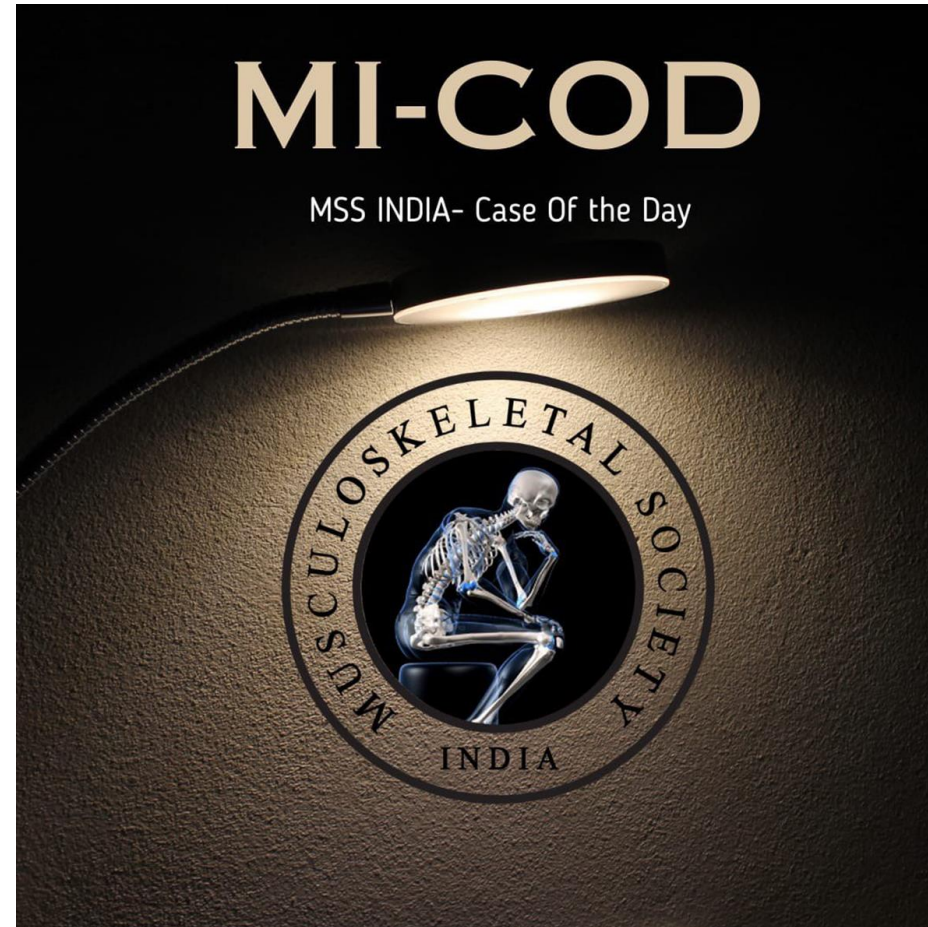


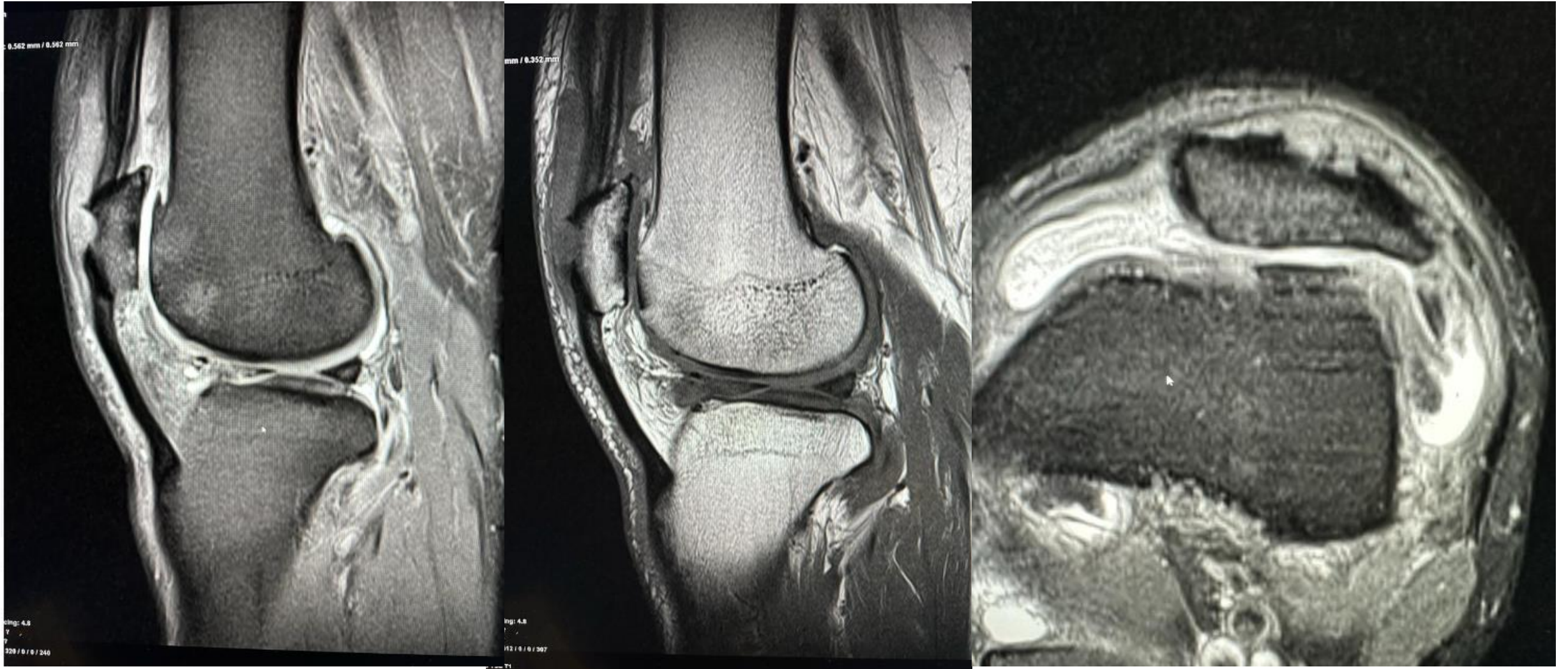MICOD -10/09/2023

Case contributor –Dr. Hema Nalini Choudur



- 60 year old male, long standing knee instability.

# Right knee MRI – done Sept 2023



Discuss diagnosis/differentials.