

Date: 20-08-2023

Case courtesy - **DR. Drushi Patel, M.D.** Consultant Radiologist,
Gujarat Imaging Centre , Samved Hospital , Ahmedabad

MI-COD

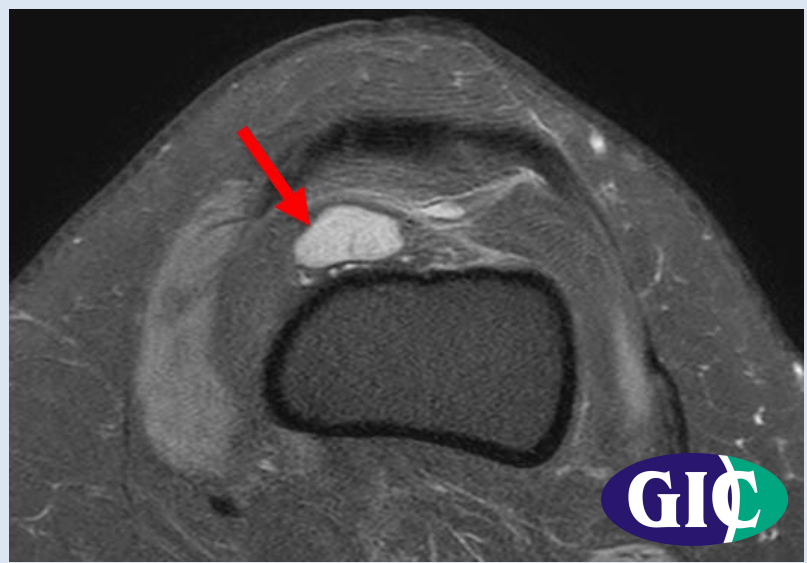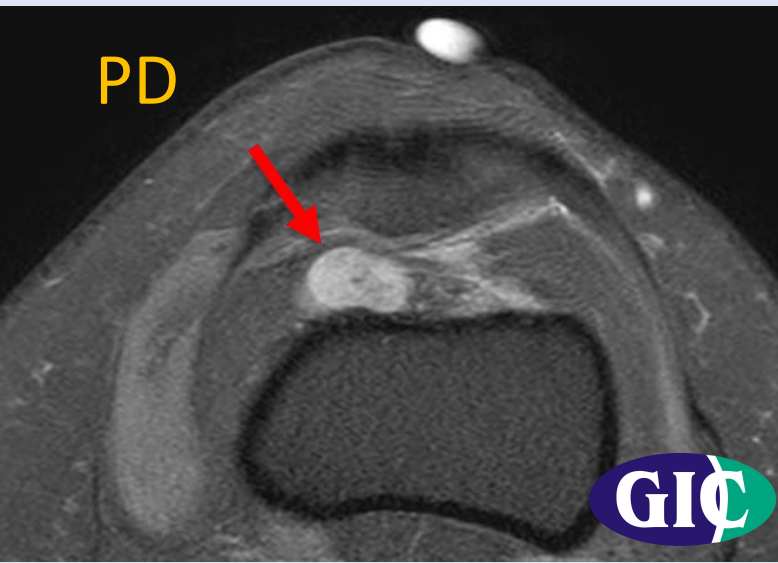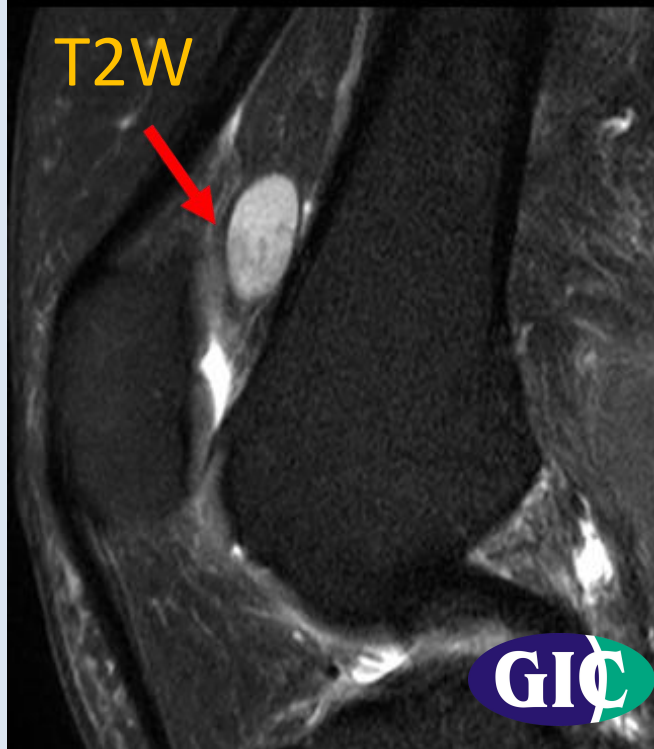
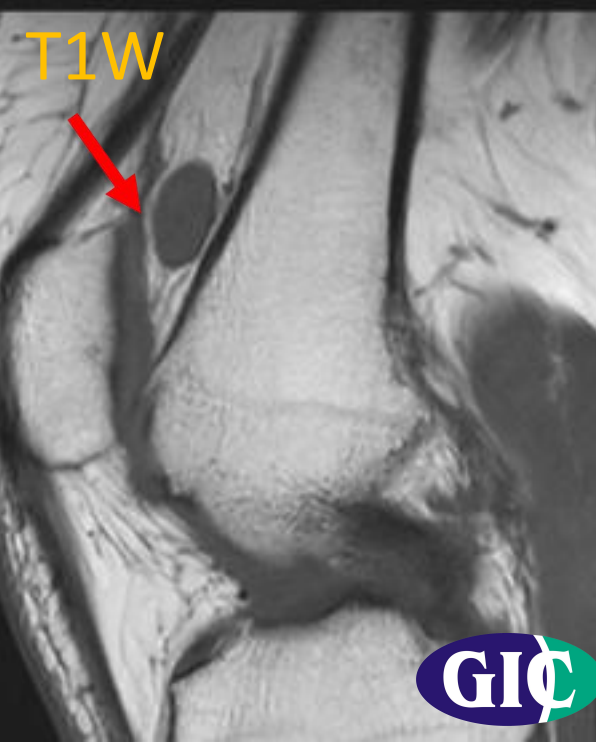
MSS INDIA- Case Of the Day



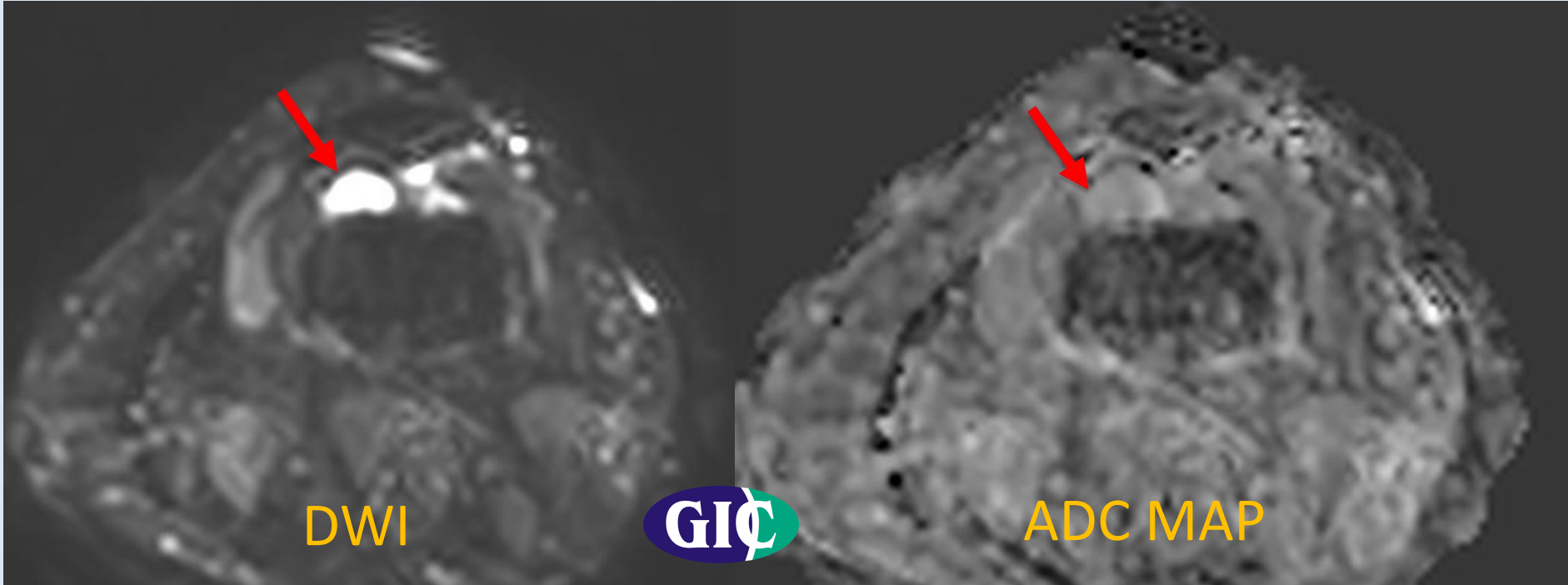
CLINICAL PRESENTATION

A 48 year old female presented with anterior knee pain since 3 months

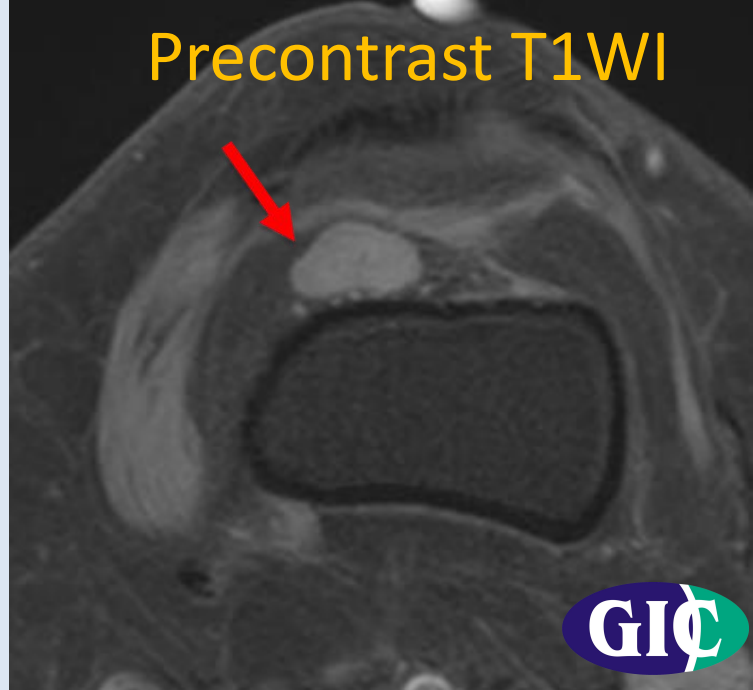
MRI



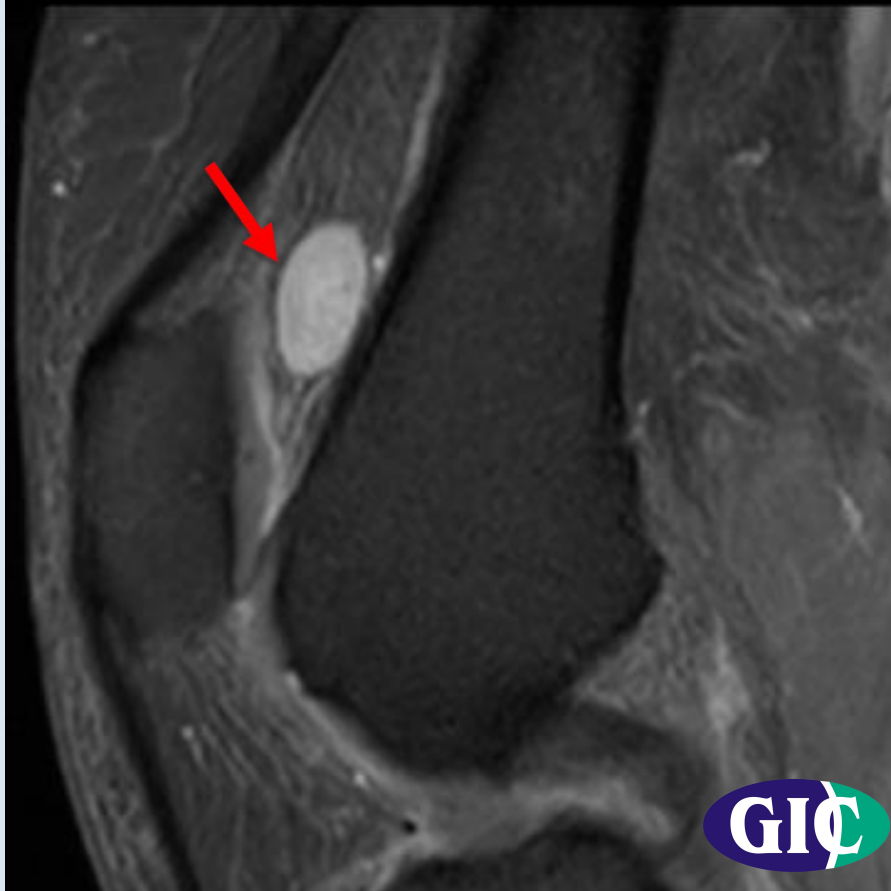MRI



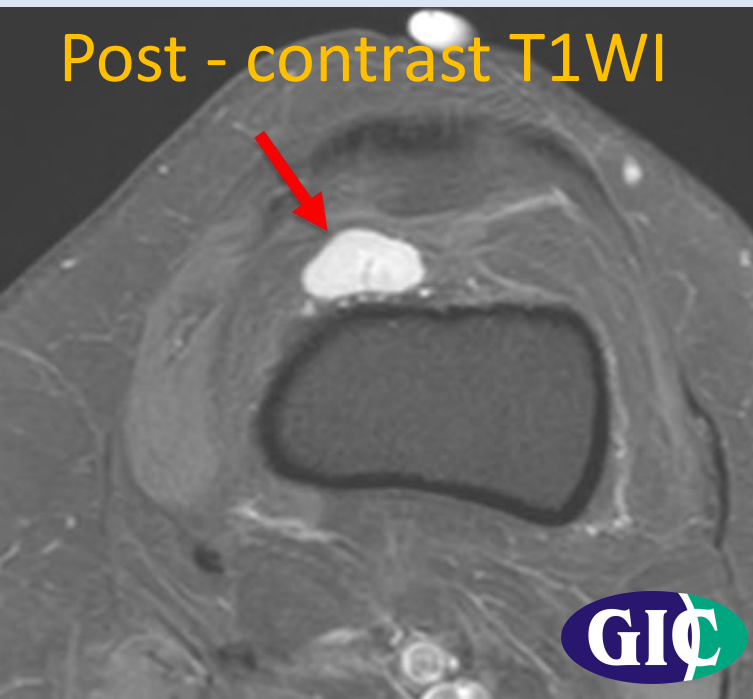Precontrast T1WI



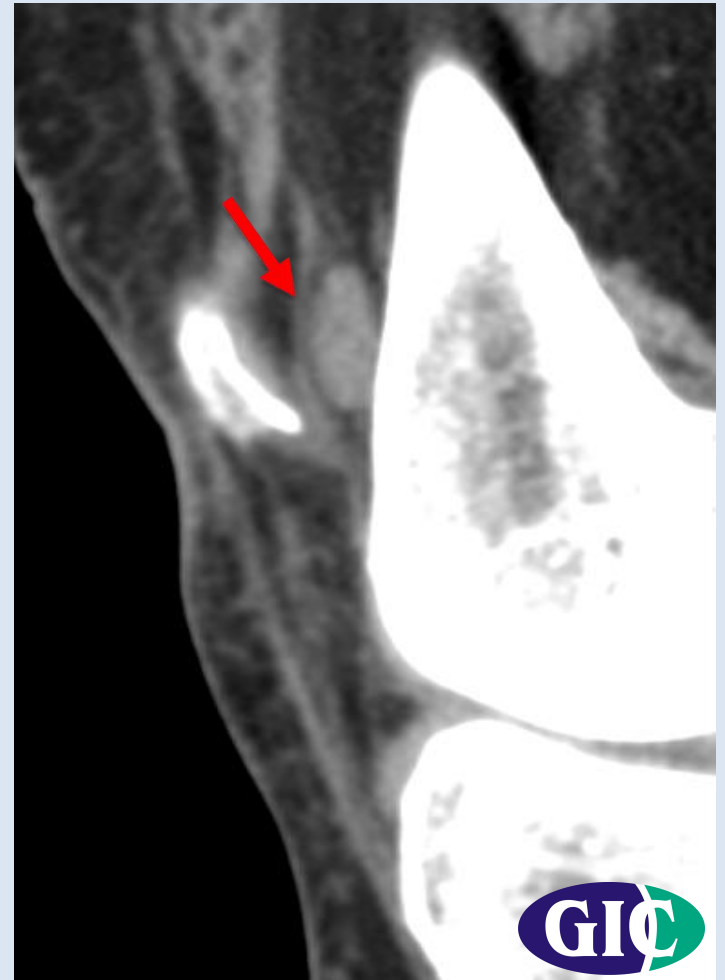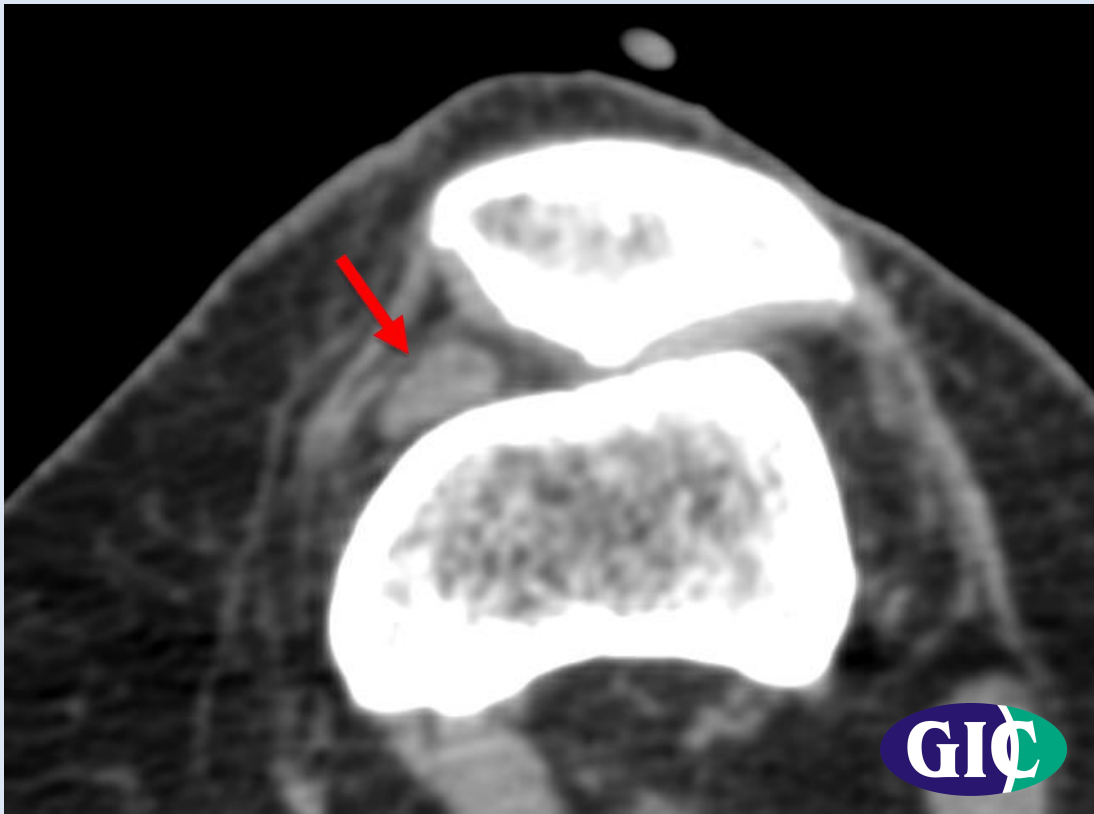
Post - contrast T1WI



Post - contrast T1WI



CT FINDINGS



HISTOPATHOLOGY

