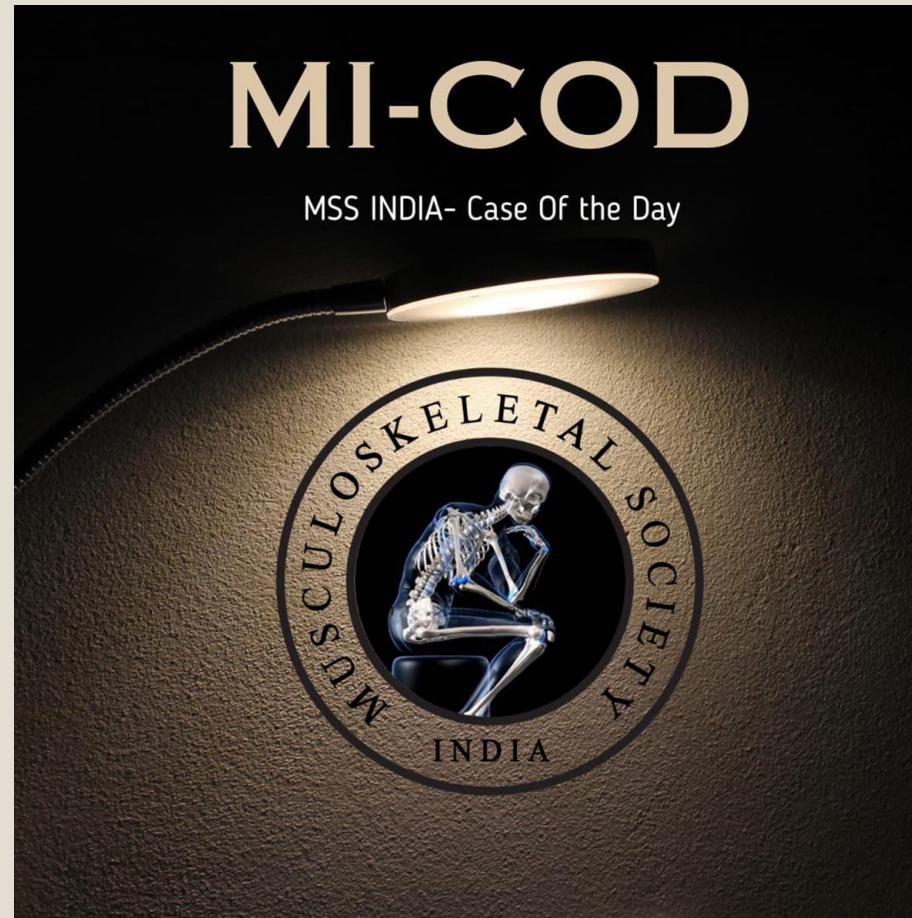


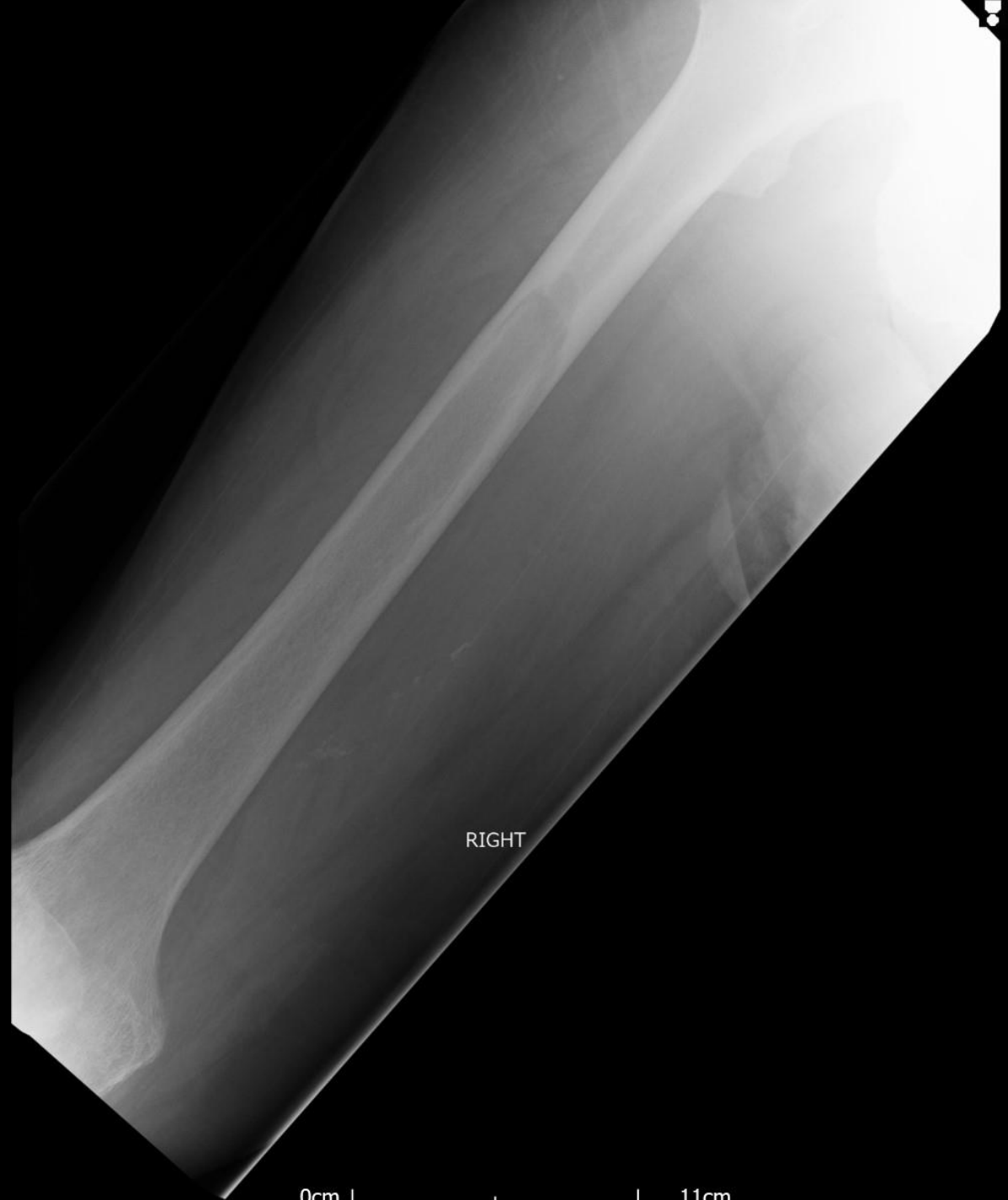MICOD -07/09/2023

Case contributor – Dr. Raj Chari



Clinical details

- 50 year old lady
- Diffuse thigh pain
- X-ray & MRI



Plain radiograph

0cm | 11cm

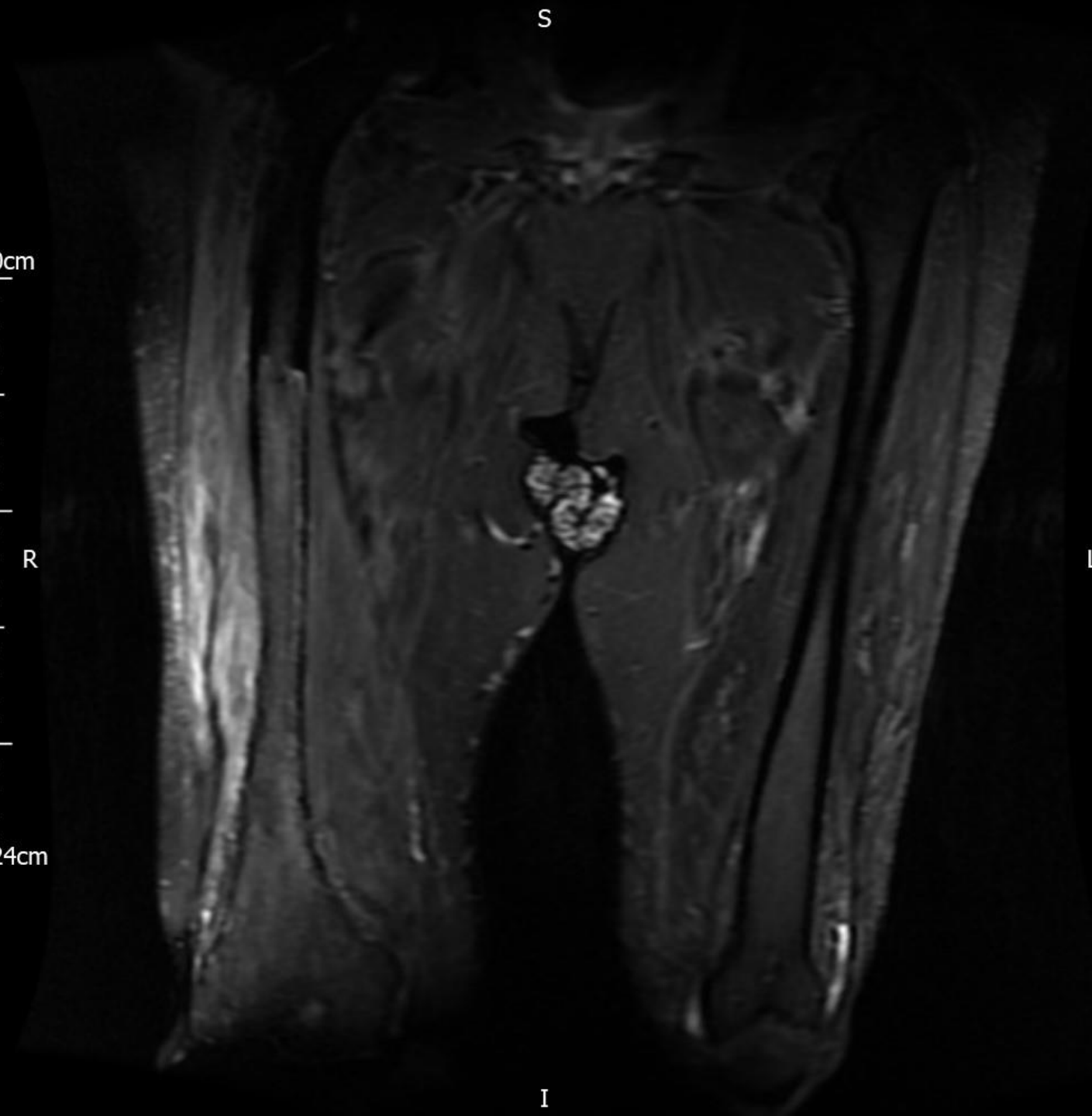
0cm
R
24cm

S

L

I

Coronal STIR



Question

What is the diagnosis?

What is the management?

PS: caution – I may set you on fire