

**Date: 19.08.2023**

**Contributor- Dr. Pushpa B T**

# MI-COD

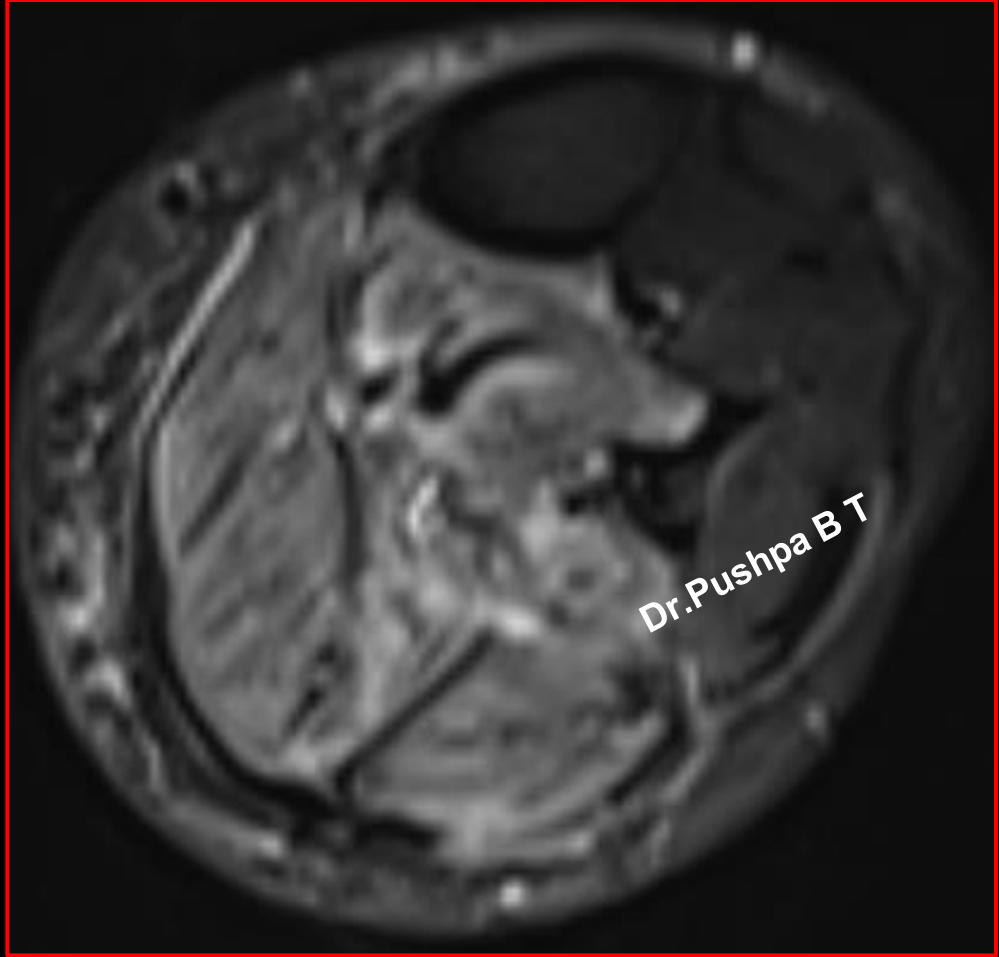
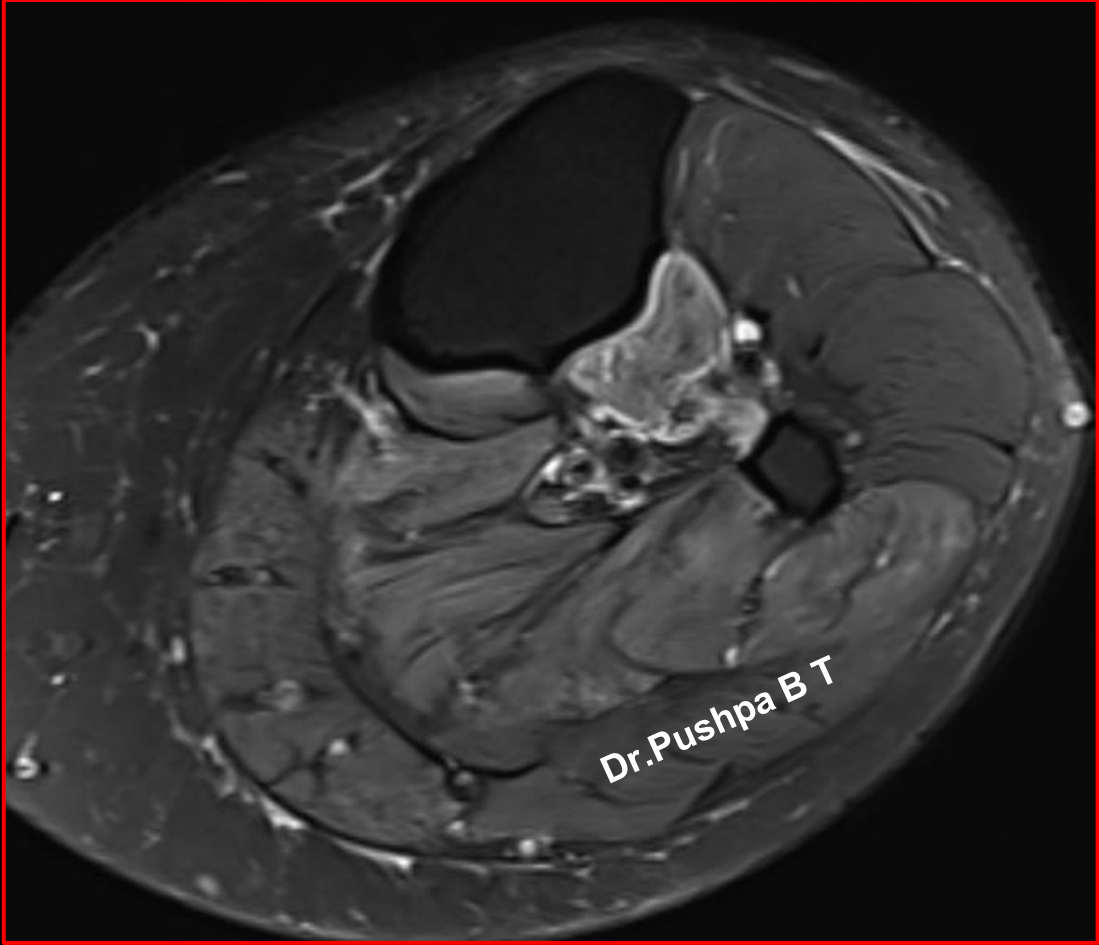
MSS INDIA- Case Of the Day

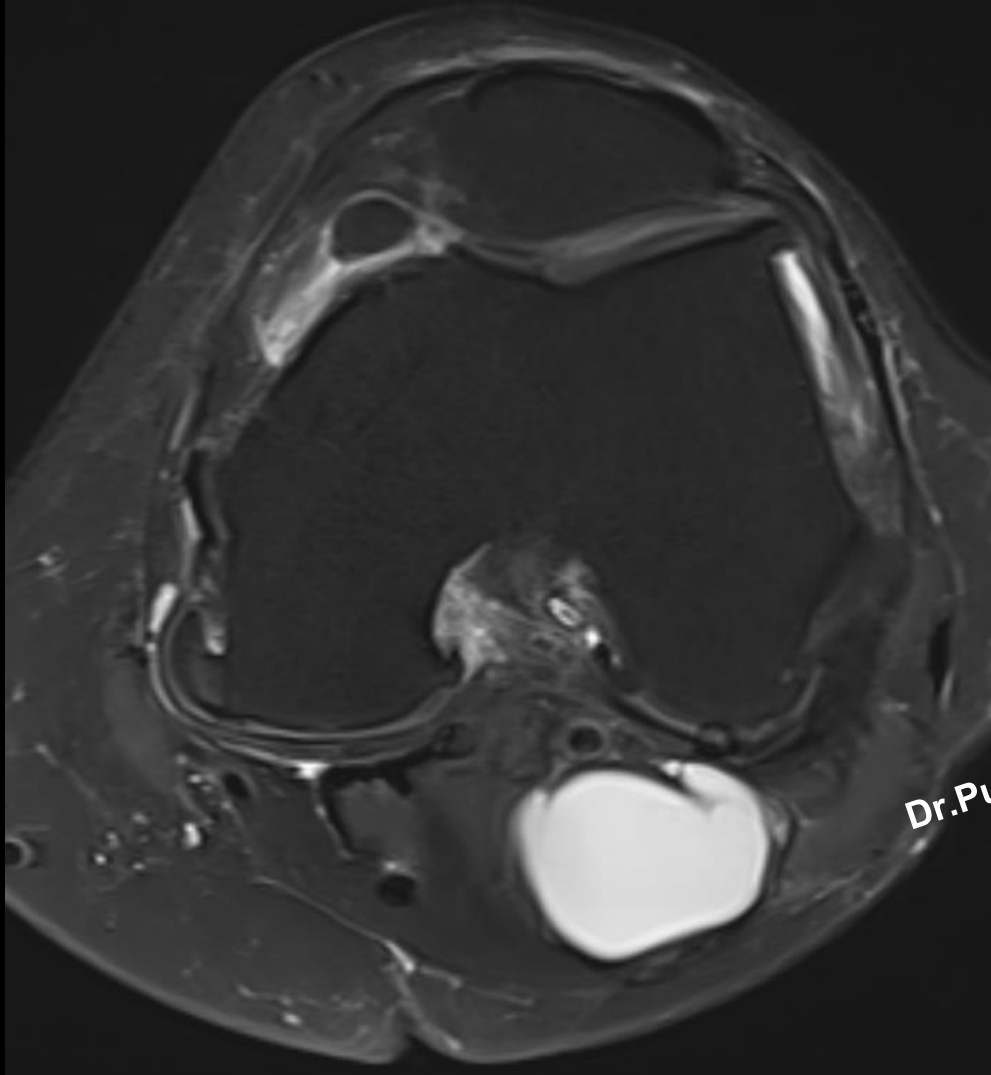


# Clinical history

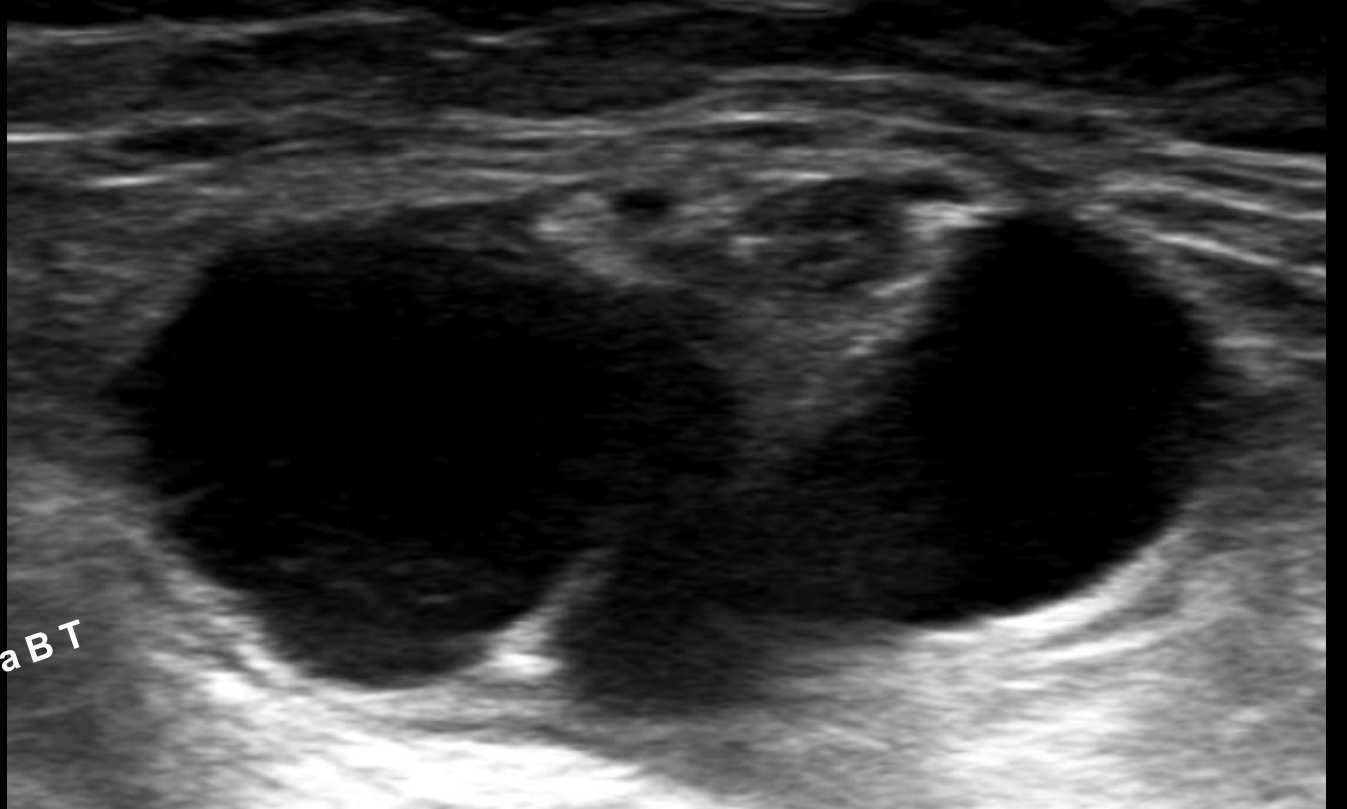
65-year-old non-diabetic non-hypertensive female patient presented with left leg pain radiating to foot for 1 week.

- History of numbness and weakness of foot.
- No fever / cough.
- No prior history of trauma, surgery or prolonged immobilization.
- Outside MRI reported as ruptured baker cyst.





Dr.Pushpa B T



Possible diagnosis?