

**Date: 18.08.2023**

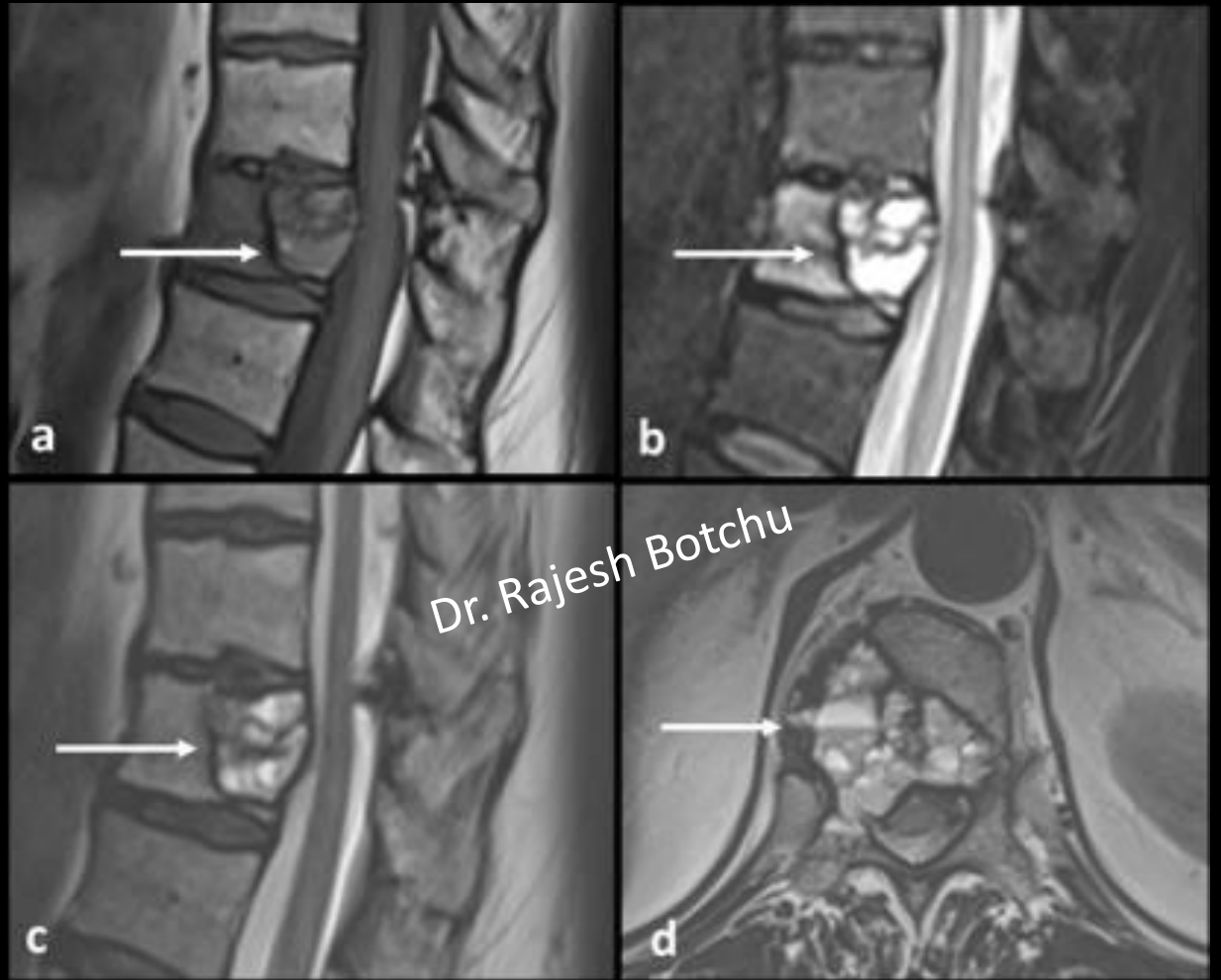
**Case courtesy – Dr. Rajesh Botchu**

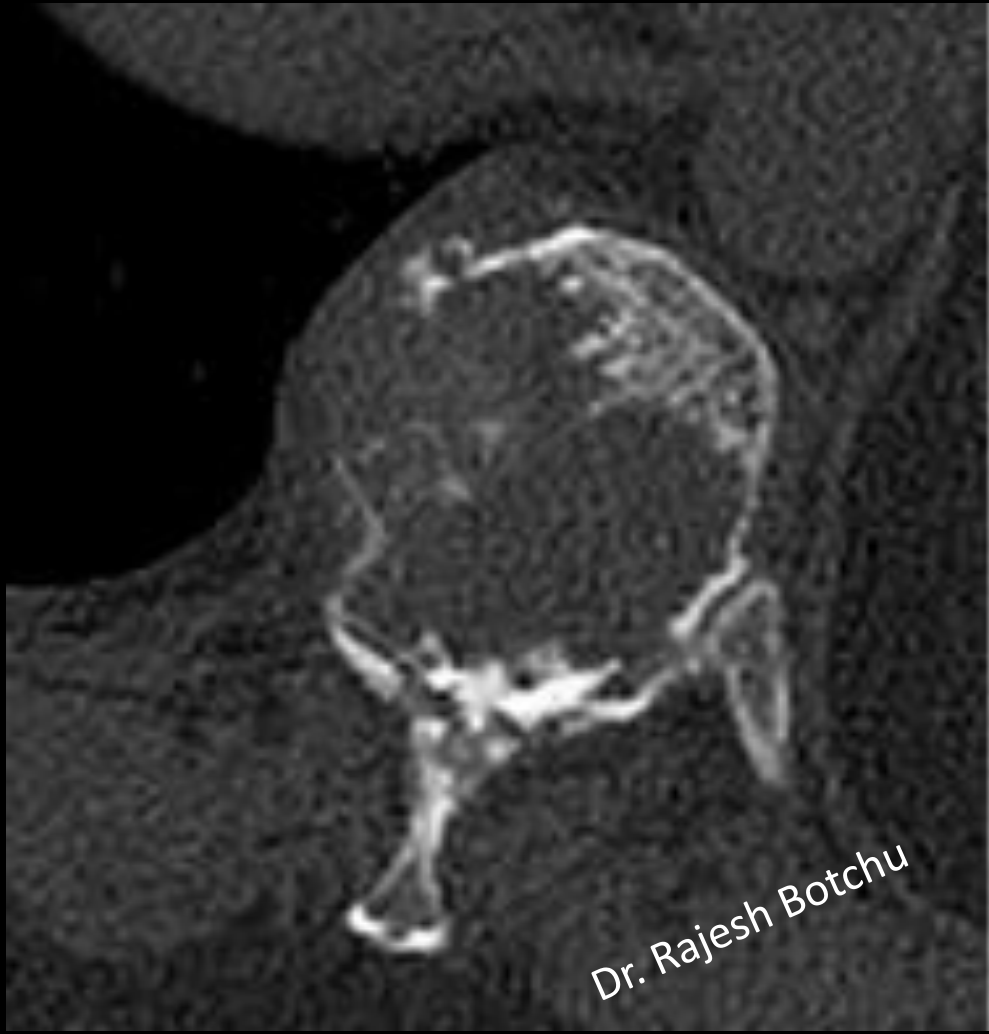# MI-COD

MSS INDIA- Case Of the Day



66 year old female with back pain





Dr. Rajesh Botchu

