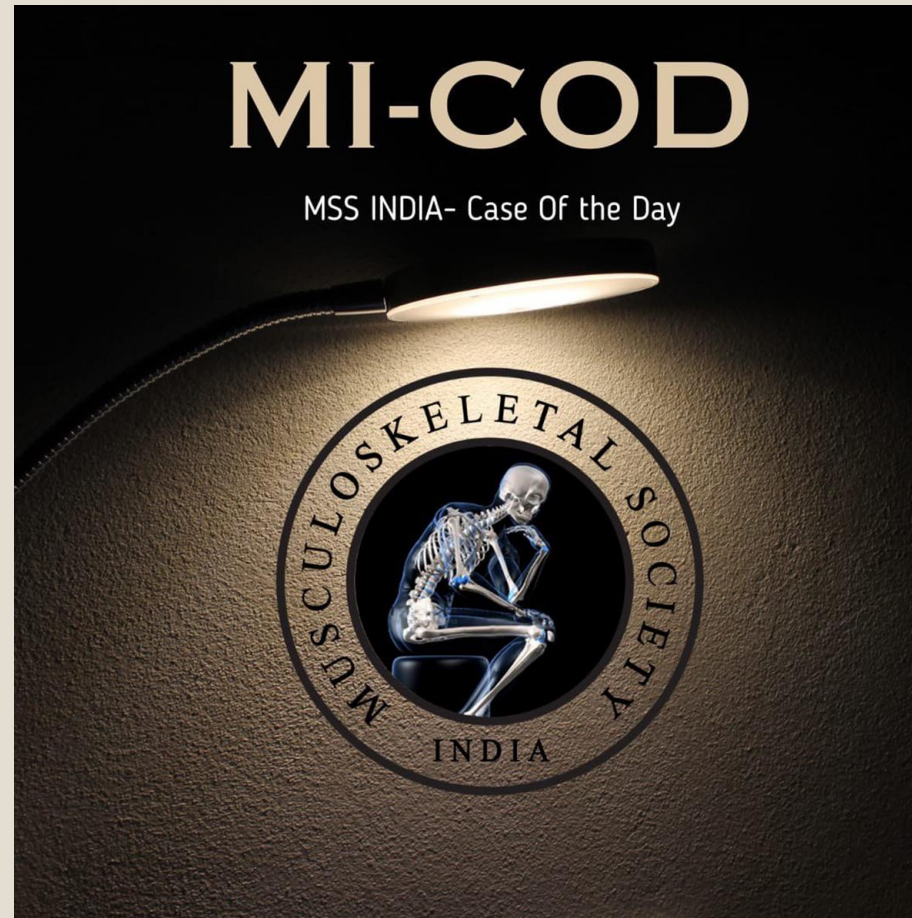


MICOD -06/09/2023

Case contributor – Dr. Darshana Sanghvi



Question: In this case of left hip DDH seen on radiograph, surgeon was unable to perform a closed reduction. What feature seen on the arthrogram might have hindered reduction?

