


MICOD- 05/09/2023

Contributor- Dr. Harun Gupta

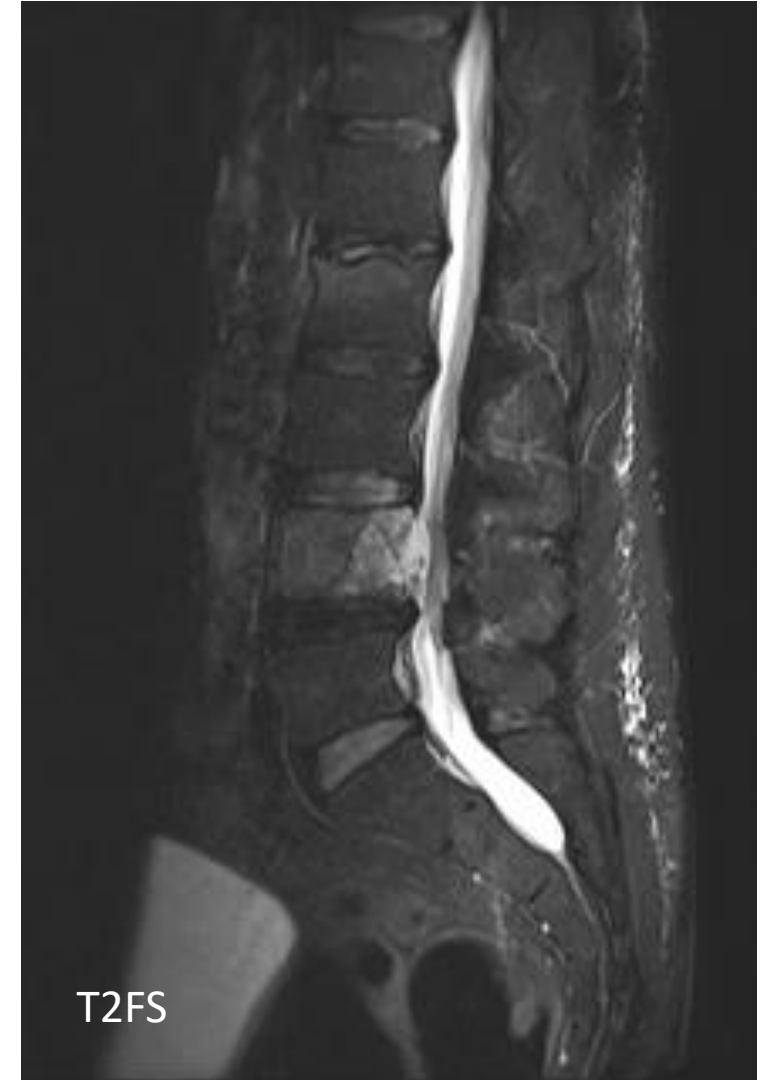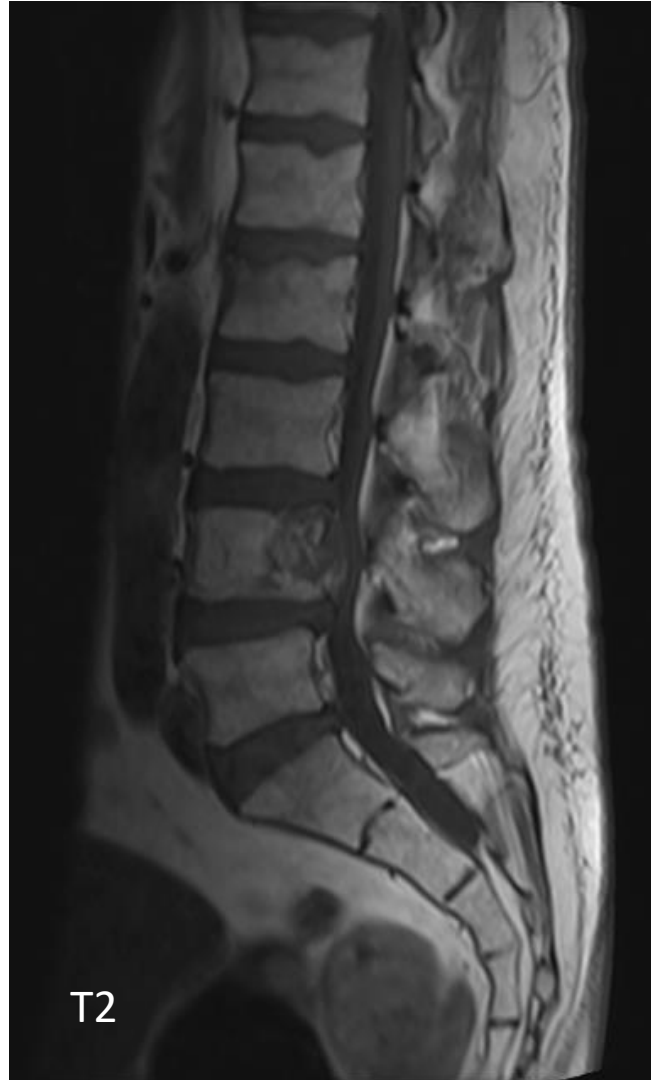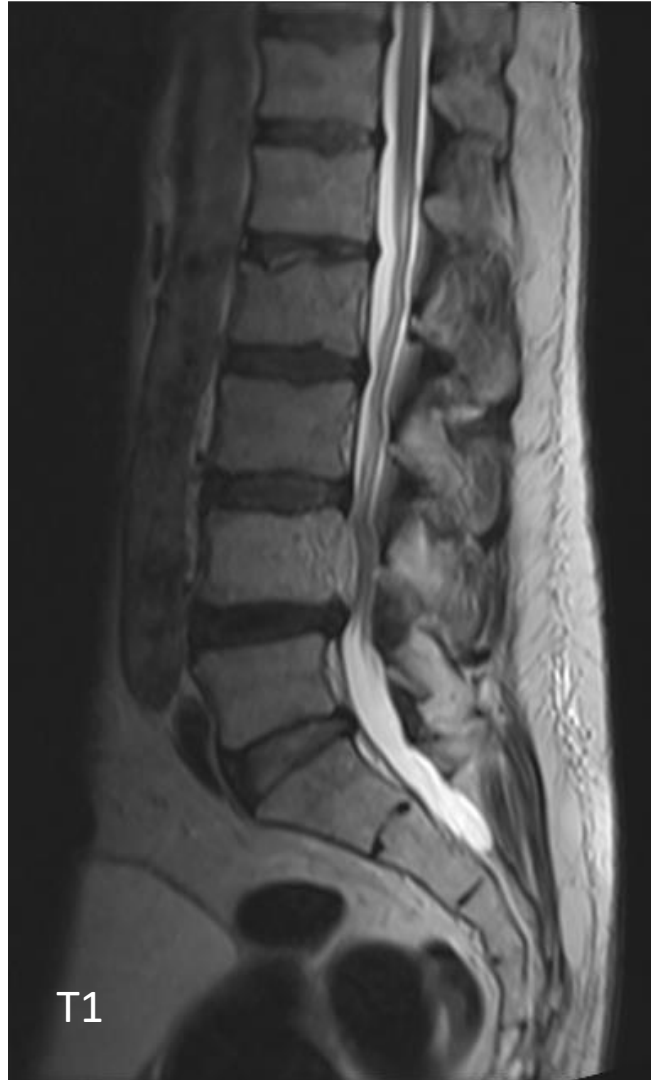@mskteachingroom



- Link for Full Case DICOM case

<https://www.cmrاد.com/cases/1987048275>

58-year-old gentleman, past elevated PSA, presenting with cauda equina symptoms



T2

