

MICOD- 04/09/2023

Contributor- Dr. Raj Chari

MI-COD

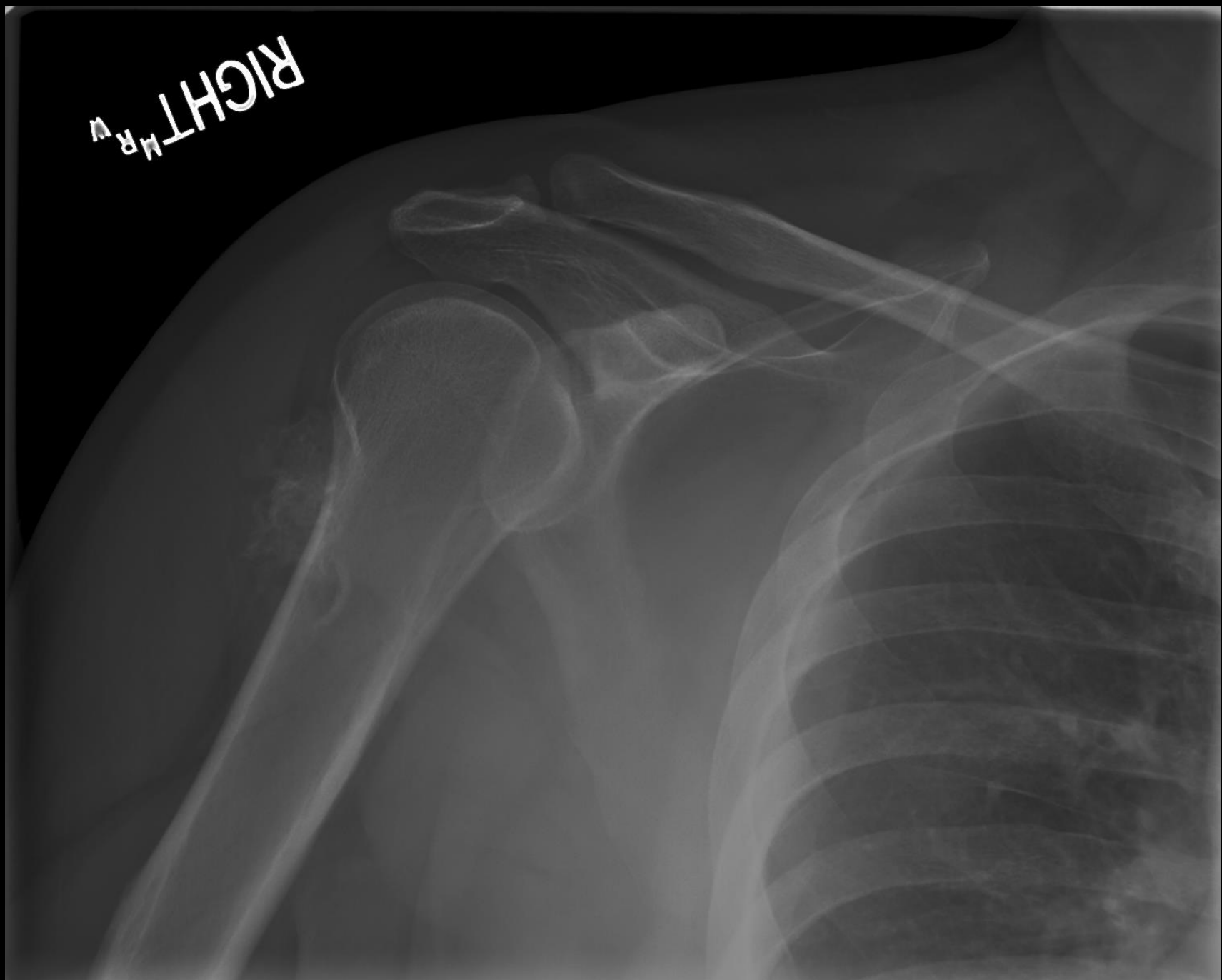
MSS INDIA- Case Of the Day



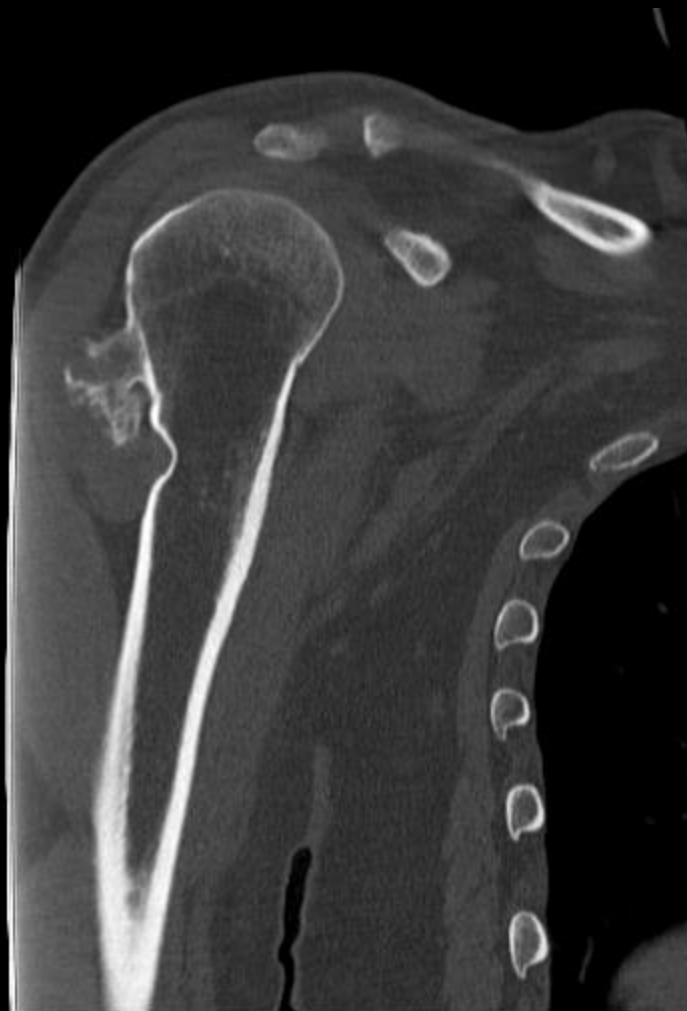Clinical details

- 30 year old lady
- Firm painless mass
- Underwent appropriate investigations

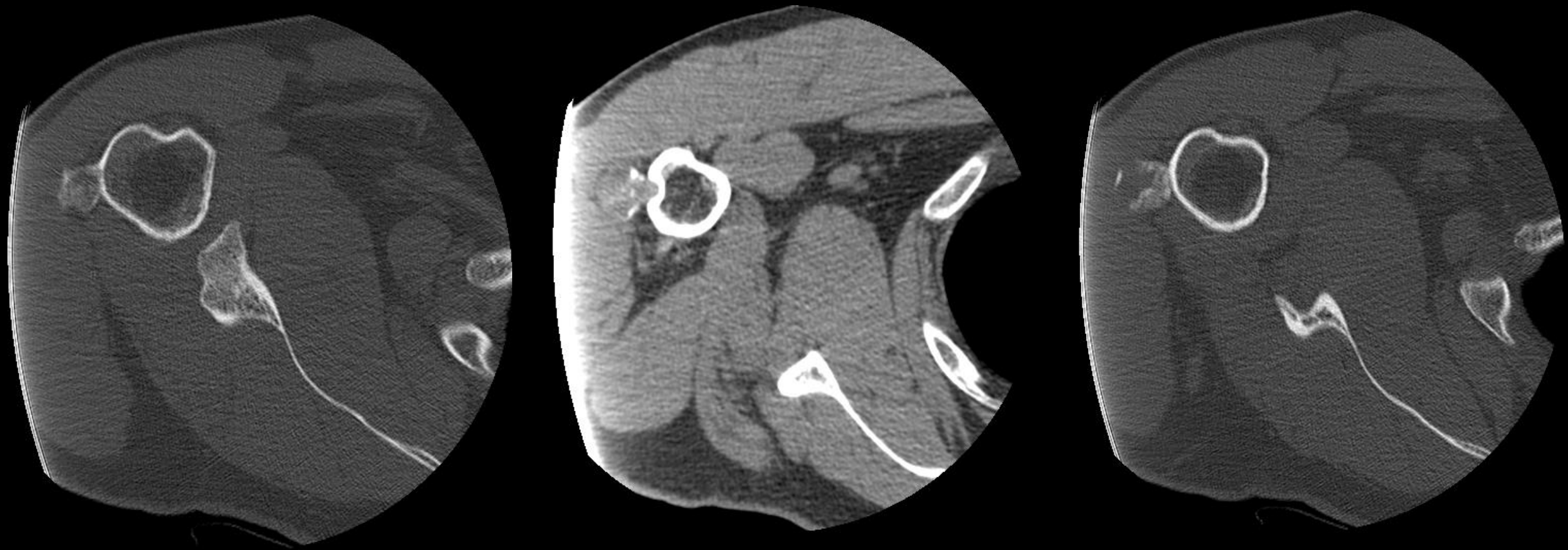
RIGHT
MR
V



AP Radiograph



Coronal unenhanced CT



Axial unenhanced CT

Question

What is the diagnosis?

PS: I am just a cortical lesion!