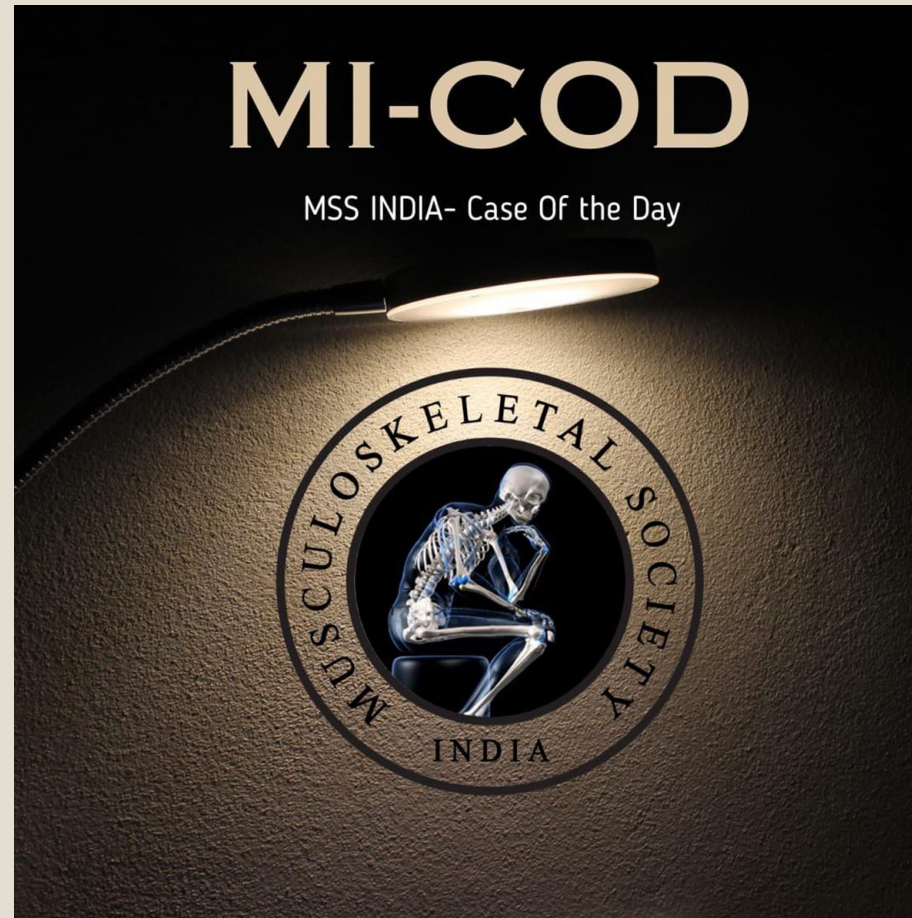


MICOD -02/09/2023

Case contributor – **Dr. Stanzin Spalkit**

, AIIMS New Delhi





**22 year old male, trauma to the wrist 3 days back, c/o dull aching pain in wrist**

